

# Tendon Expansion with Fascia Lata in Treatment of A-Pattern Strabismus due to Superior Oblique Overaction

M.R. Talebnejad, M.H. Nowroozzadeh,  
M. Sharifi

## Abstract

**Background:** In 1991, Wright described a superior oblique expander procedure for browns syndrome and superior overaction with good results. Originally, this procedure has been performed with silicone band expander. The aim of this study was to report the results of treatment of a series of patients with A-pattern strabismus associated with overacting superior oblique muscle using the fascia lata tendon expander technique.

**Methods:** A total of 12 patients with bilateral overaction of the superior oblique muscle and A-pattern strabismus were treated with bilateral superior oblique lengthening with fascia lata according to the values recommended by Wright. Fascia lata was harvested through a lineal incision on the lateral aspect of the patients' thigh.

**Results:** The follow-up was 4 to 51 months (mean,  $28.8 \pm 20.7$  months). Mean superior oblique overaction improved from  $3.5 \pm 0.8$  before surgery to  $0.8 \pm 0.9$  after surgery ( $P < 0.001$ ). Mean A-pattern improved from  $26.4 \pm 8.5$  PD to  $1.7 \pm 7$  PD ( $P < 0.001$ ), and subjective intorsion improved from  $6 \pm 0.7$  degree to  $0.3 \pm 1.1$  degree ( $P < 0.001$ ). One patient developed overcorrection. None of the patients developed recurrence.

**Conclusion:** The fascia lata tendon spacer is a useful procedure in the treatment of A-pattern strabismus due to superior oblique overaction. This technique may be superior to posterior tenectomy because of less incidence of superior oblique overaction recurrence; however, the operation time is longer.

**Iran J Med Sci 2008; 33(3): 150-154.**

**Keywords** • Elongation • fascia lata • A-pattern

Department of Ophthalmology,  
Poostchi Ophthalmology Research Center,  
Shiraz University of Medical Sciences,  
Shiraz, Iran.

## Correspondence:

Mohammad Reza Talebnejad MD,  
Department of Ophthalmology,  
Poostchi Ophthalmology Research Center,  
Shiraz University of Medical Sciences,  
Shiraz, Iran.

**Tel/Fax:** +98 711 2302830

**Email:** [talebnejadmr@yahoo.com](mailto:talebnejadmr@yahoo.com)

Submitted: 2 March 2008

Revised: 3 July 2008

Accepted: 1 July 2008

## Introduction

**T**he hazards of surgical procedures on superior oblique muscle are less predictable. Therefore the procedures should be undertaken cautiously. The weakening procedures of the superior oblique are used for conditions such as A-pattern strabismus, Brown's syndrome, torsional torticollis, and rarely, in homo lateral inferior oblique or contralateral inferior rectus paresis. The standard procedures of superior oblique weakening have been tenotomy, tenectomy, recession, split lengthening, and z-tenotomy. All these procedures cause slackening of the superior oblique muscle tendon complex, which is accompanied by inconsistent results.<sup>1,2</sup>

Wright et al described a superior oblique expander procedure for Brown's syndrome and superior oblique overaction (SOOA) with good results because the insertion of ligament is not disturbed.<sup>3,4</sup> In the superior oblique silicone expander procedure, the cut ends of the superior oblique tendon are separated by a silicone band. This approach slackens the superior oblique tendon in a graded and reversible manner without altering the superior oblique insertion.<sup>3,4</sup> In spite of its advantages, introducing a foreign body may add the potential risks of orbital cellulites,<sup>1</sup> or implant extrusion.<sup>2</sup> In this study, we used autogenous fascia lata as a substitute for silicone band to reduce the complications associated with this technique while preserving its advantages.

The purpose of this study was to present the results of bilateral superior oblique lengthening with fascia lata in 12 consecutive patients with A-pattern strabismus because of SOOA.

### Patients and Methods

In a prospective study, 24 eyes of 12 consecutive patients with bilateral SOOA and A-pattern exotropia were enrolled. Written informed consent was obtained from all the patients before surgery in accordance with Declaration of Helsinki. The study protocol was approved by the Ethics Committee of Shiraz University of Medical Sciences.

Excluded patients were those with follow-up of less than 2 months, pseudo SOOA, stereopsis less than 800 seconds of arc as measured by Titmus stereo testing (Stereo Optical Inc, Chicago, IL, USA), and any previous surgical procedure on the superior oblique muscles. All the patients were healthy and none had a history of head trauma or neurologic abnormality. Preoperative evaluations included visual acuity, ductions, versions, and measurements of the deviation in nine diagnostic positions of gaze with alternate prism-cover test. The degree of A-pattern was noted. A significant A-pattern was defined as a divergence of at least 10 prism diopter (PD) between 25° up gaze and down gaze from primary position. Oblique muscle dysfunctions were measured according to the bellow scale of overaction and with the aid of figure comparison.<sup>5,6</sup> Normal (0), hypotropia of adducted eye up to 10 PD (+1), hypotropia of adducted eye between 11 and 20 PD (+2), hypotropia of adducted eye between 21 and 30 PD (+3), and hypotropia of adducted eye more than 30 PD (+4). Subjective torsion (degree) was assessed by using the double Maddox rod test in cooperative patients.

Postoperatively, we examined the patients on days 1, 7, and 30 and then with 2 months intervals until 6 months and then every 6 months.

### Operative procedure

Under general anesthesia, a 2-cm linear skin incision was made in the lateral aspect of the thigh, roughly 5 cm superior to the knee joint over the ileo-tibial tract. Then a strip of fascia lata (1 cm in width and 1.5 cm in length) was harvested. Donor site was sutured with interrupted 5-0 nylon sutures. The operation on each eye was done through an incision made on supra temporal conjunctival fornix identical to what was described by Wright.<sup>3</sup> Superior oblique tendon was exposed and cut, and then the strip of fascia lata with a width between 2 and 3 mm was sutured by double-armed 6-0 Mersilene (Ethicon, Inc, NJ, USA) sutures to the severed ends. In the first four operations, the useful length of strip was 5, 6, and 7 mms for +2, +3 and +4 superior oblique overaction, respectively. But undercorrection was observed post operatively in 3 patients with +4 SOOA, so 9 mm strips were used for the other patients with +4 SOOA. No other simultaneous strabismus surgery was performed. The necessary surgery on rectus muscles was performed on all of the patients at least 2 months after elongation to correct any remaining horizontal deviations, but care was taken during suturing in order to avoid any transposition (table 1).

### Statistical analysis

The data were saved and analyzed using SPSS software version 11.5 (SPSS Inc., Chicago, IL, USA). A P value less than 0.05 was considered statistically significant. Linear regression was used to calculate correlation coefficients.

### Results

In the 12 patients with SOOA, a total of 24 superior oblique muscles were operated. Two of these patients had previous horizontal muscle surgery (bilateral lateral rectus recession for exotropia).

The demographic data and comparative average preoperative and postoperative measurements are shown in tables 1 and 2 and figure 1.

Patients' age ranged from 3 to 34 years (mean, 19.3 ± 8.9 years). Follow-up ranged from 4 to 51 months (mean, 28.8 ± 20.7 months). Mean preoperative A-pattern was 26.4 ± 8.5 PD. Mean postoperative A-pattern was 1.7 ± 7 PD (P<0.001). Nine of the 12 patients (75%) had marked resolution of pattern (less than 10 PD), whereas A-pattern was reduced in all of them. One patient developed consecutive V-pattern (15 PD). The SOOA decreased from +3.5 ± 0.8 (range, 2-4) preoperatively to +0.8 ± 0.9 (range, 0-3) postoperatively. Overall a +2.7 decrease in mean overaction was seen, which was statistically significant (P<0.001).

**Table 1:** Presentation of patients with superior oblique overaction.\*

Case No.	Age (y)	Sex	SOOA	Effective graft length (mm)	Other Surgery†	Follow-up (mo)
1	24	F	4/4	7/7	BLR Rec (9mm)	44
2‡	22	M	4/4	9/9	BMR Res (9mm)	40
3	7	F	2/3	5/6	BLR Rec (9mm)	48
4§	20	F	2/4	5/9		40
5	23	F	4/4	7/7	BLR Rec (8mm)	51
6	18	F	4/3	7/6	BLR Rec (9mm)	46
7	15	F	4/4	9/9	BLR Rec (11mm)	48
8	31	F	4/4	9/9	BLR Rec (11mm); BMR Rec (5mm)¶	7
9	3	M	4/4	9/9	BLR Rec (10 mm) + RMR Res (6 mm)	4
10	21	M	2/3	5/6	BLR Rec (9mm)	6
11	13	M	2/3	5/6	BLR Rec (9 mm)	5
12	34	F	4/4	9/9	BLR Rec (8 mm)	6

\*x/x indicates values for right and left eyes respectively.

†Performed at least 2 months after the 1st operation.

‡Previous bilateral lateral rectus recessions.

§Previous bilateral lateral rectus recessions and a right medial rectus resection.

¶Was performed in 2 separate operations.

BLR, bilateral lateral rectus; BMR, bilateral medial rectus; mm, millimeter; mo, month; No., number; Rec, recession; Res, resection; RMR, right medial rectus; SOOA, superior oblique overaction; y, year.

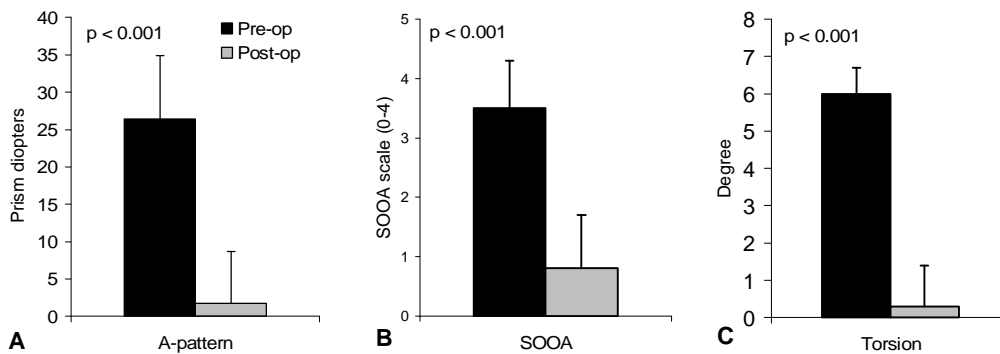
**Table 2:** Outcome of patients who underwent superior oblique lengthening with fascia lata for superior oblique overaction.

Case No.	SOOA		Intorsion		A-pattern (PD)		Exotropia (PD)	
	Preop	Postop	Preop	Postop	Preop	Postop	Preop	Postop
1	4/4	3/2	7	-1*	40	-15†	50	20
2	4/4	0/0	6	0	20	0	45	0
3	2/3	1/0	ND	ND	40	5	45	25
4	2/4	1/2	ND	ND	15	0	15	5
5	4/4	1/2	6	2	30	15	40	10
6	4/3	2/0	5	-1*	30	5	30	5
7	4/4	2/1	6	0	20	10	80	30
8	4/4	0/0	5	0	30	0	65	0
9	4/4	1/1	ND	ND	20	0	80	10
10	2/3	0/0	6	2	15	0	40	0
11	2/3	0/1	7	0	32	0	40	8
12	4/4	0/0	6	1	25	0	35	0

\*The negative numbers represent for extorsion.

†The negative number represents for V-pattern.

ND, non-determined; No., number; PD, prism diopter; Postop, postoperative; Preop, preoperative; SOOA, superior oblique overaction.



**Figure 1:** Postoperative change in A-pattern (A), superior oblique overaction (B) and fundus intorsion (C) in patients who underwent superior oblique elongation with fascia lata (solid bar, preoperative mean; gray bar, postoperative mean; SOOA, superior oblique overaction).

Seventy-five percent of the eyes had within +1 overaction of superior oblique after the surgery. Intorsion improved from  $+6 \pm 0.7$  degree to  $+0.3 \pm 1.1$  degree postoperatively ( $P < 0.001$ ). Pre and postoperatively, there was no vertical deviation in primary position. The

results were stable during the follow-up period. None of the patients showed superior oblique palsy or inferior oblique overaction after the surgery. Also, none of them developed recurrence or worsening of SOOA during the postoperative period.

Fascia spacer length did not correlate with change in the A-pattern ( $R^2 = 0.05$ ) or intorsion ( $R^2 = 0.05$ ). It was shown only minimal correlation with change in superior oblique overaction ( $R^2 = 0.42$ ; figure 2). Stereopsis did not change postoperatively. The donor sites were completely healed.

## Discussion

By introducing the silicon band expander surgery by Wright a controlled procedure for silicon oblique weakening became available.<sup>3,4</sup> This surgical technique gave the advantage of slackening the superior oblique tendon in a graded fashion without changing the insertion characteristics. In comparison to the other procedures, the incidence of postoperative superior oblique palsy was reported low after the silicone expander.<sup>2,4</sup> Accordingly, Wright reported superior oblique overaction to within +1 dysfunction in more than 80% and A-pattern correction in more than 90% of his operated patients, while superior oblique palsy was encountered in only one case.<sup>4</sup> Many surgeons have now adopted the silicone expander as the procedure of choice for superior oblique overaction. Silicone, although biocompatible and flexible, may be a source of discomfort in the first post-operative days and adds to the potential risk of secondary infection.<sup>1</sup> In addition, some cases of sterile orbital cellulites,<sup>7</sup> implant extrusion,<sup>8</sup> and production of abnormal ducts due to adhesions have been reported.<sup>1</sup> However, overall incidence of such complications is low and the silicone expander has been a reliable and safe method for treatment of superior oblique overaction.<sup>7</sup>

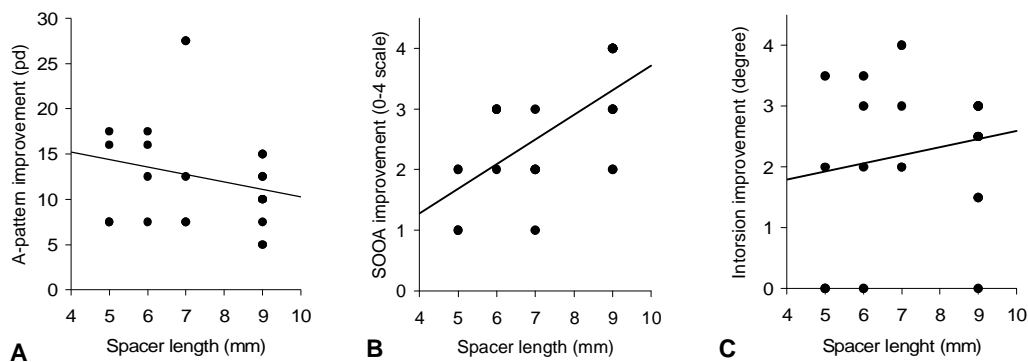
In our study, we tried to evaluate the results of superior oblique tendon elongation with autogenous fascia lata in order to overcome the complications associated with silicone

band, while preserving the advantages of the technique. At the last postoperative assessment, we achieved post-operative correction of A-pattern exotropia to within 10 PD and correction of superior oblique overaction to within +1 in 75% of our patients. These are comparable with previous reports by silicon expander.<sup>1,2,5</sup> In the present study, like other methods of treatment in severe cases,<sup>4,6</sup> superior oblique elongation with fascia lata undercorrected those with +4 superior oblique overaction. There was no evidence of superior oblique paresis (manifesting as limitation of depression in adduction) or any other significant complication at any post-operative assessments.

In comparison to silicon expander, fascia lata is more compatible physiologically, and theoretically it may prevent some complications that may arise by the use of silicone band. However, the operation time is longer and the donor site may be cosmetically unacceptable in young ladies.

The posterior SO tenectomy shares with elongation of the SO tendon with fascia lata the potential for reoperation and attempted reattachment, low risk of induced SO palsy, and allowance for asymmetric surgery. It has less surgical manipulation and operation time than SO tendon elongation; however, the amount of weakening is less correlated with the decrease in SOOA and maybe of limited use in severe SOOA. Moreover, there is more chance of recurrence in SOOA in posterior tenectomy group.<sup>9</sup>

Limitations of the present study were small number of patients and the absence of a randomized study design with appropriate controls. Despite these limitations, we believe that the results indicate that the superior oblique tendon fascia spacer may be a useful approach to weaken the superior oblique. How-



**Figure 2:** Correlation of fascia spacer length with reduction in A-pattern (A), superior oblique overaction (B) and fundus intorsion (C) in patients who underwent superior oblique elongation with fascia lata. Lines indicate linear regression curves. SOOA, superior oblique overaction; PD, prism diopter.

ever, further studies on larger patient groups are needed to determine its efficacy and safety and assess long term outcome. This technique can be considered as an alternative in patients with superior oblique overaction.

### Conclusions

The superior oblique tendon fascia lata spacer is a useful procedure in the treatment of A-pattern strabismus due to superior oblique overaction. This technique may be preferred to posterior tenectomy because of lower incidence of superior oblique overaction recurrence; however, the operation time is longer. Further studies with longer follow-up are recommended for evaluation of safety and efficacy of this method.

**Conflict of Interest:** None declared

### References

- 1 Stager DR Jr, Parks MM, Stager DR Sr. Long-term results of silicone expander for moderate and severe Brown syndrome (Brown syndrome "plus"). *J AAPOS* 1999; 3: 328-32.
- 2 Parks MM. Surgery for Brown's syndrome. In: Symposium on strabismus. Trans New Orleans Acad Ophthalmol. St Louis: Mosby; 1978. p. 157-77.
- 3 Wright KW, Min BM, Park C. Comparison of superior oblique tendon expander to superior oblique tenotomy for the management of superior oblique overaction and Brown syndrome. *J Pediatr Ophthalmol Strabismus* 1992; 29: 92-7.
- 4 Wright KW. Superior oblique silicone expander for Brown syndrome and superior oblique overaction. *J Pediatr Ophthalmol Strabismus* 1991; 28: 101-7.
- 5 Sharma P, Khokhar S, Thanikachalam. Evaluation of superior oblique weakening procedures. *J Pediatr Ophthalmol Strabismus* 1999; 36:189-95.
- 6 Rosenbarn A. Clinical strabismus management SAUNDERS, Philadelphia, USA; 1999. p. 17.
- 7 Pollard ZF, Greenberg MF. Results and complications in 66 cases using a silicone tendon expander on overacting superior oblique with A-pattern anisotropies. *Binocul Vis Strabismus Q* 2000; 15: 113-20.
- 8 Von Noorden GK. Principles of surgical treatment In: von Noorden GK, Campos EC, eds. Binocular Vision and Ocular Motility. 6th ed. St. Louis, Mosby, 2002. p. 579.
- 9 Shin GS, Elliott RL, Rosenbaum AL. Posterior superior oblique tenectomy at the scleral insertion for collapse of A-pattern strabismus. *J Pediatr Ophthalmol Strabismus* 1996; 33: 211-8.