

Variation, Length and Width of Tendinous Portion of Palmaris Longus and Forearm Length and Height: Is there a link? A Cadaver Study of Adult Iranians

M. Karimi Mobarakeh, M. Ghadi Pasha¹,
M. Moaghari poor¹

Abstract

Background: Palmaris longus (PL) is a muscle with marked variations. It is harvested as a tendon graft in many surgical procedures in which a certain length of tendon is required. The aims of the present study were to determine the variations of this tendon in Iranian population and to find whether the length of PL tendon could be estimated by measuring the forearm length and height.

Methods: We examined 128 forearms of 64 cadavers. We dissected out the tendons to measure their lengths and widths. The width of the tendon was measured at its proximal end. The forearm length and height were measured from the styloid process of the ulna to the tip of the olecranon with the forearm in neutral rotation. The height of cadavers were measured from crown to the heel in supine position.

Results: The palmaris longus muscles were absent bilaterally in 5 (7.8%) and unilaterally in 14 (21.8%) cadavers. The overall prevalence of the absence of PL (unilateral or bilateral) was 29.6% (24 forearms of 19 cadavers). The mean length and width of the PL were 14.2 ± 6.3 mm and 12.8 ± 7.2 mm in males and 4.00 ± 1.9 mm and 4 ± 2.1 mm in females, respectively. The mean forearms length and cadavers' height were 29 ± 1.6 cm and 172.6 ± 9.1 cm in males and 28 ± 1.2 cm and 166.5 ± 8.9 cm in females, respectively. A significant correlation was found between the length of the tendon and forearm in both males ($P < 0.001$) and females ($P < 0.001$). In contrast, there was not statistically significant correlation between the forearm length and width of the tendon in either males or females ($P = 0.007$ in males and females).

Conclusions: The results of this study indicate that the length of palmaris longus tendon can be estimated based on forearm length. This estimation might be useful for surgical intervention.

Iran J Med Sci 2008; 33(3): 164-168.

Keywords • Cadaver • variation • forearm • Iranian

Introduction

Palmaris longus (PL) is a muscle with marked variations. It may be digastric, duplicated, have a proximal tendon, end in antebrachial fascia, or it may be absent.

Department of Orthopaedic,
Shahid bahonar hospital,
¹Legal medicine organization,
Kerman, Iran.

Correspondence:

Mahmood Kkarimi Mobarakeh MD,
Department of Orthopaedic,
Shahid bahonar hospital,
Kerman, Iran.

Tel/Fax: +98 341 2722988

Email: drkarimi_m@yahoo.com

Submitted: 27 December 2007

Revised: 6 July 2008

Accepted: 31 July 2008

Normally, PL is a slender fusiform muscle medial to flexor carpi radialis, and it arises from medial epicondyle by common flexor tendon from adjacent intermuscular septa and antebrachial fascia. Its long slender tendon passes anterior to the flexor retinaculum and attaches to its distal half and centrally to the palmar aponeurosis.

PL does not play a major role in wrist flexion as the stronger flexors carpi radialis and ulnaris do. The only function of this muscle, if existed, is as a flexor of the proximal phalanges because its tendon splitting around flexor digitorum superficialis to be attached to proximal phalanges.¹ For the above reasons, PL is harvested as a tendon graft in many surgical procedures in which a certain length of tendon is required. If the length of PL tendon is not long enough to be used in long defects, more suitable tendons should be taken. PL muscle, though of little functional use to the human upper limb, is assumed to have great importance when used as a donor tendon for transfer. It would be useful if we can estimate the length of PL tendon before surgery.

The prevalence of absence of PL has been extensively studied.² There is a wide variation in the reported prevalence of PL absence in different ethnic groups.^{3,4} There is only one report that documented the prevalence of its absence in Iranian population by clinical examination.⁵ Some authors suggest a relationship between PL absence and other anomalies of the hand such as functional absence of the flexor digitorum superficialis to the little finger.^{6,7}

There are many clinical tests for assessment of PL tendon. The standard test is Schaeffer's test in which the subject is asked to oppose the thumb to the little finger and then flex the wrist.⁸

The aims of the present study were to determine the variations of this tendon in Iranian population and compare it with other Asian population. We also aimed to measure the length and width of PL tendon and forearm length and height. Based on these results, we studied whether the length of PL tendon could be estimated by measuring the forearm length and height.

Subjects and Methods

One hundred twenty eight forearms of 64 adult Iranian cadavers (38 males and 26 females) aged between 16 and 83 years (mean 41.1 ± 18.6 for men and 39.2 ± 16 for women) were examined in Kerman Forensic Medicine Organization during a one-year period. The cadavers were evaluated in less than 3 days after death. We dissected out the PL tendons and measured their lengths and widths. The length was

measured from the distal end to its proximal end. Distal end is defined as the point where a line connecting the pisiform and tubercle of the scaphoid bone crosses the PL tendon, and proximal end is defined as the most distal point of the muscle-tendon border irrespective of volar or dorsal side.⁹

The width of the tendon was measured at its proximal end. The length and width of each tendon were measured to the closest 0.1 mm using a slide caliper. The forearm length and height were measured in centimeter using a measure tape from the styloid process of the ulna to the tip of the olecranon with the forearm in neutral rotation. The heights of cadavers were measured from crown to the heel in supine position.⁹ We also calculated the ratio of the lengths of the PL tendons to the forearms lengths and cadavers' heights. All statistical analyses were carried out using SPSS software (version 13). The prevalence of absence of PL (unilateral or bilateral) presented with a 95% confidence interval. The associations between absence of PL and the body side and gender were assessed using Chi-square test. The relationships between the length and /or width of the PL tendon and forearm length and height were expressed by Pearson's correlation coefficient. Student's *t* test was used for statistical analysis. P values of <0.05 were considered as statistically significant.

Result

The PL was absent unilaterally in 14 cadavers (21.8%), while it was absent bilaterally in 5 (7.8%) cadavers. Overall prevalence of the absence of PL (unilateral or bilateral) was 29.6% (24 forearms of 19 cadavers). Among men, PL was absent on the right side in 5 (13.2%), on the left side in 3 (7.9%), and bilaterally in 2 (5.3%) cadavers. Among women, PL was absent on the right side in 2 (7.7%), on the left side in 4 (15.4%) and bilaterally in 3 cadavers (11.5%). The overall prevalence of PL absence was 26.4% in men (10 men) and 34.6% in women (9 women). There was no significant difference in overall prevalence of PL absence between males and females ($P=0.543$). We did not observe any double PL tendon.

The mean lengths and the mean widths of the PL were 14.2 ± 6.3 mm and 4.00 ± 1.9 mm in males, and 12.8 ± 7.2 mm and 4 ± 2.1 mm in females, respectively. The mean forearms length and cadavers' height were 29 ± 1.6 cm and 172.6 ± 9.1 cm in males, and 28 ± 1.2 cm and 166.5 ± 8.9 cm in females, respectively. The mean percentage ratio of the length of the PL tendon to the forearm length and cadavers' height was 58.4 ± 2 and 9.8 ± 0.3 in males and

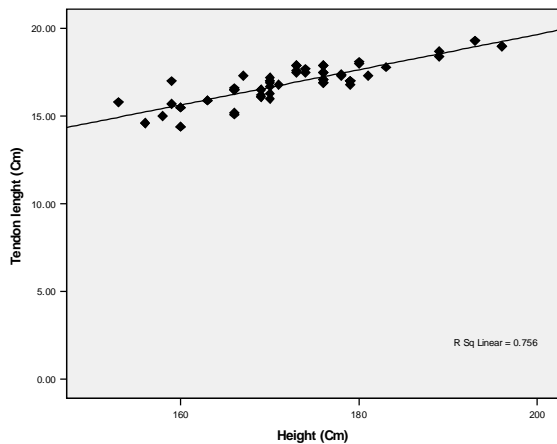
59.5 ± 3.3 and 10 ± 0.4 in females, respectively (table 1). There was no significant correlation between the cadavers' height and length of PL in men (P=0.145) and women (P=0.375; figure 1). There was no significant correlation between cadavers' height and width of PL in men (P=0.796) and women (P=0.504), respectively. The mean forearm lengths and cadavers' heights were significantly different between males and females (P<0.001 and P=0.014, respectively). The mean length and

width of the PL tendon were not significantly different between males and females respectively (P=0.248 and P=0.139).

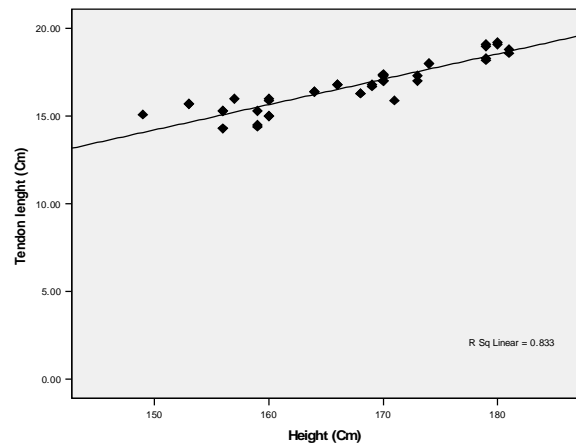
A significant correlation was found between the lengths of the tendon and the forearm in both males (P<0/001) and females (P<0.001; figure 2). In contrast, there was not statistically significant correlation between forearm length and the width of the tendon in either males or females (P=0.007 in both males and in females; figure 3).

Table 1: The length and width of the palmaris longus tendon and length of the forearm and height in men and women

	Tendon Length (mm)	Tendon Width (mm)	Forearm Length (mm)	$\frac{\text{Tendon Length}}{\text{Forearm Length}} \times 100\%$	$\frac{\text{Tendon Length}}{\text{height}} \times 100$
Men	14.18 ± 6.28	4.21 ± 1.89	28.85 ± 1.62	58.4 ± 2	9.8 ± 0.3
Women	12.79 ± 7.18	3.68 ± 2.08	27.93 ± 1.20	59.5 ± 3.3	10 ± 0.4
Total	13.62 ± 6.66	4.000 ± 1.98	28.47 ± 1.53	59.1±5.4	9.9±0.9

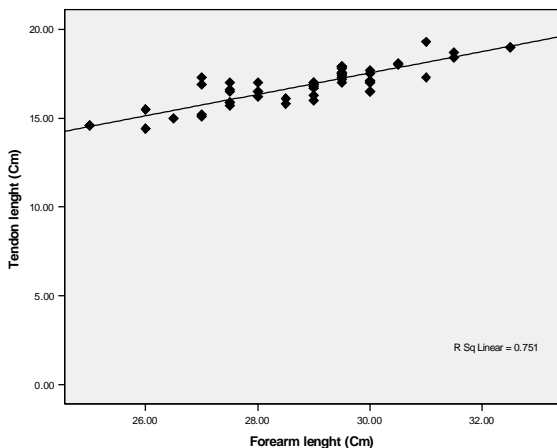


Men

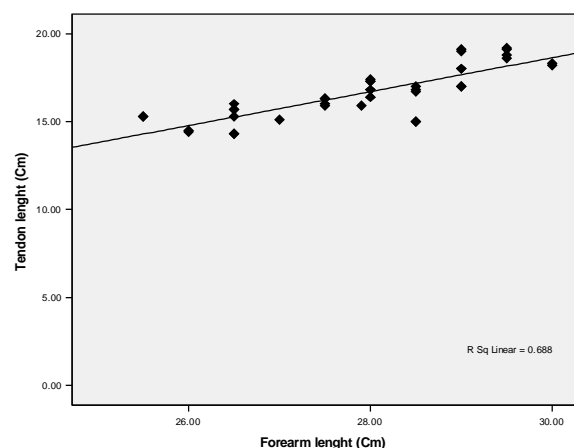


Women

Figure 1: (A diagram showing the relationship between the palmaris longus tendon length and height. Neither male nor female data show statistically significant correlation.



Men



Women

Figure 2: A diagram showing the relationship between the palmaris longus tendon length and forearm length. Both male and female data show statistically significant correlation.

Correlation between palmaris longus and height and forearm length

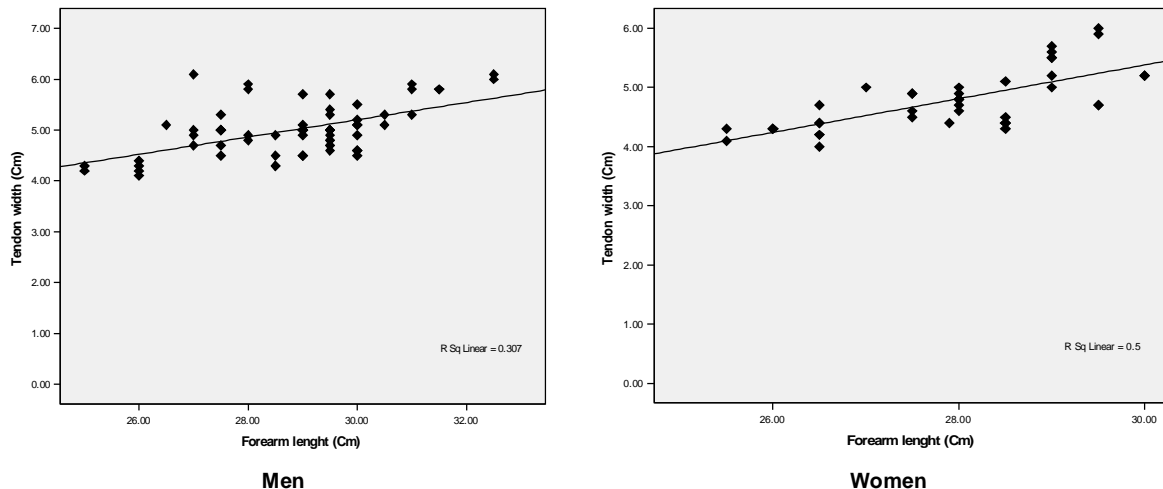


Figure 3: A diagram showing the relationship between the palmaris longus tendon width and forearm length. Neither male nor female data show statistically significant correlation.

Discussion

The PL muscle that apparently undergoes a process of phylogenetic degeneration,¹⁰ contributes in part to wrist and metacarpophalangeal flexion.¹ Some studies have shown that PL muscle is absent in approximately 20% of Whites, 4% of Blacks, 4% of Japanese,¹¹ and 4.6% of Chinese.¹² Kapoor reported palmaris longus agenesis in 17.2% of 500 Indian patients.¹³ In the present study, overall prevalence of the absence of PL (unilateral or bilateral) was 29.6% (24 forearms of 19 cadavers). It is interesting to note that textbooks of hand surgery quote a prevalence of absence of unilaterally 30% and bilaterally 15%.¹⁴⁻¹⁶ These values are higher than those obtained for the Chinese and Japanese, however, comparable with Iranian population.

There is disagreement in the literature regarding symmetry of the muscle absence, whether the absence is more common in women and association of the absence with other anomalies such as plantaris muscle.¹⁷ Most studies indicate that the absence is more common bilaterally, on the left side, and/or in women.^{3,18} In the present study, there were no statistically significant differences between the prevalence of the absence and body sides ($P=0.456$), gender ($P=0.269$), and laterality ($P=0.358$).

Milford reported that the PL tendon was long enough for an approximately 15 cm long grafts.¹⁹ Our results show that the length of the tendinous portion of the PL in the Iranians is approximately 14.2 ± 6.3 mm in males and 12.8 ± 7.2 mm in females. The ratio of the tendon of gastrocnemius muscle to the tibia also showed a similar value in White and Black individuals carried out by Williams and Grim in the United States.²⁰ Ito et al in a study

carried out in Japanese population showed that in both males and females, there was a statistically significant correlation between the PL tendon length and forearm length.⁹ We also found that the mean percentage ratio of the length of the PL tendon to the forearm length was 58.4 ± 2 in males and 59.5 ± 3.3 in females, respectively. We also found a significant correlation between the length of tendon and the forearm in both males ($P<0.001$) and females ($P<0.001$). The results of the present study and others show that the length of the PL tendon could be estimated from the length of the forearm (tendon length = forearm length $\times 58\%$ in male and $\times 59\%$ in female).

Cross-sectional area of the tendons in the lower extremities is determined by individual and gender differences,²¹ for instance the semitendinous tendon of the knee.²² Tendon width is determined by acquired elements, such as mechanical stress and force due to muscle strength. However, in the present study, the width of the PL tendon was almost constant and there was not significant correlation between this variable and forearm length or cadaver's height.

In conclusion, the results of our study show that overall prevalence of the absence of PL is approximately 30%, and it is equal in both body sides and between men and women. It would be possible to estimate the approximate length of PL tendon based on the forearm length before a surgical intervention.

Acknowledgments

We thank Dr. M. R. Droodian and Dr. Soheil Talebi for their comments and the assistance with review of articles and statistical analysis.

Conflict of Interest: None declared

References

- 1 MaMinn RMH. Last's Anatomy. 9th ed. Churchill Livingstone. London; 1997. p. 89.
- 2 Ceyhan O, Mavt A. Distribution of agenesis of palmaris longus muscle in 12 to 18 years old age groups. *Indian J Med Sci* 1997; 51: 156-60.
- 3 Thompson JW, McBatts J, Danforth CH. Hereditary and racial variations. in the musculus palmaris longus. *Am J Phys Anthropol* 1921; 4: 205-20.
- 4 Angelo BM Machado, Liberato JA Di Dio. Frequency of the musculus palmaris longus studied in vivo in some Amazon Indian. *American Journal of Physical Anthropology* 1967; 27: 11-9.
- 5 Shahriar Kamrani R, Abass Zadeh MR, Jafari SM. Variations Palmaris Longus and Superficial Flexor of the Fifth Finger. *Iranian journal of orthopaedic surgery* 2005; 1: 21-4.
- 6 Elizabeth O'Sullivan, Barry S Mitchell. Association of the absence of the palmaris longus tendon with an anomalous superficial palmar arch in the human hand. *J Anat* 2002; 201: 405-8.
- 7 Thompson NW, Mockford BJ, Rasheed T, Herbert KJ. Functional absence of the flexor digitorum superficialis to the little finger and absence of the palmaris longus—is there a link? *J Hand Surg (Br)* 2002; 7: 433-4.
- 8 Schaeffer JP. On the variations of the palmaris longus muscle. *Anat Rec* 1909; 3: 275-8.
- 9 Ito MM, Aoki M, Kida MY, et al. Length and width of the tendinous portion of the palmaris longus: a cadaver study of adult Japanese. *J Hand Surg [AM]* 2001; 26: 706-10.
- 10 William L. Straus Jr. The homologies of the forearm flexors: Urodeles, lizards, mammals. *American Journal of Anatomy* 2005; 70: 281-316.
- 11 Honma T. Flexor muscle of the forearm. In: Sato T, Akita K, eds. *Nihonjin no karada*. Tokyo: Tokyo Daigaku Shuppankai; 2000. p. 110.
- 12 Sebastin SJ, Lim AY, Wong HB. Clinical assessment of absence of the palmaris longus and its association with other anatomical anomalies- A Chinese population study. *Ann Acad Med Singapore* 2006; 35: 249-53.
- 13 Kapoor SK, Tiwari A, Kumar A, et al. Clinical relevance of palmaris longus agenesis: Common anatomical aberration. *Anat Sci Int* 2008; 83: 45-8.
- 14 Wright PE. Flexor and Extensor tendon Injuries. In: Campbell's operative Orthopaedic. Tenth ed. Mosby Company. 2003. p. 3454-5.
- 15 Henz VR, Chase RA. Divided flexor tendon. In: Henz VR, Chase RA, editors. *Hand Surgery-A Clinical Atlas*. Philadelphia: WB Sauderse; 2001. p. 364.
- 16 Smith P. Injury. In: Smith P, editor. *Lister's the Hand-Diagnosis and Indication*. London: Churchill Livingstone; 2002. p. 11.
- 17 George R. Co-incidence of the palmaris longus and plantaris muscles. *Anat Rec* 1953; 116: 521-3.
- 18 Reimann AF, Daseler EH, Anson BJ, et al. The palmaris longus muscle and tendon; a study of 1600 extrimities. *Anat Rec* 1944; 89: 495-505.
- 19 Milford L. Palmaris longus. In: Edomson AS, Crenshaw AH, eds. *The Hand*. St Louis: Mosby; 1982. p. 13.
- 20 Williams GD, Grim GE, Wimp JJ, Wayne TF. Calf muscles in American whites and negroes. *American Journal of Physical Anthropology* 1930; 14: 242.
- 21 Kanehisa H, Ikegawa S, Fukunaga T. Comparison of muscle cross-sectional area and strength between untrained women and men. *Eur J Appl Physiol Occup Physiol* 1994; 68: 148-54.
- 22 Hamada M, Shino K, Mitsuoka T, Abe N, Horibe S. Cross-sectional area measurement of the semitendinosus tendon for anterior cruciate ligament reconstruction. *Arthroscopy* 1998; 14: 696-701.