

Isolated Talonavicular Joint Tuberculosis in a Child – Rare Location of Koch's Bacillus: A Case Report

Mohd Faizan¹, MBBS, MS;
Latif Z. Jilani¹, MBBS, MS, MRCS;
Saifullah Khalid², MBBS, MD;
Mazhar Abbas¹, MBBS, MS;
Dilshad Anwar¹, MBBS, DORTH

¹Department of Orthopaedic Surgery, Jawahar Lal Nehru Medical College, Aligarh Muslim University, Aligarh, UP, India;

²Department of Radiodiagnosis, Jawahar Lal Nehru Medical College, Aligarh Muslim University, Aligarh, UP, India

Correspondence:

Mohd Faizan, MS;
Department of Orthopaedic Surgery,
Jawahar Lal Nehru Medical College,
Aligarh Muslim University, Aligarh,
UP, 202002 India

Tel: +91 571 2709641

Email: mohdfaizan2002@gmail.com

Received: 15 April 2015

Revised: 22 June 2015

Accepted: 05 July 2015

What's Known

- To the best of our knowledge, there has been only one previously reported case of isolated tuberculosis of the talonavicular joint in children.

What's New

- This report is the second case of isolated tuberculosis of the talonavicular joint in children.
- Diagnosis of tuberculosis of the foot is usually delayed or missed due to vague presentations. However, we managed early diagnosis clinico-radiologically as confirmed by fine-needle aspiration cytology.

Abstract

Tuberculosis of the foot is an uncommon entity and the reported incidence is 0.1% to 0.3%. The isolated tuberculosis of talonavicular joint is exceptionally rare. In tuberculosis of the foot and ankle, the presentation is usually nonspecific. The diagnosis of tuberculosis affecting foot is difficult, especially when it is isolated. In doubtful cases, diagnosis should be confirmed by histopathological examination. Unlike pulmonary Kochs, osteoarticular tuberculosis should be treated with antituberculous drugs for a longer duration, preferably for 18 months. We are reporting a case of a 9-year-old boy with tuberculosis of the isolated talonavicular joint and the diagnosis was suggested on plain radiography, which was further confirmed by histopathological examination. He was treated with first-line antitubercular drugs. A good recovery was seen following the commencement of anti-tuberculosis treatment. After two years of follow-up, he was pain-free and doing all of his routine activities. In tuberculosis of the foot, diagnosis is usually delayed or missed due to vague presentation.

Please cite this article as: Faizan M, Latif Z. Jilani LZ, Khalid S, Abbas M, Anwar D. Isolated Talonavicular Joint Tuberculosis in a Child – Rare Location of Koch's Bacillus: A Case Report. *Iran J Med Sci.* 2017;42(1):85-88.

Keywords • Tuberculosis • Foot • Talonavicular coalition
• Antitubercular drugs • Child

Introduction

Skeletal tuberculosis (TB) accounts for around 3-5% of all cases, of which about 10% occurs at the ankle and foot region.^{1,2} In most cases, tuberculosis of the foot affected a single bone,³ and tarsal bones are rarely affected.⁴ Diagnoses of these cases are difficult and delayed because of the overlapping and vague symptoms. In the English literature, very few cases of talonavicular tuberculosis in adults have been reported. On PubMed search (using keywords "talonavicular", "children", "tuberculosis"), only one case of isolated talonavicular tuberculosis in children has been reported by Birjandinejad et al.⁵ To the best of our knowledge, we are reporting the second case of isolated talonavicular tuberculosis in a child.

Case Report

A 9-year-old boy presented with a 6-month history of pain and swelling over the medial aspect of the left foot with unknown etiology. The patient was not able to bear weight on the affected foot. There was no history of fever, loss of appetite and other

constitutional symptoms. Mild swelling and tenderness were present over the talonavicular joint. The range of motion of the affected foot was painfully restricted. The plain radiographs of foot AP and oblique views showed diffuse osteopenia with marginal erosion of the articular surface of talus and navicular and narrowing of the talonavicular joint with prominent soft tissue medial to the talonavicular joint (figure 1).

Hematological investigations were within normal limits except for the raised erythrocyte sedimentation rate (ESR) (30 mm 1st hour) and positive C-reactive protein (CRP-10). We could not get MRI done because of the financial constraint of the patient. We performed needle biopsy from the talonavicular joint under image intensifier and aspirated thick grayish-white material, which was sent for histopathology, culture, and acid-fast bacillus (AFB) staining. There were no acid-fast bacilli seen on AFB staining. On histopathological examination, epithelioid granulomas with caseating necrosis were seen which was suggestive of tuberculosis (figure 2).

The growth of Koch's bacillus on culture further confirmed our diagnosis. Anti-tuberculosis therapy (ATT) was started with the first-line of 4 drugs, including rifampicin, isoniazid, ethambutol, and pyrazinamide. After three months, ethambutol was stopped and the remaining 3 drugs continued for the next 3 months, followed by rifampicin and isoniazid for one year. We gave ATT for a longer duration because of the high prevalence of osteoarticular tuberculosis in our country. The patient responded satisfactorily with ATT. At the end of week 8, pain and swelling started to disappear. The patient had no pain on walking, the range of motion of the affected foot was pain-free, and there was no secondary deformity seen in the foot at the end of treatment. After 18 months, the ESR and CRP were within normal limits. The plain radiological findings showed remineralization of bones with sclerosis of joint margins and reformation of the joint space (figure 3).

The patient was able to walk pain-free and is presently doing all of his routine activities in the last 3-year follow-up. Written informed consent was obtained from the patient's legal guardian (father) for the publication of this paper and any accompanying images.

Discussion

The diagnosis of spinal and major joint tuberculosis such as the hip and knee is relatively easy. In contrast, the diagnosis of tuberculosis of small bones of the ankle and foot are often difficult

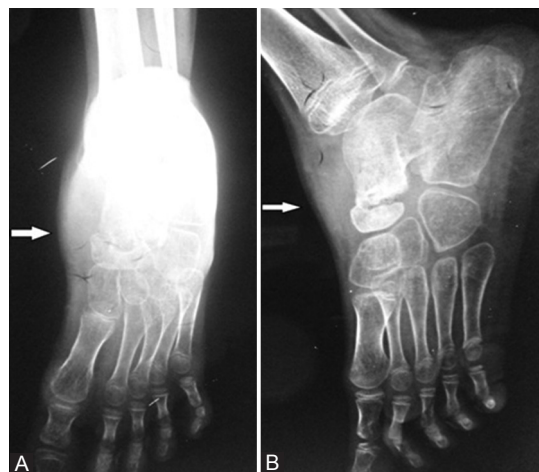

Figure 1: Pre-treatment radiographs of the foot (AP and oblique) showing diffuse osteopenia with narrowing of the talonavicular joint and erosion of the articular surface of talus and navicular and prominent soft tissue.

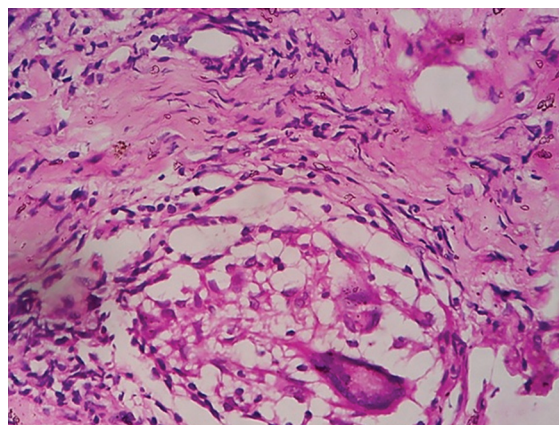


Figure 2: Histopathological examination showing well formed epithelioid cell granuloma along with Langerhans-type giant cell, lymphocytic infiltration, and fibrocollagenous tissue (100x).

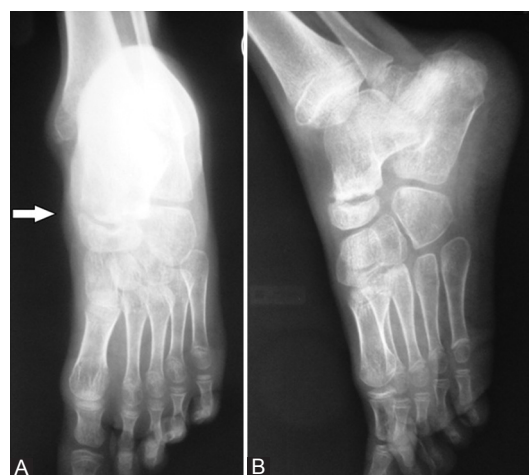

Figure 3: Post-treatment radiographs (AP and oblique) showing remineralization of bones with sclerosis of joint margins and reformation of the joint space of the talonavicular joint and disappearance of soft tissue.

and confusing; leading to delayed treatment and increased risks of secondary infection.⁶

The ankle and foot are rarely affected and comprises only 1% of all tubercular infections.^{1,7} The most common presentation of foot TB is a granulomatous focus adjacent to a joint, which can be easily missed on initial radiographs.⁷ The X-ray findings are fairly nonspecific and usually show an osteolytic lesion with occasional evidence of central sequestration seen in cases involving calcaneum.³ The absence of any specific radiographic features of infection in bone and joints leads to difficulty in the diagnosis of the localized lesion.⁸

The differential diagnosis includes pyogenic osteomyelitis, bone tumour, fungal osteomyelitis, and granulomatous diseases such as gout, sarcoidosis, and amyloidosis.⁹ Mittat et al. treated 37 patients with foot tuberculosis and observed five patterns of lesion radiologically, namely (i) Cystic type: this pattern is more common in calcaneum, (ii) Rheumatoid type: appears as a coalesced mass of the bone and seen in midfoot involvement, (iii) Subperiosteal type: subperiosteal scalloping of bone was noted on the outer surface of the cuboid, the base of the fifth metatarsal and talar head, (iv) Kissing type: lesion was present in one joint and symmetrical scalloped lesions had developed on the adjacent articular surfaces of the bones, (v) Spina ventosa type: found in the short tubular bone of the foot.¹⁰

TB of the foot is an uncommon entity and the reported incidence is 0.1% to 0.3%.³ TB of the foot can manifest as articular, soft tissue mass or an isolated bony lesion. Calcaneum is the commonest tarsal bone to be involved in isolated osseous tubercular involvement, followed by talus, distal end of the first metatarsal, navicular, cuneiform, and cuboid in descending order of incidence.¹¹ Isolated involvement of talonavicular joint is extremely rare and this is the second case to be reported on the isolated involvement of the talonavicular joint in children.

The clinical history may be unhelpful with TB of the foot as they usually have an insidious onset. The nonspecific features including pain, swelling, and localized tenderness may be present, but pyrexia or constitutional symptoms are usually absent. Hematological investigations are usually within normal limits except for the raised ESR and positive CRP as in the present case.

The treatment of choice for the patients with tuberculosis of the foot is ATT. Surgical debridement may be required along with medical treatment in some cases. Partial excision of the navicular bone is the surgical option for isolated navicular lesion. In the

present case, the patient responded well to ATT and became pain-free during the course of treatment; therefore, he was not subjected to any surgical procedure.

Conclusion

The tuberculosis of talonavicular joint is extremely rare. The nonspecific features including pain, swelling and localized tenderness may be present in the foot. A raised ESR and a positive C-reactive protein may be the only abnormal haematological investigation. When there is high clinico-radiological suspicion, needle biopsy should be performed and early treatment with ATT should be started in endemic areas.

Conflict of Interest: None declared.

References

1. Dhillon MS, Nagi ON. Tuberculosis of the foot and ankle. *Clin Orthop Relat Res.* 2002;107-13. PubMed PMID: 11964638.
2. Rasool MN. Osseous manifestations of tuberculosis in children. *J Pediatr Orthop.* 2001;21:749-55. PubMed PMID: 11675548.
3. Dhillon MS, Singh P, Sharma R, Gill SS, Nagi ON. Tuberculous osteomyelitis of the cuboid: a report of four cases. *J Foot Ankle Surg.* 2000;39:329-35. PubMed PMID: 11055024.
4. Dalldorf PG, Banas MP, Marquardt JD. Tuberculosis of the foot: a case report. *Foot Ankle Int.* 1994;15:157-61. PubMed PMID: 7951945.
5. Birjandinejad A, Parsa A, Ebrahimzadeh MH. Isolated tuberculosis of the talonavicular joint in a child. *Foot (Edinb).* 2012;22:255-7. doi: 10.1016/j.foot.2012.04.005. PubMed PMID: 22626906.
6. Tuli SM. Tuberculosis of the skeletal system (bones, joints, spine and bursal sheaths). 2nd ed. New Delhi: Jaypee Brothers Medical Publishers (P) Ltd; 1991.
7. Dhillon MS, Sharma S, Gill SS, Nagi ON. Tuberculosis of bones and joints of the foot: an analysis of 22 cases. *Foot Ankle.* 1993;14:505-13. PubMed PMID: 8314185.
8. Watts HG, Lifeso RM. Tuberculosis of bones and joints. *J Bone Joint Surg Am.* 1996;78:288-98. PubMed PMID: 8609123.
9. Choi WJ, Han SH, Joo JH, Kim BS, Lee JW. Diagnostic dilemma of tuberculosis in the foot and ankle. *Foot Ankle Int.* 2008;29:711-5. PubMed PMID: 18785421.

10. Mittal R, Gupta V, Rastogi S. Tuberculosis of the foot. *J Bone Joint Surg Br.* 1999;81:997-1000. PubMed PMID: 10615974.
11. Vijay V, Sud A, Mehtani A. Multifocal bilateral

metatarsal tuberculosis: a rare presentation. *J Foot Ankle Surg.* 2015;54:112-5. doi: 10.1053/j.jfas.2014.09.030. PubMed PMID: 25441279.