

# A Comparison of Immunohistochemical Expression of Epidermal Growth Factor Receptor and Human Epidermal Growth Factor Receptor 2 in Dental Follicles with Different Radiographic Sizes

Shirin Saravani<sup>1</sup>, DDS, MSc; Hamed Nemati Rezvani<sup>2</sup>, DDS, MSc; Mehrdad Shahraki<sup>2</sup>, DDS, MSc; Hamideh Kadeh<sup>1</sup>, DDS, MSc

<sup>1</sup>Oral and Dental Disease Research Center, Department of Oral and Maxillofacial Pathology, Faculty of Dentistry, Zahedan University of Medical Sciences, Zahedan, Iran;

<sup>2</sup>Department of Oral and Maxillofacial Surgery, Faculty of Dentistry, Zahedan University of Medical Sciences, Zahedan, Iran

## Correspondence:

Hamideh Kadeh, DDS, MSc;  
School of Dentistry, Azadegan St., Postal code: 98167-43463, Zahedan, Iran

Tel: +98 54 33441814

Email: h\_a\_kade@yahoo.com

Received: 18 June 2023

Revised: 11 November 2023

Accepted: 28 November 2023

## What's Known

- Normal dental follicles of impacted teeth can be distinguished using normal radiographic size.
- The normal dental follicle of impacted teeth can evolve into odontogenic cysts and tumors.

## What's New

- The EGFR and HER2 expression was high in both normal and abnormal follicles.
- Epidermal growth factor receptor and human epidermal growth factor receptor 2 expression was not significantly different between the radiographic of normal and abnormal follicles.

## Abstract

**Background:** Odontogenic cysts and tumors develop from the dental follicle of asymptomatic impacted teeth. Odontogenic tissues express the epidermal growth factor receptor family (EGFR), which mediates cell proliferation, survival, and neoplastic differentiation. The present study aimed to compare the immunohistochemical expression of EGFR and human epidermal growth factor receptor 2 (HER2) in the dental follicle of impacted wisdom teeth with normal and abnormal radiographic size.

**Methods:** In this analytical study, immunohistochemical staining of EGFR and HER2 was performed on 30 normal and 30 abnormal follicles of impacted third molars. Follicles with a width of  $<2.5$  mm were considered normal, whereas those with a width of  $\geq 2.5$  mm were regarded as abnormal. The immunoreactive score (IRS) was used to report the expression levels of EGFR and HER2. The obtained data were analyzed using SPSS software. Age and sex were compared in normal and abnormal groups with independent *t* test and Chi square test, respectively.  $P < 0.05$  was considered statistically significant.

**Results:** The EGFR and HER2 overall expression was high in all normal and abnormal follicles. The comparison of the percentage of stained cells and intensity of EGFR and HER2 staining in normal and abnormal follicles were not significantly different ( $P=0.73$ ,  $P=0.63$ ,  $P=0.95$ , respectively).

**Conclusion:** Due to the high expression of EGFR and HER2 in normal and abnormal follicles, as well as the lack of significant differences in these two groups, the radiographic size of dental follicles might not indicate the potential capabilities of their cells, and more research in this field is recommended.

Please cite this article as: Saravani S, Nemati Rezvani H, Shahraki M, Kadeh H. A Comparison of Immunohistochemical Expression of Epidermal Growth Factor Receptor and Human Epidermal Growth Factor Receptor 2 in Dental Follicles with Different Radiographic Sizes. Iran J Med Sci. doi: 10.30476/IJMS.2023.98602.3121.

**Keywords** • ErbB receptors • Dental sac • Molar, third • Radiography • Tooth extraction

## Introduction

The dental follicle is a connective tissue originating from loose ectomesenchyme that surrounds the enamel organ and the dental papilla of the tooth germ.<sup>1</sup> Dental follicles are involved in

cementum, periodontal ligament, and alveolar bone formation.<sup>2</sup> *In vitro* studies indicated that dental follicle stem cells can differentiate into osteoblasts, adipocytes, cardiomyocytes, chondrocytes, neurons, hepatocytes, salivary gland cells, and ductal cells.<sup>3</sup> Radiographically, the dental follicles surrounding the impacted teeth present as a semicircular radiolucency around unerupted teeth.<sup>4</sup> Dental follicles with pericoronal spaces of <2.5 mm are considered normal, but follicular space of  $\geq 2.5$  mm is recognized as radiographic pathology.<sup>4, 5</sup> Nonetheless, limited histopathological studies confirmed this radiographic criterion, and more detailed studies are required in this regard.<sup>6</sup>

Growth factors are polypeptides that regulate cell proliferation and differentiation.<sup>7</sup> One of these growth factors is the ErbB family from receptor tyrosine kinases. This family performs is essential for normal epithelial cell activity.<sup>8</sup> The epidermal growth factor receptor family (EGFR) is the first member of this transmembrane receptor family, which is located on chromosome 7p12 and more than 40 ligands control its signaling.<sup>9</sup> The second member of this family is human epidermal growth factor receptor 2 (HER2), a 185-kDa transmembrane protein, which is located on chromosome 17q21-22.<sup>10</sup> EGFR and HER2 overexpression has been reported in odontogenic cysts and tumors.<sup>11-13</sup>

The extraction of asymptomatic impacted third molars with their associated dental follicles has always been a controversial issue. One of the indications for impacted tooth extraction is the presence of abnormal changes in the dental follicle on radiography.<sup>4</sup> However, studies reported that odontogenic cysts and tumors develop from the dental follicle of asymptomatic impacted teeth. Therefore, it is critical to identify the role of follicle cells in the pathogenesis and progression of odontogenic lesions.<sup>2</sup> In light of

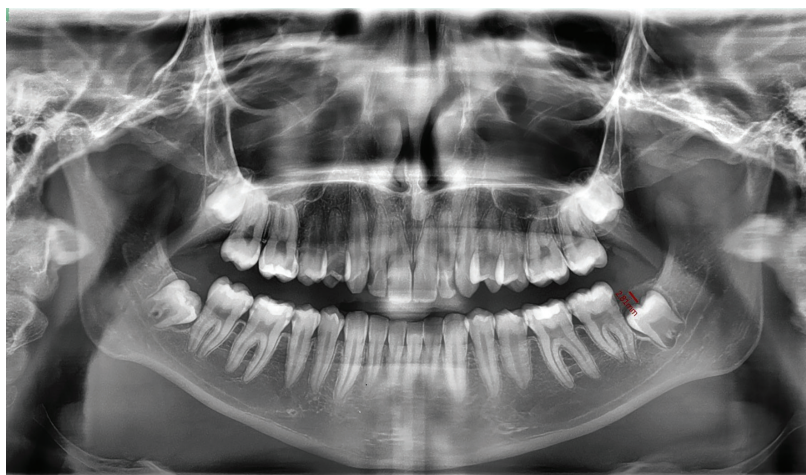
the aforementioned issues, the present study aimed to compare the immunohistochemical expression of EGFR and HER2 in the follicles of impacted wisdom teeth with normal and abnormal radiographic size.

## Patients and Methods

The current case-control study was approved by the Ethics Committee of Zahedan University of Medical Sciences (code: IR.ZAUMS.REC.1395.037). Due to the small number of eligible patients and the high cost of histopathological evaluation and immunohistochemical staining, all eligible samples were evaluated over one year. Initially, all patients who were referred to the oral surgery clinic, affiliated with Zahedan School of Dentistry (Zahedan, Iran), for the extraction of the impacted third molars were clinically evaluated by an oral and maxillofacial surgeon.

All panoramic radiographs were prepared by Ortho Pantomo Gram device (Planmeca, Finland), transferred to Planmeca Romexis viewer, and calibrated to real size. An expert oral and maxillofacial radiologist measured the pericoronal space of the impacted wisdom tooth from distal, mesial, and occlusal surfaces using a "measuring tool", and the greater width was recorded (figure 1). Radiographic measurements were performed in a room with low light. According to the radiographic findings, follicles less than 2.5 mm in width were considered normal, while those  $\geq 2.5$  mm in width were considered abnormal.<sup>4</sup>

After providing necessary explanations about the aims of the study, written informed consent was obtained from all the patients who were systemically healthy. An oral and maxillofacial surgeon extracted the impacted wisdom teeth and their accompanying follicles. Then, complete information about the patient, including age,



**Figure 1:** Radiographic feature shows the measurement of greater pericoronal width of dental follicle.

sex, surgical site, and radiological size of the follicle, was recorded in an information form and assigned a code. The specimen was then sent to the pathology laboratory in a 10% formalin solution.

In the laboratory, paraffin blocks of specimens were initially prepared. Thereafter, 3-5 micron sections were made from the blocks. Haematoxylin and eosin (H&E) stained pathology slides were prepared, and an oral and maxillofacial pathologist confirmed the diagnosis of dental follicles. Afterward, the patient was informed of the results. The follicles that were developed into cysts or tumors after fixation and microscopic examinations, as well as necrotic and infectious follicles, were excluded. All immunohistochemical staining steps were performed for other follicles that had sufficient tissue according to the instructions in the EGFR and HER2 staining kit as follows:

#### *Immunohistochemical Staining*

In the first step, antigen retrieval was performed for 30 min (Ethylenediaminetetraacetic acid [EDTA]; PH=8 for EGFR and PH=9 for HER2) using a microwave. Following that, the basket containing the slide was cooled in running water, but not in direct contact with the slides. The basket of slides was placed in a jar containing Tris-buffered saline (TBS) buffer. Subsequently, the slides were rinsed, and the tissues were encircled by an immunohistochemical Pen.

In the following stage, the primary antibody of mouse monoclonal anti-EGFR antibody (EmergoEurope, Pleasanton, CA, Lot: E858) and Rabbit anti-c-erbB-2/HER2 monoclonal antibody clone SP3 (Master diagnostica, Lot: 0186-02), which were diluted (1:50) and was ready to use, was poured on the specimens for 30 min. Then, the basket of slides was immersed in three TBS containers for 5 min, and the excess buffer was rinsed and removed from the slides. Following that, secondary antibodies were poured on the specimens for 1 hour, after which the slides were rinsed in three TBS containers, and then the slides were cleaned up. Next, the obtained Dap solution was poured onto the specimens for 5 min, and the slides were rinsed in a distilled water container. Afterward, hematoxylin was poured onto the tissues, and the slides were then immersed in distilled water for 1 min. The specimens were taken in alcohol (90 °C and then 100 °C). Subsequently, the slides were immersed in a xylene container for 2 min. Finally, the slides were mounted by a coverslip. It is worth mentioning that squamous cell carcinoma samples were used as the positive control, and the primary antibody was

removed as the negative control.

#### *Microscopic Evaluation*

Following the completion of immunohistochemical staining, the slides were evaluated under a light microscope (Leica, USA). The expression of EGFR and HER2 in the cell membrane and cytoplasm of odontogenic epithelial cells in dental follicles was assessed using the immunoreactive score (IRS) and based on the staining intensity and percentage of stained cells. The overall intensity was rated based on a four-point scale (0, 1, 2, and 3 for none, light, medium, or dark brown staining, respectively). Moreover, the percentage of staining was rated as follows: 0 (no staining), 1 (<10% of cells), 2 (11%-50% of cells), 3 (51%-80% of cells), 4 (81%-100% of cells).<sup>14</sup> Then, the IS score (0-12) was obtained by multiplying the percentage of positive cells by the intensity of staining. The expression was classified as low if the score was <3 and high if it was ≥4.

#### *Statistical Analysis*

All analyses were performed using the SPSS software version 23.0 (SPSS Inc., Chicago, IL, USA). The obtained data were expressed as frequency and percentage. Statistical analysis was performed using the Chi square test. Age and sex were compared in normal and abnormal groups using an independent *t* test and Chi square test, respectively.  $P < 0.05$  was considered statistically significant.

## **Results**

In this study, 60 dental follicles were examined. Radiographically, 30 follicles were normal, and 30 cases were abnormal. The study included 33 (55%) male and 27 (45%) female patients. Moreover, 14 (46.7%) normal follicles and 13 (43.3%) abnormal follicles were related to female patients ( $P=0.79$ ). In addition, 34 (56.7%) follicles were located on the left side of the patients, out of which 18 follicles (60%) were normal, and 16 follicles (53.3%) were abnormal.

The participant's age range was between 18-34 years old, and their mean age was  $25.2 \pm 3.7$  years. The mean age of the patients with normal and abnormal follicles was  $24.3 \pm 4.1$  and  $26.2 \pm 2.9$  years, respectively ( $P=0.04$ ).

The EGFR staining was performed for all specimens, and the percentage of stained cells in most normal and abnormal follicles was above 80% (table 1). The EGFR staining percentages in normal and abnormal follicles were not significantly different ( $P=0.73$ ).



**Table 1:** Frequency distribution of EGFR staining percentage, intensity, and overall expression in normal and abnormal follicles

Groups	EGFR staining			EGFR staining intensity				EGFR overall expression		
	51-80%	81-100%	P Value*	Weak	Moderate	Severe	P Value*	Low	High	P Value*
Abnormal Follicle, n (%)	5 (16.7%)	25 (83.3%)	0.73	8 (26.7%)	11 (36.7%)	11 (36.7%)	0.63	3 (10.0%)	27 (90.0%)	0.68
Normal Follicle, n (%)	6 (20.0%)	24 (80.0%)		5 (16.7%)	12 (40.0%)	13 (43.3%)		4 (13.3%)	26 (86.7%)	
Total, n (%)	11 (18.3%)	49 (81.7%)		13 (21.7%)	23 (38.3%)	24 (40.0%)		7 (11.7%)	53 (88.3%)	

\*Chi square test; P<0.05 was considered statistically significant.

**Table 2:** Frequency distribution of HER2 staining intensity in normal and abnormal follicles

Groups	HER2 staining intensity			Total	P value*
	Weak	Moderate	Severe		
Abnormal Follicle, n (%)	8 (26.7%)	18 (60.0%)	4 (13.3%)	30 (100%)	0.95
Normal Follicle, n (%)	7 (23.3%)	19 (63.3%)	4 (13.3%)	30 (100.0%)	
Total, n (%)	15 (25.0%)	37 (61.7%)	8 (13.3%)	60 (100.0%)	

\*Chi square test; P<0.05 was considered statistically significant.

Table 1 presents the distribution of EGFR staining intensity in normal and abnormal follicles. Moreover, the comparison of EGFR staining intensity in normal and abnormal follicles revealed no significant difference (P=0.63).

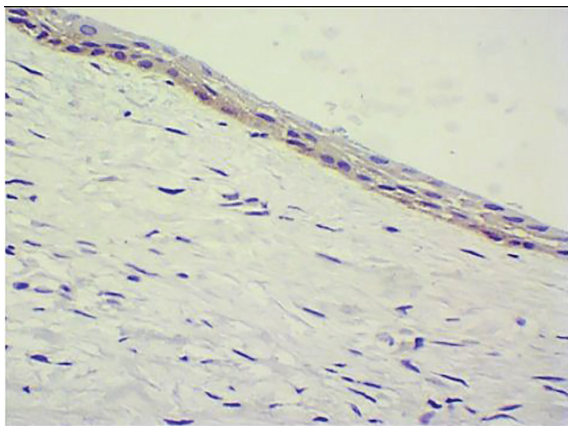
The overall expression of EGFR was high in 86.7% of normal follicles and 90% of abnormal follicles (table 1). However, this difference was not statistically significant (P=0.68).

The percentage of the cells stained for HER2 was above 80% in all normal and abnormal follicles. As indicated in table 2, most normal and abnormal follicles had a moderate intensity of staining. The HER2 staining intensity in normal and abnormal follicles was not significantly different (P=0.95).

HER2 overall expression was high in all normal and abnormal follicles. Figures 2 and 3 show the EGFR and HER2 staining of abnormal and normal follicular cells.

## Discussion

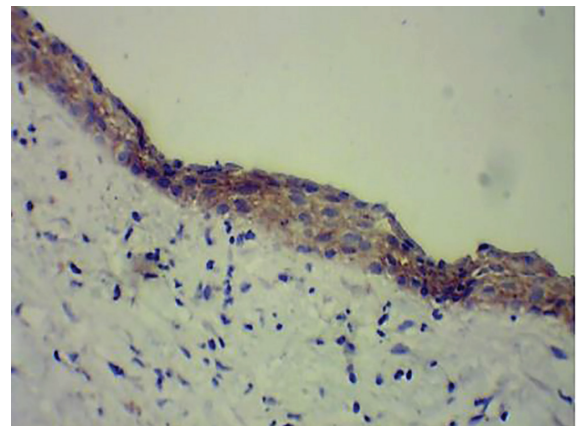
The EGFR and HER2 overall expression was



**Figure 2:** Histopathologic feature shows EGFR staining of abnormal follicle cells ( $\times 400$ ).

high in both normal and abnormal follicles. The percentage of stained cells and intensity of EGFR and HER2 staining in normal and abnormal follicles indicated no significant difference. In the present research, 100% of dental follicles were stained with EGFR, which was consistent with the findings of other previous studies.<sup>11-13, 15</sup> However, in a study by Cimadon and colleagues, EGFR expression was observed in only 86% of the 42 follicles surrounding the impacted teeth.<sup>16</sup> In the present study, the percentage of EGFR staining in all follicular cells of impacted wisdom teeth under the study was above 50%. However, in the study by Oikawa and colleagues, more than 50% of cells were stained in 54% of specimens.<sup>13</sup> The intensity of EGFR staining in the present study was generally strong in 36.7% of cases. However, while in the study by Mohan and Angadi, 70% of cases had severe EGFR staining intensity. Moreover, staining intensity was (++) in 80% of cases in the study by Oikawa and colleagues.<sup>13, 15</sup>

Instead of examining the percentage and intensity of EGFR staining, some studies



**Figure 3:** Histopathologic feature shows HER2 staining of normal follicle cells ( $\times 400$ ).

assessed only the location of EGFR staining in cells in three forms: membrane-only, cytoplasm-only, and combined membrane and cytoplasmic staining. In all of these studies, the most prevalent form of staining was a combination of membrane and cytoplasmic.<sup>11, 12, 16</sup> In line with the study conducted by Oikawa and colleagues,<sup>13</sup> in the present research, the staining of the dental follicle epithelial cells surrounding the impacted teeth was combined membrane and cytoplasmic in all cases. When cells exhibit membrane-only staining, they appear to alter more quickly in the presence of ligands in the bloodstream. On the other hand, when cells display cytoplasm-only or combined membrane and cytoplasmic staining, all or some of the receptors are internalized and display a slower and physiological response.<sup>11</sup>

On the other hand, some studies evaluated separately the EGFR expression in the reduced enamel epithelium (REE) and the remnants of odontogenic epithelium in the impacted tooth follicle. In terms of EGFR staining, some of these studies found no significant differences between these two components of the dental follicle.<sup>15, 17</sup> Nonetheless, Cimadon and colleagues suggested that the epithelial islands and cords indicated higher positivity for EGFR (71.07%) than REE (28.93%).<sup>16</sup> In the present study, out of a total of 60 dental follicles, only five specimens contained epithelial islands. Their staining was similar to the follicle's surface epithelium or REE.

The present study compared the expression of EGFR in follicles <2.5 mm (as normal follicles) and ≥2.5 mm (as abnormal follicles). In contrast to the results of the study by Razavi and colleagues,<sup>6</sup> the present study found no significant difference between them. This difference can be attributed to variations in sample size, type, and time of sample fixation, as well as type of marker, such as retrieval, monoclonality, or polyclonality, and marker dilution.<sup>11</sup> This variation could also be attributed to the staining assessment criteria. Razavi and colleagues utilized membrane-only, cytoplasm-only, and combined membrane and cytoplasmic stainings.<sup>6</sup> While, in the present research, staining was combined membrane and cytoplasmic in all specimens and was evaluated as the percentage of stained cells and intensity of staining.

In the present study, HER2 staining was observed in all normal and abnormal follicles. The percentage of all impacted dental follicle cells with positive HER2 staining exceeded 80%. Likewise, Oikawa and colleagues found HER2 expression in all 10 impacted mandibular wisdom teeth.<sup>13</sup> In the present study, HER2 staining intensity was strong in 13% of cases and moderate to weak in 87% of cases. Whereas, Oikawa and colleagues

found that staining intensity was weak in 100% of cases.<sup>13</sup> This discrepancy in the intensity and proportion of HER2 staining in the dental follicle can be attributed to the differences in the type of marker (monoclonality and polyclonality) utilized in the studies.

Numerous studies examined the histopathological changes in radiographically normal follicles surrounding the impacted teeth and indicated that these follicles had the potential to differentiate into different tissues and cause cysts and tumors.<sup>18, 19</sup> In the same context, Razavi and colleagues found no correlation between radiographic size of third molar's follicles and staining with ki-67 antigen.<sup>20</sup> Furthermore, Cabbar and colleagues reported Ki-67 expression in 59 follicles (with <2.5 mm radiographic width) surrounding impacted third molars. Besides, Ki-67 expression in dental follicles was significantly higher than normal oral epithelium. This finding indicated the ability of active proliferation in the odontogenic epithelia of the dental follicles, and prophylactic removal of impacted wisdom teeth was recommended.<sup>21</sup> Finally, it is suggested that future studies evaluate other immunohistochemical markers using new molecular techniques to express markers.

Therefore, although there are advanced modalities such as cone beam computed tomography (CBCT) to better evaluate the size of the dental follicle, considering that the majority of the studied patients did not have CBCT, and performing CBCT for the patients had additional cost and radiation dose, in this study, panoramic radiographs were used, which was a limitation of the present study.

## Conclusion

According to the findings of this study, follicles with a size of <2.5 and ≥2.5 mm indicated no significant difference in EGFR and HER2 expression. Furthermore, the high expression of EGFR and HER2 in dental follicles indicated that the dental follicle epithelium had a high growth potential. Therefore, since the radiographic size of dental follicles might not indicate the potential capabilities of their cells, it is recommended that further research be done in this area.

## Acknowledgment

This article was written based on the dataset from a DDS thesis of Mehrdad Shahraki registered with the reference number 1865 (IR.ZAUMS.REC.1395.037) and a research grant with reference number 7438 in Zahedan University of Medical Sciences.

### Authors' Contribution

S.S; H.N.R; M.Sh and H.K: Study concept and design, Acquisition of data, Data analysis, and interpretation, Drafting of the manuscript, Critical revision of the manuscript for scientific and factual content. All authors have read and approved the final manuscript and agree to be accountable for all aspects of the work in ensuring that questions related to the accuracy or integrity of any part of the work are appropriately investigated and resolved.

**Conflict of Interest:** None declared.

### References

- Lima RL, Holanda-Afonso RC, Moura-Neto V, Bolognese AM, DosSantos MF, Souza MM. Human dental follicle cells express embryonic, mesenchymal and neural stem cells markers. *Arch Oral Biol.* 2017;73:121-8. doi: 10.1016/j.archoralbio.2016.10.003. PubMed PMID: 27764680.
- Gamal h, Hammuda A, Mohammed S. Detection of Stem Cells in Dental Follicle and Benign Odontogenic Lesions by Immunohistochemical Expression of CD44 and c Myc. *Egyptian Dental Journal.* 2021;67:2133-42. doi: 10.21608/edj.2021.70335.1570.
- Zhang J, Ding H, Liu X, Sheng Y, Liu X, Jiang C. Dental Follicle Stem Cells: Tissue Engineering and Immunomodulation. *Stem Cells Dev.* 2019;28:986-94. doi: 10.1089/scd.2019.0012. PubMed PMID: 30968740.
- Haidry N, Singh M, Mamatha NS, Shivhare P, Girish HC, Ranganatha N, et al. Histopathological Evaluation of Dental Follicle Associated with Radiographically Normal Impacted Mandibular Third Molars. *Ann Maxillofac Surg.* 2018;8:259-64. doi: 10.4103/ams.ams\_215\_18. PubMed PMID: 30693242; PubMed Central PMCID: PMC6327824.
- Dongol A, Sagtani A, Jaisani MR, Singh A, Shrestha A, Pradhan A, et al. Dentigerous Cystic Changes in the Follicles Associated with Radiographically Normal Impacted Mandibular Third Molars. *Int J Dent.* 2018;2018:2645878. doi: 10.1155/2018/2645878. PubMed PMID: 29755527; PubMed Central PMCID: PMC65884152.
- Razavi SM, Siadat S, Mehdizadeh M, Movahedian B, Hasheminia D. Immunohistochemical study of correlation between histologic changes and radiologic features in pericoronal tissues of impacted wisdom teeth. *J Isfahan Dent Sch.* 2012;8:162-71. Persian.
- Bhuyan L, Nishat R, Behura SS, Mahapatra N, Kumar H. Insight into the molecular pathogenesis of odontogenic lesions. *J Oral Biosci.* 2021;63:35-44. doi: 10.1016/j.job.2020.12.001. PubMed PMID: 33476705.
- Fasano M, Della Corte CM, Viscardi G, Di Liello R, Paragliola F, Sparano F, et al. Head and neck cancer: the role of anti-EGFR agents in the era of immunotherapy. *Ther Adv Med Oncol.* 2021;13:1758835920949418. doi: 10.1177/1758835920949418. PubMed PMID: 33767760; PubMed Central PMCID: PMC67953226.
- Oprita A, Baloi SC, Staicu GA, Alexandru O, Tache DE, Danoiu S, et al. Updated Insights on EGFR Signaling Pathways in Glioma. *Int J Mol Sci.* 2021;22. doi: 10.3390/ijms22020587. PubMed PMID: 33435537; PubMed Central PMCID: PMC67827907.
- Lakshminarayana S, Rao RS, Sowmya SV, Augustine D, Patil S, Haragannavar VC. Immunohistochemical analysis of erbb2 in odontogenic lesions: a pilot study. *World J Dent.* 2021;12:70-3. doi: 10.5005/jp-journals-10015-1796.
- da Silva Baumgart C, da Silva Lauxen I, Filho MS, de Quadros OF. Epidermal growth factor receptor distribution in pericoronal follicles: relationship with the origin of odontogenic cysts and tumors. *Oral Surg Oral Med Oral Pathol Oral Radiol Endod.* 2007;103:240-5. doi: 10.1016/j.tripleo.2005.11.009. PubMed PMID: 17234542.
- de Oliveira MG, Lauxen Ida S, Chaves AC, Rados PV, Sant'Ana Filho M. Odontogenic epithelium: immunolabeling of Ki-67, EGFR and survivin in pericoronal follicles, dentigerous cysts and keratocystic odontogenic tumors. *Head Neck Pathol.* 2011;5:1-7. doi: 10.1007/s12105-010-0216-0. PubMed PMID: 21053110; PubMed Central PMCID: PMC3037468.
- Oikawa M, Miki Y, Shimizu Y, Kumamoto H. Assessment of protein expression and gene status of human epidermal growth factor receptor (HER) family molecules in ameloblastomas. *J Oral Pathol Med.* 2013;42:424-34. doi: 10.1111/jop.12024. PubMed PMID: 23278525.
- Yang HK, Chen H, Mao F, Xiao QG, Xie RF, Lei T. Downregulation of LRIG2 expression inhibits angiogenesis of glioma via EGFR/VEGF-A pathway. *Oncol Lett.* 2017;14:4021-8. doi: 10.3892/ol.2017.6671. PubMed PMID: 28943909; PubMed Central PMCID: PMC65605965.
- Mohan BC, Angadi PV. Quantitative and qualitative analysis of epidermal growth

- factor receptor expression in pericoronal follicles in predicting proliferative potential. *Acta Odontol Scand.* 2014;72:770-5. doi: 10.3109/00016357.2014.906649. PubMed PMID: 24844785.
- 16 Cimadon N, Lauxen IS, Carrard VC, Sant'Ana Filho M, Rados PV, Oliveira MG. Analysis of the proliferative potential of odontogenic epithelial cells of pericoronal follicles. *J Contemp Dent Pract.* 2014;15:761-5. doi: 10.5005/jp-journals-10024-1613. PubMed PMID: 25825104.
- 17 Kömerik N, Tufan A, Kapucuoglu N. Comparison of Proliferative Activity of Epithelial Cells between the Follicles of Impacted Teeth. *International Journal of Morphology.* 2014;32:1296-302. doi: 10.4067/S0717-95022014000400028.
- 18 Saravana GH, Subhashraj K. Cystic changes in dental follicle associated with radiographically normal impacted mandibular third molar. *Br J Oral Maxillofac Surg.* 2008;46:552-3. doi: 10.1016/j.bjoms.2008.02.008. PubMed PMID: 18406023.
- 19 Satheesan E, Tamgadge S, Tamgadge A, Bhalerao S, Periera T. Histopathological and Radiographic Analysis of Dental Follicle of Impacted Teeth Using Modified Gallego's Stain. *J Clin Diagn Res.* 2016;10:ZC106-11. doi: 10.7860/JCDR/2016/16707.7838. PubMed PMID: 27437341; PubMed Central PMCID: PMC4948517.
- 20 Razavi SM, Hasheminia D, Mehdizade M, Movahedian B, Keshani F. The relation of pericoronal third molar follicle dimension and bcl-2/ki-67 expression: An immunohistochemical study. *Dent Res J (Isfahan).* 2012;9:S26-31. doi: 10.4103/1735-3327.107931. PubMed PMID: 23814558; PubMed Central PMCID: PMC3692196.
- 21 Cabbar F, Guler N, Comunoglu N, Sencift K, Cologlu S. Determination of potential cellular proliferation in the odontogenic epithelia of the dental follicle of the asymptomatic impacted third molars. *J Oral Maxillofac Surg.* 2008;66:2004-11. doi: 10.1016/j.joms.2008.06.011. PubMed PMID: 18848095.