

Rosmarinic Acid Protects the Testes of Rats against Cell Phone and Ultra-high Frequency Waves Induced Toxicity

Jafar Fatahi Asl¹, PhD; Mehdi Goudarzi², PhD; Esrafil Mansouri³, PhD; Hamed Shoghi⁴, PhD

¹Department of Radiologic Technology, Faculty of Paramedicine, Ahvaz Jundishapur University of Medical Sciences, Ahvaz, Iran;

²Medicinal Plant Research Center, Ahvaz Jundishapur University of Medical Sciences, Ahvaz, Iran;

³Cellular and Molecular Research Center, Department of Anatomical Sciences, Faculty of Medicine, Ahvaz Jundishapur University of Medical Sciences, Ahvaz, Iran;

⁴Department of Physiology, Pharmacology and Medical Physics, Faculty of Medicine, Qom University of Medical Sciences, Qom, Iran

Correspondence:

Hamed Shoghi, PhD;
Room 309, Department of Physiology,
Pharmacology and Medical Physics,
Faculty of Medicine, Qom University of
Medical Sciences, Postal code: 37361-
75513, Qom, Iran

Tel: +98 25 31971146

Email: h_shoghi2004@yahoo.com

Received: 15 January 2023

Revised: 15 March 2023

Accepted: 22 April 2023

What's Known

- Cell phone and Ultra-High Frequency (UHF) waves cause oxidative stress, contributing to the generation of Reactive Oxygen Species (ROS), which results in aging and dysfunctions, such as multiple sclerosis, Parkinson's, and Alzheimer's diseases.
- Rosmarinic Acid (RA), as a polyphenol, has anti-inflammatory, antitumor, and anti-hepatitis characteristics.

What's New

- RA as an anti-oxidant could save the testes and diminish the induction of ROS by increasing antioxidant enzymes and decreasing the lipid peroxidation and oxidative stress indicators in rats.
- RA as a food supplement can be useful for protecting humans exposed to cell phones and UHF environmental contamination.

Abstract

Background: Cell phone and Ultra-High Frequency (UHF) waves produce oxidative stress and cause testicular toxicity. This investigation was directed to evaluate the effectiveness of Rosmarinic Acid (RA) against oxidative stress caused by UHF radiation in rats.

Methods: Forty-two male Wistar rats were divided into six groups. The control received 5 mL normal saline (0.9% NaCl) by gavage, the cell phone group received 915 MHz, the UHF waves group just received 2450 MHz, the RA/cell phone group received RA plus 915 MHz, RA/UHF waves group received RA plus 2450 MHz, and RA just received RA (20 mg/kg). After 30 days of consecutive radiation, the biochemical and histopathological parameters of their testes were measured. Statistical comparison was made using one-way ANOVA followed by Tukey's *post hoc* test.

Results: Cell phone and UHF wave radiation significantly diminished the activity of antioxidant enzymes such as superoxide dismutase, catalase, and glutathione peroxidase, and glutathione content ($P < 0.001$). On the opposite, UHF significantly increased oxidative stress indices including malondialdehyde level, nitric oxide level, and protein carbonyl content ($P < 0.001$). UHF also significantly reduced the number of Sertoli cells, spermatogonia, primary spermatocyte, epithelial height, and seminiferous tubular and luminal diameters ($P < 0.001$). RA, as an effective antioxidant, reverses the above-mentioned harms and moderates the adverse effects of UHF on the testes of rats by significantly diminishing the oxidative stress indices and antioxidant enzyme rise and improving the histological parameters ($P < 0.001$).

Conclusion: RA can protect the testes of rats from UHF-induced toxicity by reducing oxidative stress. RA as a food supplement might be useful for protecting humans exposed to UHF environmental contamination.

Please cite this article as: Fatahi Asl J, Goudarzi M, Mansouri E, Shoghi H. Rosmarinic Acid Protects the Testes of Rats against Cell Phone and Ultra-high Frequency Waves Induced Toxicity. Iran J Med Sci. doi: 10.30476/ijms.2023.97695.2952.

Keywords • Rosmarinic acid • Testes, Oxidative stress • UHF waves, cell phone

Introduction

Because of the incessant evolution of new technologies, many people are exposed to various frequencies of electromagnetic fields and wireless devices such as cell phones and Ultra-High Frequency (UHF) waves at home or work. Wireless devices

irradiated UHF, and the memory of animal and human models was influenced by it. Free radical and oxidative stress were produced, which have a decisive role in modulating redox responses *in vitro/in vivo* and assist in the production of reactive oxygen species (ROS), the principal delinquent in the degeneration of neurons. Moreover, oxidative stress can regulate the biochemical alterations leading to elderly and dysfunctions such as Parkinson's, Alzheimer's, multiple sclerosis, and amyotrophic lateral sclerosis.¹

Antioxidants can be both endogenous and exogenous and may prevent complications caused by high-frequency electromagnetic radiation by performing mechanisms such as suppressing oxidative stress via neutralizing ROS and free radicals.² Several endogenous antioxidants can moderate the harmful effects of radiation, including Superoxide Dismutase (SOD), Glutathione (GSH), Glutathione Peroxidase (GPx), Malondialdehyde (MDA), Nitric Oxide (NO), Protein Carbonyl (PC), and Total Antioxidant Capacity (TAC). Sometimes first-line defense antioxidants such as SOD, CAT, GSH, and GPx cannot alone protect the body from damage caused by ROS-induced oxidative stress. Therefore, natural antioxidants as exogenous molecules, can diminish free radicals.³ Rosmarinic Acid (RA), as a polyphenol, has anti-inflammation, anti-hepatitis, and antitumor characteristics. RA is found in rosemary, lemon balm, savory, peppermint, oregano, thyme, and sage.

RA has been identified as a strong antioxidant in some studies, besides its anti-inflammatory and anti-tumor effects.⁴ The principal goal of this project was to evaluate the radio-protective effects of RA on oxidative stress by measuring the changes in TAC level, GSH content, and the activities of antioxidant enzymes, such as SOD, CAT, and GPx, and the values of stress oxidative indicators such as MDA, NO level, and PC content in the testes of Wistar rats in the presence of 915 and 2450 MHz radiofrequency radiations.

Materials and Methods

Chemicals

RA, Bovine Serum Albumin (BSA),

Phosphate Buffer Saline (PBS), GSH, 2,4-dinitrophenylhydrazine (DNPH), tri-2-pyridyl-s-triazine (TPTZ), trichloroacetic acid (TCA), N-(1-naphthyl) ethylenediamine dihydrochloride (NEDD), 1,1,3,3-tetraethoxypropane (TEP), 5, 5-dithiobis (2-nitrobenzoic acid) (DTNB), thiobarbituric acid (TBA), and the Bradford reagent were bought from Sigma Chemicals (St. Louis, Mo., USA).

Animals

A total of 42 male adult Wistar rats from the animal laboratory of Baqiyatallah University with weights between 200 and 250 g were prepared (seven per cage) and fed in the form of water and granules. Temperature (22 ± 1 °C), humidity (35 to 60%), and light (12 h light/dark cycle) were set. Rats were randomly divided into six groups (table 1). Radiation groups were irradiated 60 min/day for 30 consecutive days.⁵ In this study, the dose of RA was chosen similar to other publications that have worked in this field.⁶ The code of ethics assigned to this project by Ahvaz Jundishapur University of Medical Science (AJUMS) is IR.AJUMS.ABHC.REC.1397.013. The time of administration of Normal Saline (NS) or RA was one hour before the rats were exposed to radiation.

UHF-producing System

The incident electromagnetic field from the Gigahertz Transversal Electromagnetic Mode (GTEM) cell was uniform over the entire biological object. The power density was 0.98 mW/cm² for 915 MHz and 0.79 mW/cm² for 2450 MHz in this project.

Sample Collection

One day after the last treatment, rats intraperitoneally were anesthetized with ketamine (80 mg/Kg) and xylazine (8 mg/Kg) combination.⁷ First, the testicles of the rats were separated and washed with NS, and then the rats were cut off. To perform the tissue identification analysis, the left testis tissues were fixed in Bouin's solution and then embedded in paraffin. To perform biochemical evaluations, the right testis was used. An ice-cold Tris-HCl buffer with a concentration of 0.1

Table 1: Classification of the studied groups

Groups	Treatment
Control	5 mL/Kg normal saline daily by gavage
Cell phone	915 MHz (60 min/day) for 30 days
UHF waves	2450 MHz (60 min/day) for 30 days
RA/Cell phone	RA (20 mg/Kg, p.o.) plus 915 MHz (60 min/day) for 30 days
RA/UHF waves	RA (20 mg/Kg, p.o.) plus 2450 MHz (60 min/day) for 30 days
RA	RA (20 mg/Kg, p.o.) for 30 days

M (pH 4.7) was used to homogenize the testes (1/10 w/v) using the German device (WiseTis HG-150D, PMI-Labortechnik GmbH Company).⁸ Bradford's method was used to measure protein homogenates and crystalline BSA.⁹

GSH Assay

As previously described, the GSH content was measured.¹⁰ The homogenate and 100 μ L of TCA (25%) were combined as well as 0.1 mL of the supernatant with 2 mL of DTNB. At the wavelength of 412 nm, the comparison was made between the standard curve and its absorbance. To express the obtained results, nmol/mg protein was reported.

Activity of the Antioxidant Enzymes

To determine SOD, CAT, and GPx activities (units/mg protein), a commercial kit from Zell Bio GmbH (Germany) was used.

MDA Assay

A composite material (0.5 mL of tissue homogenate plus 2.5 mL of 10% (w/v) TCA) was made, and the mixture was centrifuged for 10 min at 1000 g. Afterward, 2 mL of each supernatant sample was mixed with 1 mL of TBA solution (0.67%, w/v). Keeping the sample in boiling water for 30 min and cooling it at room temperature, led to the pink color of the solution. A spectrometer (Shimadzu UV-VIS 160A, Japan) was used to measure the absorbance of the sample at 532 nm. A standard curve was used to determine the tissue level of MDA (nmol/mg protein).¹¹

NO Assay

To determine the level of NO in the testicles, the Griess reaction was used, which included the measurement of its nitro-nitrite products.¹² To deproteinize the homogenates, 40 μ L of zinc sulfate (30% (w/v)) was mixed with 800 μ L of the desired sample, and after 10 min of incubation, it was centrifuged (1000 \times g, 10 min).

To measure the nitrate, 2.5 g of cadmium granules were added to the tubes, and then the tubes were incubated for 2 hours at room temperature. Then, 50 μ L of Griess reagent (equal volumes of sulfanilamide 2% in H₃PO₄ 5% and 0.2% NEDD in deionized water) was combined with 50 μ L supernatant, and the mixture was incubated for 10 min at room temperature. A spectrometer was used to measure absorption at a wavelength of 540 nm.

PC Assay

Homogenate (0.5 mL) plus an equivalent volume of 0.1% DNPH (w/v) in 2 N hydrogen

chloride were incubated at room temperature for one hour. TCA 20% was added to the output, and the supernatant was removed after centrifugation. Ethyl acetate-ethanol (1:1 volume; 0.5 mL) was used to wash the pellets and then resuspended in 1000 μ L of Tris buffer as well as guanidinium chloride (8.0 M). The dissolved hydrazones were analyzed at a wavelength of 370 nm, and the concentration of protein carbonyl derivatized with 2-4-DNPH was determined using the extinction coefficient of 22000 M⁻¹cm⁻¹. It was used to express the obtained carbonyl values in nanomoles per milligram of protein.¹³

TAC Assay

A cheap colorimetric way for TAC assay was the Ferric-Reducing Antioxidant Power (FRAP) method. 50 μ L of the supernatant was blended with 1.5 mL of fresh FRAP reagent (25 mL of 0.3 M sodium acetate buffer, pH 3.6; 2.5 mL of 0.01 M TPTZ in 0.04 M HCl; 2.5 mL of 0.02 M FeCl₃·6H₂O). Then, it was incubated for five min at a temperature of 37 °C, and the absorbance was assessed at 593 nm.

Protein Determination

The protein of rat testis was determined by the Bradford method using bovine serum albumin as a standard solution.

Histopathological Studies

Testes were fixed in paraffin and cut into pieces. The pieces were stained with hematoxylin and eosin (H&E). Finally, 12 seminiferous tubule parts of stage VII-VIII for each rat were evaluated under a light microscope. With the use of Motic software, tubule diameter (from the basal lamina to the basal lamina of the other side), epithelial height, and ductal diameter were analyzed.

Statistical Analysis

Data were shown as mean \pm SD, and statistical analyses were done by version 8 of GraphPad Prism software. The Kolmogorov-Smirnov test showed that the data distribution was normal. Statistical evaluation was done by one-way ANOVA along with Tukey's *post hoc* test. A P<0.05 was considered significant.

Results

Reaction of RA on Antioxidant Enzymes and GSH

The GSH and the activity of CAT, SOD, and GPx were decreased notably in the cell phone and UHF waves groups compared to the control (P<0.001). RA remarkably raised the GSH

content in RA/cell phone and RA/UHF waves compared to the cell phone and UHF waves groups, respectively ($P<0.001$).

RA remarkably raised the GPx in RA/cell phone and RA/UHF waves compared to the cell phone and UHF waves groups ($P<0.001$ and $P=0.03$). Treatment with RA notably elevated the SOD activity in RA/cell phone and RA/UHF waves groups compared to the cell phone and UHF waves groups ($P<0.001$ and $P=0.02$). RA notably increased the CAT activity in RA/UHF waves compared to the UHF waves group ($P=0.01$). Furthermore, RA alone did not change the amount of GSH and the function of CAT, SOD, and GPx compared with the control (figures 1 and 2).

Reaction of RA on MDA and NO

Despite significant increases in MDA and NO ($P<0.001$) in rats' testes exposed to cell phone and UHF waves compared to the control, the RA/cell phone and RA/UHF waves groups showed significant decreases in MDA and NO when compared to the cell phone and UHF waves ($P=0.01$ and $P=0.02$). The levels of MDA

and NO were not changed by treatment with RA alone compared to the control. Moreover, the MDA level in the UHF waves was increased compared to the cell phone ($P=0.02$) (figure 3).

Reaction of RA on TAC and PC

PC was remarkably raised and TAC was notably diminished in the cell phone and UHF waves groups compared to the controls ($P<0.001$). RA notably decreased PC in RA/cell phone and RA/UHF waves compared to the cell phone and UHF waves groups ($P<0.001$). RA administration notably reversed the TAC level. The administration of RA alone to intact rats did not alter TAC and PC compared to the control group. Besides, there was a further PC increase in the UHF waves compared to the cell phone group ($P=0.02$) (figure 4).

Reaction of RA on the Light Microscopic Detections

The histological examination of the testicular tissue indicated that the epithelial structure of the seminiferous tubules in the RA and control groups was normal. A decrease in germinal

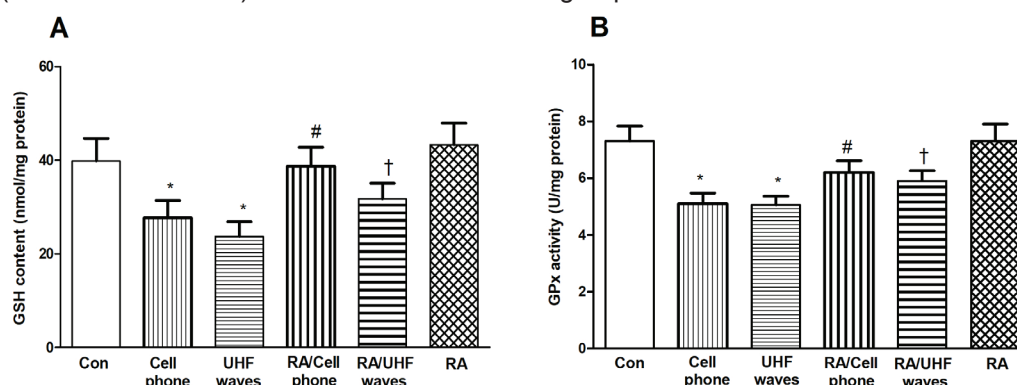


Figure 1: Result of RA on GSH and GPx in rats' testes facing UHF. UHF notably diminished GSH and GPx compared to the control group, and RA treatment significantly reversed the above event. (* $P<0.05$) indicates a significant difference in comparison with the control. (# $P<0.05$) reveals a significant difference compared to the cell phone. († $P<0.05$) reveals a significant difference versus UHF waves. RA: Rosmarinic acid; UHF: Ultra-high frequency

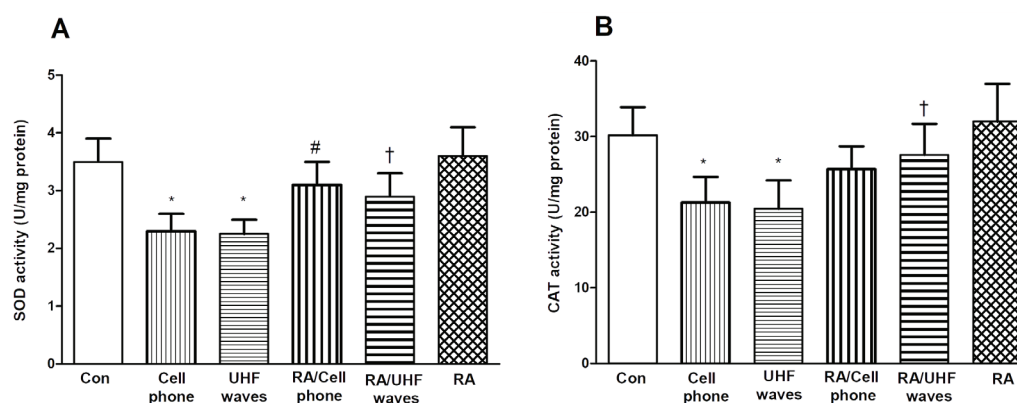


Figure 2: Result of RA on SOD and CAT in rats' testes faced to UHF. UHF notably reduced SOD and CAT compared to the controls, and RA treatment significantly reversed the above event. (* $P<0.05$) indicates a significant difference compared to the controls. (# $P<0.05$) reveals a significant difference compared to the cell phone group. († $P<0.05$) reveals a significant difference compared to the UHF waves group. RA: Rosmarinic acid; UHF: Ultra-high frequency

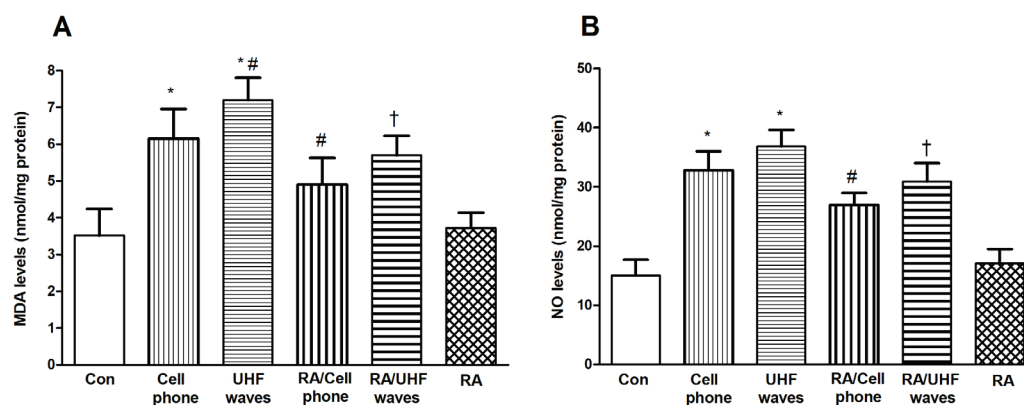


Figure 3: Levels of MDA and NO affected by RA are evident in the testes of rats exposed to UHF. UHF remarkably increased MDA and NO compared to the controls, and RA treatment significantly reversed the above event. RA: Rosmarinic acid. UHF: Ultra-high frequency, (* $P<0.05$) showed a significant difference compared to the control. (# $P<0.05$) displays a significant difference from the cell phone. († $P<0.05$) showed a significant difference compared to UHF waves.

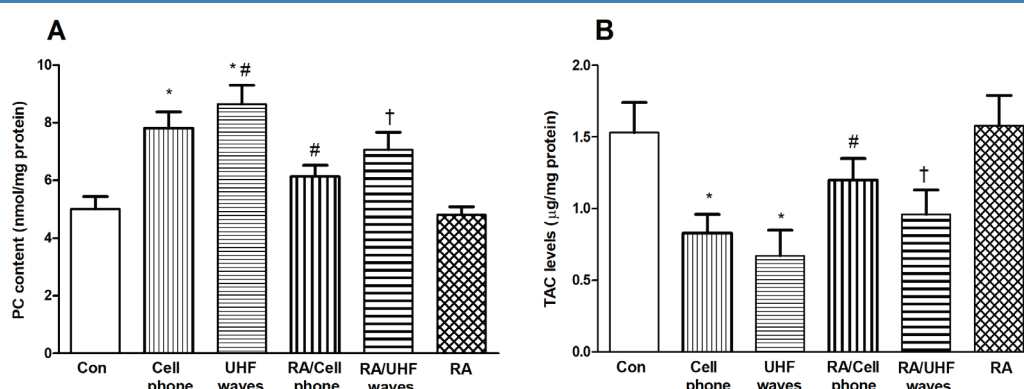


Figure 4: The reaction of RA on PC and TAC in rats' testes faced to UHF. UHF notably raised PC and diminished TAC compared to the controls. RA treatment basically reversed the above event. RA: Rosmarinic acid. UHF: Ultra-high frequency, (* $P<0.05$) indicates a significant difference compared to controls. (# $P<0.05$) shows a significant difference versus the cell phone. († $P<0.05$) indicates a significant difference compared to UHF waves.

epithelial cells, including primary spermatocytes, spermatogonia, and Sertoli cells ($P<0.001$), and disorder in the positioning of the epithelium, were revealed in the cell phone and UHF in the seminiferous tubules compared to the control. Moreover, the epithelial height and the diameter of the duct and spermatogenic tubules in the cell phone and UHF diminished notably compared to the control ($P<0.001$).

The epithelium was eradicated, and the empty space between the cells was shown (black arrow) (figure 5). The epithelium in some tubules is separated from its main position and moves into the lumen of the spermatogenic tubules (white arrow). More desolation was observed in the UHF wave compared to the cell phone in the tissue images. In fact, the sperm tubules lost their regular shapes, the number of epithelial cells decreased drastically, and spaces between the germinal epithelial cells (black arrow) and epithelium fall into the lumen (white arrow) were indicated. Treatment with RA remarkably improved seminiferous tubular diameter ($P<0.001$), seminiferous luminal

diameter ($P<0.001$), seminiferous epithelial height ($P<0.001$), number of spermatogonia ($P<0.001$), and primary spermatocyte ($P=0.03$) in the RA/cell phone and RA/UHF waves groups compared to the cell phone and UHF waves groups. In the RA/UHF group, histological images indicated that the form of the tubules was distinctly arranged, and the epithelium was largely returned to normal, but the number of epithelial cells was qualitatively diminished, and the intraepithelial spaces were evident in some places (black arrow).

Moreover, administration of RA alone to normal rats did not significantly change these indices in the testes of the control (figure 5). The evaluation data of the number of germinal epithelium cells, the diameter of the tube, as well as the height of the epithelium, are summed up in table 2.

Discussion

Chronic exposure of rats' testes to cell phone and UHF waves caused a notable diminishing

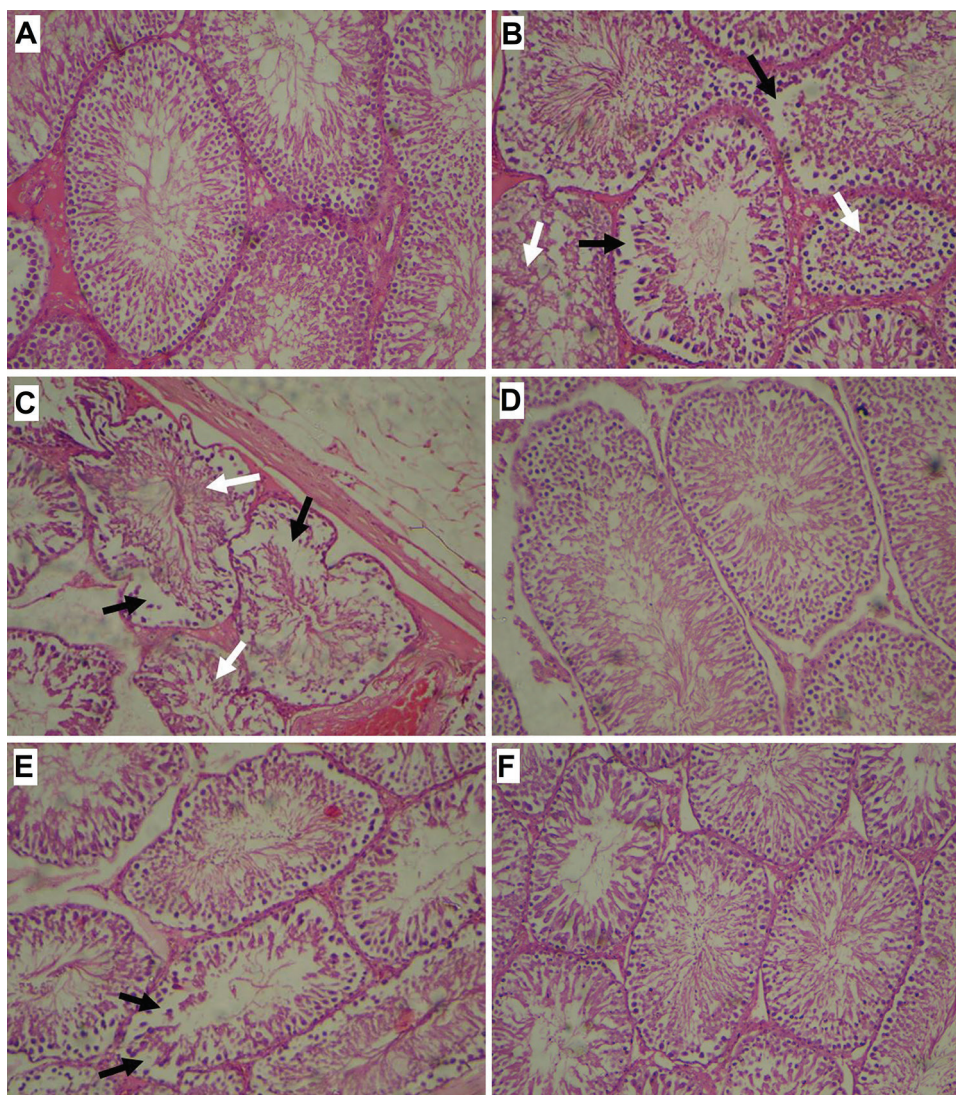


Figure 5: The reaction of rosmarinic acid on light microscopic detections in the testes of rats was shown in confronting with Ultra High Frequency. Groups include: A: Control, B: Cell phone, C: Ultra-high frequency waves, D: Rosmarinic acid/ cell phone, E: Rosmarinic acid /ultra-high frequency waves, and F: Rosmarinic acid (magnification $\times 400$). In the cell phone group, the microscopic images showed deformities in seminiferous tubules epithelium, that way epithelium was destroyed, and an empty space was shown between cells (black arrow). In some tubules, the epithelium was separated from its original location and entered the lumen of seminiferous tubules (white arrow). In the ultra-high frequency group, the tissue images showed more destruction relative to the cell phone-exposed group. As can be seen, the seminiferous tubules underwent structural changes and lost their structural order and regular shape, the number of epithelial cells sharply decreased, and spaces between the germinal epithelial cells (black arrow) and epithelium fall into the lumen (white arrow) were observed. In the rosmarinic acid/ ultra-high frequency group, tissue images show that the shape of the tubules was clearly regularized and the epithelium went largely back to normal, but the epithelium cell count remained qualitatively reduced, and the spaces between the epithelium are obvious in some places (black arrow).

in GSH, GPx, CAT, and SOD compared to the control. Previous studies showed GPx, CAT, and SOD as antioxidants were reduced after facing mice to 2.45 GHz microwave radiation,¹⁴ and GSH was significantly decreased following UHF.¹⁵ Salah and colleagues showed that SOD was significantly reduced following exposure to UHF.¹⁵ Ozguner and others indicated that GPx, SOD, and CAT activities were decreased with 30 min/day rats exposure to cell phones for 90 consecutive days.¹⁶ It was shown that GPx and SOD levels were decreased by chronic electromagnetic field exposure.¹⁷ Amara and

colleagues reported a decrease in the GPx, CAT, and SOD levels of testis after exposure to UHF.¹⁸

RA treatment, as an exogenous antioxidant, reversed the side effects of UHF in this study, which is consistent with previous studies. Zhang and others showed that GPx, SOD, and CAT activity were increased after RA administration in the liver and kidney of rats.¹⁹ Fernando and colleagues showed that RA increased SOD and CAT activities by scavenging intracellular ROS induced by UVB.²⁰

Our results showed that UHF radiation

Table 2: Results of histopathological examination

Variable	Control	Cell phone	P value vs. control	UHF waves	P value vs. control	RA/cell phone	P value vs. cell phone	RA/UHF waves	P value vs. UHF waves	RA	P value vs. control
Seminiferous tubular diameter (μm)	334 \pm 18	224 \pm 14*	<0.001	210 \pm 11*	0.001	262 \pm 16#	<0.001	231 \pm 19	0.07	340 \pm 22	0.1
Seminiferous luminal diameter (μm)	83 \pm 5	61 \pm 4*	<0.001	53 \pm 3*	<0.001	72 \pm 6#	<0.001	62 \pm 4†	0.02	86 \pm 7	0.2
Seminiferous epithelial height (μm)	135 \pm 12	81 \pm 7*	<0.001	76 \pm 5*	<0.001	103 \pm 9#	<0.001	98 \pm 8†	<0.001	138 \pm 13	0.1
No. of spermatogonia / tubule	53 \pm 5	27 \pm 3*	<0.001	23 \pm 2*	<0.001	39 \pm 4#	<0.001	36 \pm 4†	<0.001	51 \pm 6	0.3
No. of primary spermatocyte / tubule	40 \pm 6	20 \pm 3*	<0.001	16 \pm 2*	<0.001	28 \pm 5#	0.03	23 \pm 4	0.08	43 \pm 6	0.2
No. of sertoli cell/tubule	13 \pm 2	6 \pm 1*	<0.001	5 \pm 1*	<0.001	9 \pm 2	0.06	8 \pm 2	0.1	14 \pm 3	0.4

The evaluation data of the number of germinal epithelium cells, the diameter of the tube, as well as the height of the epithelium, were summed up. Statistical evaluation was done by one-way ANOVA along with Tukey's *post hoc* test. A $P < 0.05$ was significant. Values are means \pm SD, (n=7). * $P < 0.05$ indicates a significant difference in comparison with the control group. # $P < 0.05$ indicates a significant difference compared with the cell phone group. † $P < 0.05$ indicates a significant difference in comparison with the ultra-high frequency group. RA: Rosmarinic acid; UHF: Ultra-high frequency.

caused the enhancement of oxidative stress indices including NO and MDA levels in the testes of rats, consistent with previous research. Additionally, 945 MHz radiation (power density, 3.67 W/m²) enhanced the MDA level in the blood sample of rats.²¹ Salah and colleagues revealed that 2.45 GHz radiation, 1 hour per day, for 21 consecutive days increased the MDA level in the liver and kidney of rats.¹⁵ Amara and others reported an enhancement in the MDA levels of testis after exposure to UHF.¹⁸ On the opposite side, RA treatment of mice caused a reduction of MDA levels in the liver and kidney.¹⁹ RA protects dopaminergic neurons by inhibiting NO production.²² Moreover, the administration of 5 mg RA per day for each rat as a compensator decreased the MDA level after exposure to a 50 Hz electromagnetic field (EMF).²³ Our results authenticated these studies that NO and MDA in rats' testes were significantly decreased in RA/cell phone and RA/UHF waves groups in comparison with cell phone and UHF waves groups, respectively.

Under normal conditions, testes have a high TAC level due to their enzymatic and/or non-enzymatic antioxidant capacity.²⁴ Thus, by decreasing the amount of TAC level in the testes of male rats infertility occurred.²⁵ We showed that TAC was decreased basically in the testes of rats in confronting with cell phone and UHF radiations, and RA could compensate for this complication by increasing the amount of TAC level. Notably, MDA level and PC contents in the NS/UHF waves group were more increased

than the NS/cell phone group. This means that UHF radiation is likely to be more powerful and therefore more harmful than cell phone radiation.

Our results showed that UHF causes dysfunction of the testis, which leads to impaired spermatogenic activity. Additionally, UHF decreased the number of cells of the spermatogenic lineage, the height of germinal epithelium, spermatogonia, primary spermatocytes, and Sertoli cells in male rats confronted with cell phone radiation and UHF waves for 30 days. These results are consistent with prior data that UHF radiation caused a decrease in testis weight and serious testicular emaciation with a decline of germ cells in seminiferous tubules. The tubules were condensed and mainly evacuated from germ cells.²⁶ Moreover, it was shown that microwave radiation caused a decrease in the diameters of seminiferous tubule²⁷ and sperm count and destruction in spermatogenesis.²⁸ It has been shown that UHF decreases the size of the testicular organs and the diameter of the seminiferous tubules.²⁹ A significant protective effect of RA on tissue structures of germinal epithelium, seminiferous tubules, and ductal part of tubules was observed by histopathological results.

Improving the diameter of the spermatogenic tubes may cause an elevation in the action of spermatogenesis. Khaki and others showed that low-frequency magnetic fields had negative effects on testicular histology, and these harmful effects of radiation were less in the groups

that received RA.³⁰ Raisi and colleagues also showed that RA improved sperm parameters, increased antioxidant activity, and reduced histopathological damage.³¹ In diabetic rats, RA could treat the complication by preventing lipid peroxidation, showing that RA could inhibit damage oxidative and balance cholinergic neurotransmission in the diabetic state.⁶ RA as an exogenous natural antioxidant could protect the tissue damage induced by free radicals by improving the proceedings of endogenous antioxidant enzymes and also scavenging the superoxide radicals in the testes of rats. The formation of ROS is followed by the rise of lipid peroxidation. It has been shown that the MDA was significantly lower in RA-treated groups and controls, which means lipid peroxidation can be suppressed by RA via the scavenging free radicals mechanism in rats.³² Because of the incorporation of conjugated structures in the polyphenol frameworks, especially the dihydroxyphenol or catechol structure, as well as the presence of a carboxylic group, RA could prevent hydroxyl radicals.³³ Besides, it was shown that in aqueous media, conjugation of a carboxylic acid group with two catechol construction caused enhancement of the antioxidant activity of RA.³⁴ Moreover, it was shown that the antioxidant activity of RA is principal because of redox properties, which have a major responsibility in deactivating free radicals, quelling singlet and triplet oxygen, or disintegrating peroxides.³⁵

Attah and colleagues declared through a literature review in 2022 that exposure to high radiofrequency radiation (RFR) (≥ 2.45 GHz) could result in numerous health impairments. They indicated that oxidative stress and cellular damage were induced by high RFR in Wistar rats compared to unexposed groups. In this review study, no reports indicated non-harmful effects of high radiofrequency radiation on the health of rats.³⁶ On the other hand, there has been no evidence that rosemary acid has no effect on oxidative stress parameters and antioxidant enzymes. On the contrary, Nadeem and others reported the therapeutic potential of rosemary acid on a wide range of diseases in a comprehensive review.³⁷

In this project, one of our limitations was not investigating the pathways of inflammation and apoptosis. Besides, one of the reasons for not evaluating other signaling pathways was financial issues.

Conclusion

UHF may destroy the morphological and

operational properties of testes. Male infertility might be caused by exposure of rats to UHF waves and cell phone radiation via decreasing testicular antioxidant enzymes as well as increasing testicular oxidative stress indices. It was found that RA as an antioxidant could save the testes and diminish the induction of ROS by increasing antioxidant enzymes and decreasing lipid peroxidation and oxidative stress indicators. Because of the notable protective effect of RA, it can be considered a promising cure to compensate for the harmful effect of UHF on the testes of rats and improve the histological parameters.

It seems that the measurement of inflammatory factors and cell death pathways, including apoptosis, can be useful to explain the mechanism of the effect of RA on the testes of rats against cell phones and UHF waves.

Acknowledgment

This work was supported by the grant number (MPRC-9708) provided by the Deputy of Research of Ahvaz Jundishapur University of Medical Sciences, Ahvaz, Iran.

Authors' Contribution

J.F.A, M.G, A.M, and H.Sh: Conception and design; performing the experiments, analysis, and interpretation of data for the work, drafting and reviewing. All authors have read and approved the final manuscript and agree to be accountable for all aspects of the work in ensuring that questions related to the accuracy or integrity of any part of the work are appropriately investigated and resolved.

Conflict of Interest: None declared.

References

- 1 Uttara B, Singh AV, Zamboni P, Mahajan RT. Oxidative stress and neurodegenerative diseases: a review of upstream and downstream antioxidant therapeutic options. *Curr Neuropharmacol*. 2009;7:65-74. doi: 10.2174/157015909787602823. PubMed PMID: 19721819; PubMed Central PMCID: PMC2724665.
- 2 Richer S, Stiles W, Zargar P, Rezaei M, Vo T, Bone R, et al. The human lens: A living biometric indicator of health status and successful aging. *Studies on the Cornea and Lens*. 2015:155-86. doi: 10.1007/978-1-4939-1935-2_10.
- 3 Carocho M, Ferreira IC. A review on

- antioxidants, prooxidants and related controversy: natural and synthetic compounds, screening and analysis methodologies and future perspectives. *Food Chem Toxicol.* 2013;51:15-25. doi: 10.1016/j.fct.2012.09.021. PubMed PMID: 23017782.
- 4 Chung CH, Jung W, Keum H, Kim TW, Jon S. Nanoparticles Derived from the Natural Antioxidant Rosmarinic Acid Ameliorate Acute Inflammatory Bowel Disease. *ACS Nano.* 2020;14:6887-96. doi: 10.1021/acsnano.0c01018. PubMed PMID: 32449857.
- 5 Naziroglu M, Celik O, Ozgul C, Cig B, Dogan S, Bal R, et al. Melatonin modulates wireless (2.45 GHz)-induced oxidative injury through TRPM2 and voltage gated Ca(2+) channels in brain and dorsal root ganglion in rat. *Physiol Behav.* 2012;105:683-92. doi: 10.1016/j.physbeh.2011.10.005. PubMed PMID: 22019785.
- 6 Mushtaq N, Schmatz R, Pereira LB, Ahmad M, Stefanello N, Vieira JM, et al. Rosmarinic acid prevents lipid peroxidation and increase in acetylcholinesterase activity in brain of streptozotocin-induced diabetic rats. *Cell Biochem Funct.* 2014;32:287-93. doi: 10.1002/cbf.3014. PubMed PMID: 24301255.
- 7 Haybar H, Goudarzi M, Mehrzadi S, Aminzadeh A, Khodayar MJ, Kalantar M, et al. Effect of gemfibrozil on cardiotoxicity induced by doxorubicin in male experimental rats. *Biomed Pharmacother.* 2019;109:530-5. doi: 10.1016/j.biopha.2018.10.101. PubMed PMID: 30551518.
- 8 Mehrabani M, Goudarzi M, Mehrzadi S, Siahpoosh A, Mohammadi M, Khalili H, et al. Crocin: a protective natural antioxidant against pulmonary fibrosis induced by bleomycin. *Pharmacol Rep.* 2020;72:992-1001. doi: 10.1007/s43440-019-00023-y. PubMed PMID: 31997260.
- 9 Bradford MM. A rapid and sensitive method for the quantitation of microgram quantities of protein utilizing the principle of protein-dye binding. *Anal Biochem.* 1976;72:248-54. doi: 10.1006/abio.1976.9999. PubMed PMID: 942051.
- 10 Nesari A, Mansouri MT, Khodayar MJ, Rezaei M. Preadministration of high-dose alpha-tocopherol improved memory impairment and mitochondrial dysfunction induced by proteasome inhibition in rat hippocampus. *Nutr Neurosci.* 2021;24:119-29. doi: 10.1080/1028415X.2019.1601888. PubMed PMID: 31084475.
- 11 Goudarzi M, Kalantar M, Kalantar H. The hepatoprotective effect of gallic acid on mercuric chloride-induced liver damage in rats. *Jundishapur Journal of Natural Pharmaceutical Products.* 2017;12. doi: 10.5812/jjnpp.12345.
- 12 Mehrzadi S, Mehrabani M, Malayeri AR, Bakhshayesh M, Kalantari H, Goudarzi M. Ellagic acid as a potential antioxidant, alleviates methotrexate-induced hepatotoxicity in male rats. *Acta Chir Belg.* 2019;119:69-77. doi: 10.1080/00015458.2018.1455419. PubMed PMID: 29587597.
- 13 Goudarzi M, Amiri S, Nesari A, Hosseinzadeh A, Mansouri E, Mehrzadi S. The possible neuroprotective effect of ellagic acid on sodium arsenate-induced neurotoxicity in rats. *Life Sci.* 2018;198:38-45. doi: 10.1016/j.lfs.2018.02.022. PubMed PMID: 29455002.
- 14 Shahin S, Singh VP, Shukla RK, Dhawan A, Gangwar RK, Singh SP, et al. 2.45 GHz microwave irradiation-induced oxidative stress affects implantation or pregnancy in mice, *Mus musculus*. *Appl Biochem Biotechnol.* 2013;169:1727-51. doi: 10.1007/s12010-012-0079-9. PubMed PMID: 23334843.
- 15 Salah MB, Abdelmelek H, Abderraba M. Effects of olive leave extract on metabolic disorders and oxidative stress induced by 2.45 GHz WIFI signals. *Environ Toxicol Pharmacol.* 2013;36:826-34. doi: 10.1016/j.etap.2013.07.013. PubMed PMID: 23994945.
- 16 Ozguner F, Armagan A, Koyu A, Caliskan S, Koylu H. A novel antioxidant agent caffeic acid phenethyl ester prevents shock wave-induced renal tubular oxidative stress. *Urol Res.* 2005;33:239-43. doi: 10.1007/s00240-005-0470-x. PubMed PMID: 15877224.
- 17 Oksay T, Naziroglu M, Dogan S, Guzel A, Gumral N, Kosar PA. Protective effects of melatonin against oxidative injury in rat testis induced by wireless (2.45 GHz) devices. *Andrologia.* 2014;46:65-72. doi: 10.1111/and.12044. PubMed PMID: 23145464.
- 18 Amara S, Abdelmelek H, Garrel C, Guiraud P, Douki T, Ravanat JL, et al. Effects of subchronic exposure to static magnetic field on testicular function in rats. *Arch Med Res.* 2006;37:947-52. doi: 10.1016/j.arcmed.2006.06.004. PubMed PMID: 17045109.
- 19 Zhang Y, Chen X, Yang L, Zu Y, Lu Q. Effects of rosmarinic acid on liver and kidney antioxidant enzymes, lipid peroxidation and tissue ultrastructure in aging mice. *Food Funct.* 2015;6:927-31. doi: 10.1039/c4fo01051e. PubMed PMID: 25635678.
- 20 Fernando PM, Piao MJ, Kang KA, Ryu YS, Hewage SR, Chae SW, et al. Rosmarinic Acid

- Attenuates Cell Damage against UVB Radiation-Induced Oxidative Stress via Enhancing Antioxidant Effects in Human HaCaT Cells. *Biomol Ther (Seoul)*. 2016;24:75-84. doi: 10.4062/biomolther.2015.069. PubMed PMID: 26759705; PubMed Central PMCID: PMC4703356.
- 21 Yurekli AI, Ozkan M, Kalkan T, Saybasili H, Tuncel H, Atukeren P, et al. GSM base station electromagnetic radiation and oxidative stress in rats. *Electromagn Biol Med*. 2006;25:177-88. doi: 10.1080/15368370600875042. PubMed PMID: 16954120.
- 22 Park JA, Kim S, Lee SY, Kim CS, Kim DK, Kim SJ, et al. Beneficial effects of carnosic acid on dieldrin-induced dopaminergic neuronal cell death. *Neuroreport*. 2008;19:1301-4. doi: 10.1097/WNR.0b013e32830abc1f. PubMed PMID: 18695511.
- 23 Hajhosseini L, Khaki A, Merat E, Ainehchi N. Effect of rosmarinic acid on sertoli cells apoptosis and serum antioxidant levels in rats after exposure to electromagnetic fields. *Afr J Tradit Complement Altern Med*. 2013;10:477-80. doi: 10.4314/ajtcam.v10i6.14. PubMed PMID: 24311872; PubMed Central PMCID: PMC47387.
- 24 Aitken RJ, Roman SD. Antioxidant systems and oxidative stress in the testes. *Adv Exp Med Biol*. 2008;636:154-71. doi: 10.1007/978-0-387-09597-4_9. PubMed PMID: 19856167.
- 25 Pahune PP, Choudhari AR, Muley PA. The total antioxidant power of semen and its correlation with the fertility potential of human male subjects. *J Clin Diagn Res*. 2013;7:991-5. doi: 10.7860/JCDR/2013/4974.3040. PubMed PMID: 23905087; PubMed Central PMCID: PMC47387.
- 26 Samarth RM, Samarth M. Protection against radiation-induced testicular damage in Swiss albino mice by *Mentha piperita* (Linn.). *Basic Clin Pharmacol Toxicol*. 2009;104:329-34. doi: 10.1111/j.1742-7843.2009.00384.x. PubMed PMID: 19320637.
- 27 Kesari KK, Behari J. Effects of microwave at 2.45 GHz radiations on reproductive system of male rats. *Toxicological and Environ Chemistry*. 2010;92:1135-47. doi: 10.1080/02772240903233637.
- 28 Saygin M, Caliskan S, Karahan N, Koyu A, Gumral N, Uguz A. Testicular apoptosis and histopathological changes induced by a 2.45 GHz electromagnetic field. *Toxicol Ind Health*. 2011;27:455-63. doi: 10.1177/0748233710389851. PubMed PMID: 21310776.
- 29 Salama N, Kishimoto T, Kanayama HO. Effects of exposure to a mobile phone on testicular function and structure in adult rabbit. *Int J Androl*. 2010;33:88-94. doi: 10.1111/j.1365-2605.2008.00940.x. PubMed PMID: 19076254.
- 30 Khaki A, Imani S, Golzar FS. Effects of rosmarinic acid on male sex hormones (testosterone-FSH-LH) and testis tissue apoptosis after exposure to electromagnetic field (EMF) in rats. *African Journal of Pharmacy and Pharmacology*. 2012;6:248-52. doi: 10.5897/AJPP11.701.
- 31 Raisi A, Davoodi F, Mohammadi R. Protective effects of rosmarinic acid on testicular torsion-detorsion in an animal model. *Iranian Journal of Veterinary Surgery*. 2022;17:80-6.
- 32 Alagawany M, Abd El-Hack ME, Farag MR, Gopi M, Karthik K, Malik YS, et al. Rosmarinic acid: modes of action, medicinal values and health benefits. *Anim Health Res Rev*. 2017;18:167-76. doi: 10.1017/S1466252317000081. PubMed PMID: 29110743.
- 33 Soobrattee MA, Neergheen VS, Luximon-Ramma A, Aruoma OI, Bahorun T. Phenolics as potential antioxidant therapeutic agents: mechanism and actions. *Mutat Res*. 2005;579:200-13. doi: 10.1016/j.mrfmmm.2005.03.023. PubMed PMID: 16126236.
- 34 Del Bano MJ, Castillo J, Benavente-Garcia O, Lorente J, Martin-Gil R, Acevedo C, et al. Radioprotective-antimutagenic effects of rosemary phenolics against chromosomal damage induced in human lymphocytes by gamma-rays. *J Agric Food Chem*. 2006;54:2064-8. doi: 10.1021/jf0581574. PubMed PMID: 16536576.
- 35 Renzulli C, Galvano F, Pierdomenico L, Speroni E, Guerra MC. Effects of rosmarinic acid against aflatoxin B1 and ochratoxin-A-induced cell damage in a human hepatoma cell line (Hep G2). *J Appl Toxicol*. 2004;24:289-96. doi: 10.1002/jat.982. PubMed PMID: 15300717.
- 36 Attah TA, Ayantunji B, Adamu A, Omede A, Leleji J, Hussiani S, et al. Biological Effects of High Radiofrequency Radiation on Wistar Rats: A Literature Review. *Journal of Public Health International*. 2022;5:1-31. doi: 10.14302/issn.2641-4538.jphi-22-4197.
- 37 Nadeem M, Imran M, Aslam Gondal T, Imran A, Shahbaz M, Muhammad Amir R, et al. Therapeutic potential of rosmarinic acid: A comprehensive review. *Applied Sciences*. 2019;9:3139. doi: 10.3390/app9153139.