

# Unusual Presentation of Iliac Bone Hydatid Cyst

F. Omid Kashani, Z. Hagi, M. Mazloumi

## Abstract

A 21-year-old woman presented with a painless growing mass in her right flank since 5 months before. With the probable diagnosis of a cold abscess, the patient was operated, but the wound was not cured. The patient was re-examined and a biopsy from the lesion was taken which revealed hydatid cyst. After nearly complete excision of the infected area and adjuvant chemotherapy with albendazole for 6 weeks, no recurrence was seen until 14 months after the operation.

**Iran J Med Sci 2007; 32(2): 121-123.**

**Keywords** • Hydatid cyst • pelvic bone • drainage

## Introduction

**E**chinococcosis (hydatid cyst) is an infection caused by the larva of the tapeworms of the genus *Echinococcus*.<sup>1</sup> It is transmitted by the ingestion of eggs and commonly involves the liver (80%) and lung (15%) although any part of the body may be affected.<sup>2</sup> A primary hydatid cyst of the bone is rare, and usually misdiagnosed. Herein, we described a case of primary iliac bone hydatid cyst presenting with a draining sinus in the right flank.

## Case Presentation

A 21-year-old woman from the Northeast of Iran, presented with a painless swelling over her right flank, which had progressively increased in size over five months. There was no associated fever, loss of appetite, or history of tuberculosis. Local examination showed a cystic, non-tender swelling of almost 10-cm in diameter in the right flank area. No swelling or mass could be felt in the abdomen; there was no spinal tenderness or deformity. Physical examination of the right hip joint revealed limited internal rotation without any pain.

The clinical diagnosis was the collection of the liquid (most probably a psoas abscess). Other possibilities were a chronic hematoma, a benign tumor, or tuberculosis (regarding the residence place of the patient).

Abdominal sonography revealed a large (10.1×8.6 cm) hypoechoic mass with echogenic septation in the right flank. Liver, spleen, both kidneys, and the urinary bladder appeared normal. Moderate amount of effusion was detected in the right hip joint. Routine laboratory tests were normal.

The patient was operated in a local hospital for abscess incision and drainage through Petit triangle by a general surgeon. After local irrigation and debridement, one suction drain was used as a hemovac. Two days later, the drain was removed. After a few days, from the site of drain removal, a yellowish discharge was appeared. The sample of the liquid sent to the laboratory could not be diagnostic and its culture was sterile. The patient was discharged with oral antibiotics and

Department of Orthopedic Surgery,  
Mashhad University of Medical Sciences,  
Mashhad, Iran.

### Correspondence:

Farzad Omid Kashani MD,  
Department of Orthopedic Surgery,  
Ghaem Hospital,  
Mashhad University of Medical Sciences,  
Mashhad, Iran.

**Tel:** +98 511 8400000

**Fax:** +98 511 8409612

**Email:** [omidif@mums.ac.ir](mailto:omidif@mums.ac.ir)

anti-inflammatory drugs, but fluid drainage persisted and the patient referred to our hospital for further evaluation.

In our hospital, the patient was examined carefully again. She had no hepatosplenomegaly and her only positive findings were right flank tenderness and limited internal rotation of the right hip joint. On plain radiography of the pelvis, multiple cystic lesions were present throughout the right iliac bone (fig 1). Chest x ray was normal. Barium enema for ruling out of Crohn disease or ulcerative colitis was done, but revealed no positive findings. Then, fistulography was done (fig 2a) which revealed a large cystic lesion in almost all of the right iliac bone.

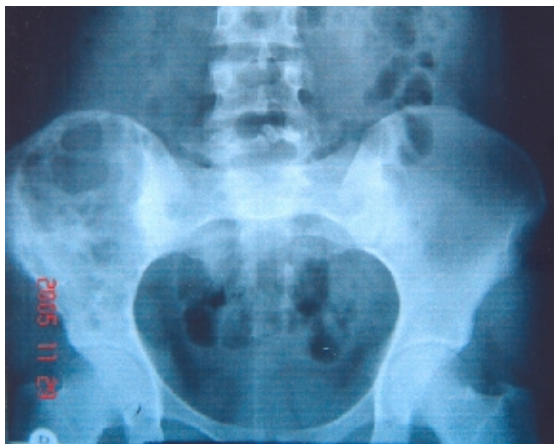

Fig1: Multiple cystic lesions in the right ilium.

Computed tomography of the pelvis showed multiple erosive lesions in the right iliac bone in addition to soft tissue swelling in gluteal muscles (especially *gluteus medius*) and suggested osteomyelitis or malignancy

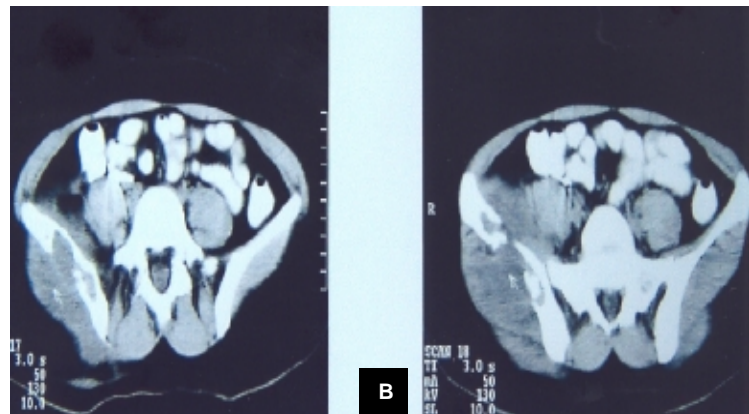
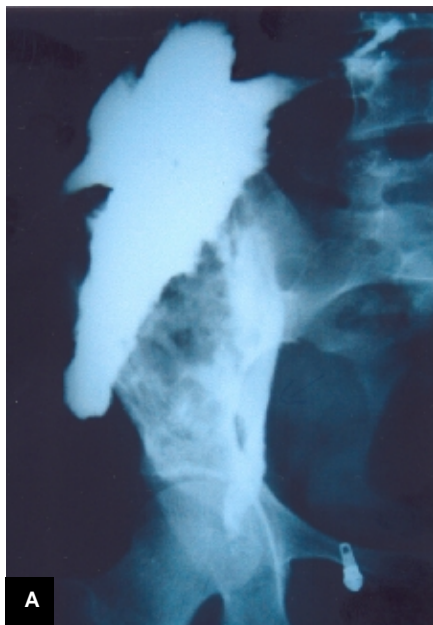


Fig 2: a) Extension of the lesion in fistulography b) Computed tomography showing ruptured cyst in the right iliac bone.

(fig 2b). Bone scanning with  $^{99m}\text{Te}$ , revealed increased perfusion, blood pool and bone uptake in the right iliac bone. No other abnormal uptake was detected throughout the skeleton. Laboratory tests indicated white blood cell count of  $11,900 \text{ cells/mm}^3$  (with 70% polymorphonuclear cells), erythrocyte sedimentation rate of 120 mm after the first hour and 3<sup>+</sup> C-reactive protein. The Casoni and indirect hemagglutination tests were negative.

The patient was operated on to rule out malignant bone tumor, chronic osteomyelitis, or other bone cysts like aneurismal bone cyst, simple bone cyst or a neglected hydatid cyst. The biopsy result showed laminated bone associated with granulation tissue, lymphomononuclear infiltrations and lamellar and kitinic wall of hydatid cyst.

The patient was operated again and all of the fistular tract and infected bone were excised. Fortunately, as the infected area was in the wing of the ilium, we could excise it almost completely. After the operation, medical treatment with albendazole began and continued for six weeks. After 14 months of follow-up, the patient was well and recurrence was not occurred.

## Discussion

Man is an accidental host in the life cycle of *Echinococcus granulosus*. Human infestation occurs when the ova are swallowed. The outer protective coat of the ovum is digested in the stomach and the liberated larvae penetrate the mucosa of the proximal bowel to enter the portal system and to spread to various organs. Cysts are found in the liver (55%–60%), lungs (30%), kidneys (2.5%), heart (2.5%), bones

(2%, mostly in spinal column), muscles (1%), brain (0.5%) and in other organs (1.5%).<sup>3</sup>

In man, infection is usually acquired in childhood. The symptoms present several years after exposure and it may take five to 20 years before a diagnosis is made. Of 532 cases of echinococcosis reviewed in Lebanon, 12 were of pelvic hydatid disease.<sup>4</sup> Sometimes, primary pelvic hydatid cyst may present with abdominal symptoms related to compression of the rectum and urinary tract.<sup>5</sup> In some cases, primary pelvic hydatid cyst causes sciatica and foot drop.<sup>1,6</sup> Our patient, though, with a draining sinus in her flank region, was unique.

It is of the utmost importance that a correct preoperative diagnosis is made, since all precautions must be taken to prevent dissemination and seeding of the surgical field. Deaths have been reported due to anaphylactic shock resulted from spillage during excision or biopsy after a mistaken diagnosis of a retroperitoneal tumor.<sup>7</sup> So in endemic regions, because of the diversity of its presentation, hydatid disease should always be in the differential diagnosis list of any growing mass in the body. Diagnostic techniques such as radiography, ultrasonography, computed tomography, magnetic resonance imaging and immunologic tests are of value.<sup>8</sup> Complete surgical excision is the treatment of choice for osseous hydatid disease. Isolated medical therapy with mebendazole or albendazole is not adequate for controlling the process, but as we did, can be added to surgery when complete excision of the cyst is not possible or doubtful.<sup>9</sup>

## References

- 1 Gupta A, Kakkar A, Chadha M, Sathave CB. A Primary intrapelvic hydatid cyst presenting with foot drop and a gluteal swelling: a case report. *J Bone Joint Surg Br* 1998; 80: 1037-9.
- 2 Terek MC, Ayan C, Ulukus M, et al. Primary pelvic hydatid cyst. *Arch Gynecol Obstet* 2000; 264: 93-6.
- 3 Loudiye H, Aktaou S, Hassikou H, et al. Hydatid disease of bone. Review of 11 cases. *Joint Bone Spine* 2003; 70: 352-5.
- 4 Martínez AA, Herrera A, Cuenca J, Herrero L. Hydatidosis of the pelvis and hip. *Int Orthop* 2001; 25: 302-4.
- 5 Bounaim A, Sakit F, Janati IM. Primary pelvic hydatid cyst: a case report. *Med Trop (Mars)* 2006; 66: 279-81.
- 6 Hasan FO, Shannak A. Primary pelvic hydatid cyst: an unusual cause of sciatica and foot drop. *Spine* 2001; 26: 230-2.
- 7 Kantarci M, Onbas O, Alper F, et al. Anaphylaxis due to a rupture of hydatid cyst: imaging findings of a 10-year-old boy. *Emerg Radiol* 2003; 10: 49-50.
- 8 Grzeszczuk A, Tarasow E, Kubas B, et al. New imaging diagnostics of liver echinococcosis. *Wiad Parazytol* 2001; 47: 565-72.
- 9 Szypryt EP, Morris DL, Mulholland RC. Combined chemotherapy and surgery for hydatid bone disease. *J Bone Joint Surg Br* 1987; 69: 141-4.