

AUTOGENOUS OSTEOCHONDRAL TRANSPLANTATION MOSAICPLASTY (AN ANIMAL STUDY ON SHEEP)

F.M Jaberi, F. Dehghani,* N. Tanideh,** S. Torabinezhad ****

Department of Orthopedic Surgery, **Animal Laboratory, and *Department of Pathology,
Shiraz University of Medical Sciences, Shiraz*

ABSTRACT

Background: Autogenous osteochondral grafting of articular defect in weight-bearing surface of large joints has proven to be a proper biomechanical and physiological solution for localized full-thickness defects.

Objective: To study the gross and histopathological results of mosaicplasty in an animal model (sheep's medial femoral condyle), evaluating the factors of defect and graft size, assessing the effect of fixation with only cancellous bone impaction between graft columns, and early free post-operative motion.

Methods: Fourteen medium sized sheep were the subject of the study. Cylindrical osteochondral grafts of 4 mm and 6 mm diameter and 1 cm length from the periphery of the medial femoral condyles at the patellofemoral joint were used to fill corresponding 8 mm and 15 mm diameter cylindrical defects of 1 cm depth at the weight-bearing surface of medial femoral condyles. The spaces between the grafts were packed with cancellous bone with double gloved thumb. The sheep were free for activities and weight bearing after the operation. Two of the 14 sheep died. The first due to sepsis and the other of cardiorespiratory arrest during anesthesia induction. All sheep were sacrificed after 4 months and their knees collected as specimens for further gross and histopathological studies.

Results: All grafted defects except one healed with smooth cartilage. The quality of cartilage was evaluated by histopathological criteria, rating the cellular morphology, surface regularity as well as structural integrity and thickness of cartilage, binding to adjacent normal cartilage and clustering. Twenty-three out of 24 specimen showed excellent or good result, that is a success rate of 95.8%.

Conclusion: Mosaicplasty, autogenous osteochondral grafting in this animal study was effective and successful even in larger defects of 15 mm diameter. Cancellous bone cementing between the cylindrical grafts, respecting the normal convexity of the femoral condyle insertion of obliquely harvested grafts at the periphery of the defects and freedom of motion and activity were all helpful in obtaining good results 4 months after graft implantation.

Iran J Med Sci 2001; 26(3&4):95-101

Key Words • Osteochondral • cartilage • transplantation

Introduction

Localized articular cartilage defects in weight bearing joints are common yet difficult to treat. The single and greatest limitation of articular cartilage is its inability to heal even

the most minor injury and once destroyed, it is unrepairable. However, if subchondral bone is also damaged, fibrous, fibrocartilage or hyaline cartilage will develop which is biomechanically and biochemically different from normal cartilage. The second and third phases of healing are highly mediated by the vascular system and thus, all the inflammatory and reparative aspects that the vascular system provides are not available to cartilage. The

Correspondence: *F.M. Jaberi, Department of Orthopedic Surgery, Medical School, Shiraz University of Medical Sciences, Shiraz, Iran, Tel: +98711-6246093, E-Mail:fnjaberi@yahoo.com.*

modulating factors influencing the healing response of articular cartilage are the size of the defect, continuous motion and age of the organism. Viscoelastic properties of articular cartilage determine its nutrition and altered biomechanical characters of the repaired tissue affect chondrocyte metabolism leading to lack of matrix support.¹ Shapiro et al., observed lack of integration of collagen fibers of healing cartilage with adjacent normal cartilage leading to vertical shear stress at the boundary, precipitating micromotion and degenerative changes in the form of surface fibrillation and acellular area.¹⁻⁵

To help repair a cartilage defect many methods have been used with varying degrees of success in both animal studies and clinical trials. These include shaving or debridement of damaged articular cartilage, perforation of subchondral bone plate by multiple drilling or abrasion, osteotomies as well as transplantation of osteochondral shell grafts, perichondrium, periosteum, chondrocyte, and mesenchymal stem cells. Synthetic gels and implants, such as carbon fiber pads, biodegradable matrices, and collagen gels have been used individually or as carriers for chondrocytes or growth stimulating factors.^{1,6-20} Mosaicplasty represents a method of autogenous osteochondral transplantation for the treatment of focal cartilaginous defects secondary to biomechanical chondropathy, traumatic chondral lesions and osteochondritis dissecans of the knee and ankle.

Laszlo Hangody and colleagues reported their mosaicplasty technique in the treatment of focal cartilaginous defects in over 100 patients during 3 years with favorable results.¹² They previously reported an experimental investigation of the technique on 8 German Shepherd dogs and confirmed the integration of the implanted osteochondral grafts by histological examination following 16 operations.⁹

Garry Kish, the first American orthopedic surgeon to learn and use the osteochondral grafting technique, performed his first mosaicplasty on a 22-year-old football player with success.¹⁵

In a collaborative study, Hangody, Kish, Karpati et al., reported on a new one-step mosaicplasty technique on 107 patients who had been treated for full-thickness lesions as a result of chondropathy, traumatic chondral defects and osteochondritis dissecans. A modified HSS (Hospital for Special Surgery) knee scoring system, revealed 92% good or excellent results. The size of the defects ranged from one to eight square centimeters. Based on the animal trial conducted in 1992, they stressed the crucial importance of avoiding weight bearing on the joint for 6 to 8 weeks.¹³ In those trials, 8 German Shepherd dogs were treated by mosaicplasty, 8 grafted in weight-bearing areas of the knee and 8 grafted in non-weight-bearing areas. At 4, 8, 16, 26 and 52 weeks; gross, histological and radiological evaluation revealed the establishment of hyaline cartilage, with recipient bonding at non-weight bearing areas and subsidence of the grafts when subjected to early loading at weight bearing areas.⁹

Materials and Methods

At the Animal Laboratory Research Center of Shiraz University of Medical Sciences, 14 healthy medium-weight sheep were the subject of this study. In half of the sheep, under general anesthesia by ether inhalation, medial parapatellar arthrotomy incision was used for exposure of knee joints. Cylindrical osteocartilaginous grafts of 4 mm diameter and 1 cm length were obtained by the mosaicplasty chisel from the non-weight-bearing periphery of the femoral condyle at the patellofemoral joint. A cylindrical defect of 8 mm diameter and 1 cm depth was made by mosaicplasty

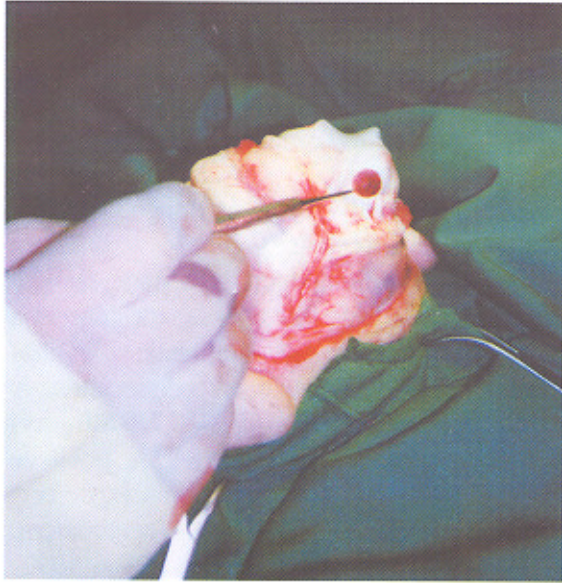


Figure 1: The defect measuring 1 mm in depth.

chisel in the center of the weight-bearing portion of the medial femoral condyle. The defects were filled with the cylindrical osteochondral grafts of 4 mm diameter and 1 cm length. The same procedure was undertaken in the remaining sheep with 6 mm diameter and 1 cm length cylindrical osteochondral grafts filled with a cylindrical osteochondral defect of 15 mm diameter and 1 cm depth (Figs. 1 and 2).

In order to preserve the natural convexity of the normal femoral condyle at the site of the defect after graft placement, we obtained some grafts in an oblique direction. A distance of 5 mm to 6 mm was left between the donor sites in order to avoid fracture and patellofemoral joint damage. We attempted non-impaction therefore packing the grafts in place by the pressure of double gloved thumb. Cancellous bone from the femoral condyle was used as cement between the cylindrical grafts achieving smooth coverage and firm fixation.

The sheep were coded post-operatively and placed in the care of a veterinarian for daily dressings, oral antibiotic and regular physical examination. They had no limitation on

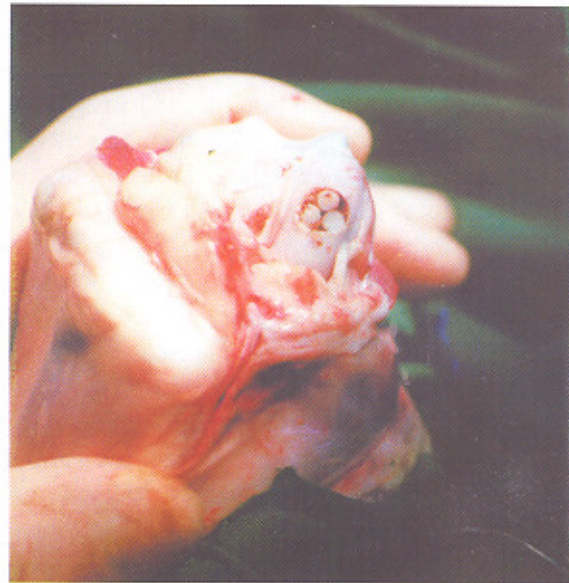

Figure 2: Completed mosaicplasty.

activities and the weight-bearing was as tolerated. They were scored regarding their activities and limping by two colleagues who were blinded to the study. Four months post-operatively, all sheep were sacrificed and 48 specimens collected of the femoral condyles of which 24 intact lateral condyles were controls.

Two sheep expired. The first from an infected wound progressing to sepsis and the second from cardiac arrest after anesthesia induction.

Results

Gross appearance

All grafted defects except one healed with a smooth and normal appearing cartilaginous surface without irregularity or steps at the grafted and normal cartilage boundary. All donor sites were filled with even fibrous tissue. There were 12 left sided medial femoral condyles with a 15 mm diameter defect of 1 cm depth, transplanted with 6 mm diameter cylindrical grafts. The same number of medial femoral condyles of right knees comprising an 8 mm diameter defect of 1 cm

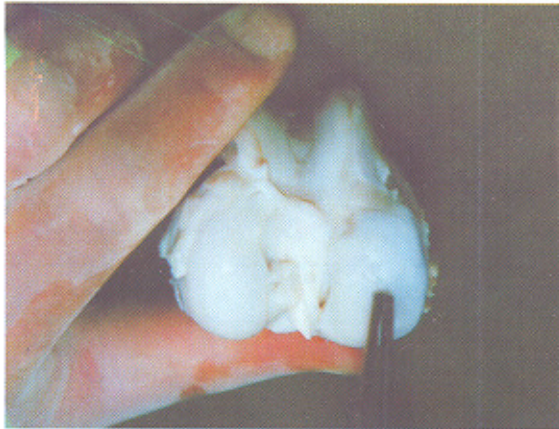


Figure 3: Healed osteochondral graft.

depth were transplanted with 4 mm diameter cylindrical osteochondral grafts (Fig. 3).

Histopathological results

Histopathological results were evaluated by a comprehensive scoring system (Table 1) regarding cellular morphology, surface regularity, structural integrity, thickness of cartilage, bounding to adjacent normal cartilage and clustering. Transplanted cartilage quality was rated into four groups as: excellent (score 7-10), good (score 11-14), fair (score 15-19), and poor (score 20-23). Overall, 60% were excellent and good results and were deemed successful. Twenty-three out of 24 specimens showed excellent or good result, that is a 95.8% success rate. There was one fair and no poor. About 50% with equal distribution in both larger and smaller defect groups scored as good. The 'fair' result was due to septic arthritis, (Table 1). Figure 4 illustrates the histological comparison between grafted and normal cartilage.

Discussion

It is not clear what percentage of patients seek medical advice for osteochondral lesions and the natural course of the lesion has not

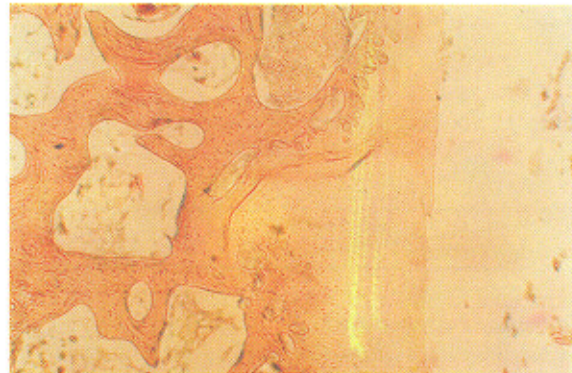


Figure 4: Planted tissue, hyaline cartilage with normal thickness, smooth and regular surface, bound to adjacent cartilage. (H&E X 250)

been well studied. However, it is logical to assume that larger defects in the weight-bearing surfaces are closely associated with eventual disabling osteoarthritis. Surgical procedures available for treatment include debridement, drilling, microfracture, abrasion arthroplasty, autogenous and allogeneous osteochondral graft, periosteal grafting and autogenous chondrocyte transplantation.^{1-3,6,7,20} Methods that rely on fibrocartilage replacement are limited by the inherent altered biomechanics of replacing cartilage with scar cartilage.²⁰ Allografts run the risk of infection and immunological long term changes. Large diameter osteochondral grafting carries the risk of surface incongruity, and if autogenous, donor site morbidity.^{6,7}

Autogenous osteochondral cylinder graft, first obtained from the intercondylar notch, have been used for replacement of articular cartilage defects while reconstructing the anterior cruciate ligament.^{2,4} Recent reports on autogenous chondrocyte transplantation has been promising, in spite of being a two-stage procedure and laboratory dependent.³ Autogenous osteochondral mosaic-like cartilage transfer has been developed for the

Table 1: Scoring system for histopathological evaluation and result

Histopathological evaluation	Sheep's number																										
	S [*] ₁	S ₂ _R	S ₂ _L	S ₃ _R	S ₃ _L	S ₄ _R	S ₄ _L	S ₅ _R	S ₅ _L	S ₆ _R	S ₆ _L	S ₇ _R	S ₇ _L	S ₈ _R	S ₈ _L	S ₉ _R	S ₉ _L	S ₁₀ _R	S ₁₀ _L	S ₁₁	S ₁₂ _R	S ₁₂ _L	S ₁₃ _R	S ₁₃ _L	S ₁₄ _R	S ₁₄ _L	
Cellular morphology 1- Hyaline articular cartilage: score = 1 2- Incompletely differentiated mesenchymal cells: score = 2 3- Fibrous tissue or bone: score = 3	1	3	3	2	1	1	1	1	1	1	1	1	1	1	1	1	1	1	1	1		1	1	1	1	3	1
Surface regularity 1- Intact: score = 1 2- Superior horizontally laminated: score = 2 3- fissure 25-100%thick: score = 3 4- Severe disruption (fibrillated): score = 4	1	3	2	2	1	2	1	1	2	2	3	1	2	2	1	1	2	1	1	1		1	1	1	2	1	2
Structural Integrity 1- Normal: score = 1 2- Severe disruption: score = 2 3- Severe disintegration: score = 3	1	2	1	2	1	1	1	1	1	1	2	1	1	1	1	1	1	1	1	1		1	1	2	1	2	2
Thickness 1- 100% of normal Cartilage: score = 1 2- 50-100% of normal Cartilage: score = 2 3- 0- 50% of normal Cartilage: score = 3	1	3	3	3	1	2	2	1	1	2	2	1	2	2	1	1	1	1	1	1		1	2	2	1	2	2
Bounding to adjacent cartilage 1- Bounded at both ends: score = 1 2- Bounded at one end: score = 2 3- Unbounded: score = 3	1	3	2	1	1	1	1	2	2	2	2	1	3	1	3	2	3	1	1	1		2	2	3	3	1	1
Cellularity 1- Normal cellularity: score = 1 2- Slight Hypocellularity: score = 2 3- Moderate Hypocellularity: score = 3 4- Severe Hypocellularity: score = 4	1	2	2	1	1	2	2	1	1	3	2	1	1	1	1	1	1	1	2	2		2	1	2	2	3	2
Chondrocyte Clustering 1- No cluster: score = 1 2- < 25% of the cells: score = 2 3- 25- 100% of the cells: score = 3	1	1	1	2	2	2	2	3	2	3	2	2	2	2	2	2	1	2	2	2		2	2	3	2	1	2
Total score	7	17	14	13	8	11	10	10	10	14	14	8	12	10	10	8	11	9	9	9		10	10	14	12	13	12
Results	E	F	G	G	E	G	E	E	E	G	G	E	G	E	E	E	G	E	E	E		E	E	G	G	G	G

E= Excellent : 7-10 R= Right Success rate = excellent + good = 95.8%
 G= Good : 11-14 L= Left Fair = 4.1%
 F= Fair : 15-19 S^{*}= Sheeps Poor = 0%
 P= Poor :20-23

treatment of cartilaginous defects of varying sizes from 8 to 19 mm. By keeping the graft small in diameter, 4.5 mm or less, increasing the number of grafts, and implanting in a mosaic fashion, recipient site congruity is maintained.

These grafts are taken from the non-weight-bearing periphery of the femoral side of the patellofemoral joint, and as such, donor site morbidity has been limited. This method has been used for the treatment of focal lesions secondary to biomechanical chondropathy, traumatic chondral defects and osteochondritis dissecans of the knee and ankle joints in patients under the age of 25 years. With a combination of 2.7 mm, 3.5 mm and 4.5 mm grafts, the recipient site is filled with 60% to 80% transplanted hyaline cartilage. "Fibrocartilage grouting" growing upward from the prepared cancellous bed completes the mosaicplasty procedure. Except for autogenous chondrocyte transplantation which is a two-stage and laboratory dependent procedure, among the one-stage procedures, only autogenous osteochondral mosaicplasty can theoretically result in a biomechanically and physiologically normal articular cartilage covering a full-thickness deep defect. The elasticity of the bone at the graft recipient interface causes a consistent and stable press-fit.

In this animal study the mosaicplasty on the medial femoral condyles of the sheep's knee resulted in 95.8% excellent or good result as scored by a comprehensive histopathological scoring system. There were some technical considerations with useful application in clinical practice in human subjects. Maintaining the normal convexity of the transplanted defect is provided by using osteocartilaginous cylinder graft with an oblique articular surface in the periphery of the defect. We know from basic science that cartilage nutrition depends on the load-bearing of the cartilage layers and its viscoelastic character, therefore congruous

surface and physiological motion are mandatory in cartilage nutrition from the synovial fluid.

In this study, the results of filling the defects of 1.5 cm core diameter with 6 mm diameter cylindrical grafts and defects of 1 cm core diameter with 4 mm diameter were excellent or good in 95.8% of cases. We obtained similar results in both study groups. It is concluded that the size of the defect is not the major limitation of the procedure and larger diameter grafts can be used successfully to cover larger defect without any further risk of loosening and later degeneration or graft fracture. An open or arthrotomy approach facilitates harvesting from larger donor areas from both the medial and lateral femoral condyles and if needed for an even larger defect, from the intercondylar notch, as suggested by Bobic⁴ in his technique in the treatment of A.C.L. insufficiency with cartilaginous defects when notchplasty is performed. We also hypothesize that free-range motion and activity is not harmful, at least in the animal model. This may be the subject of future investigation in a clinical setting. We packed the spaces between the cylindrical grafts using cancellous bone, which was similar to the use of cement between the mosaics, resulting in a better press-fit fixation. Histopathologic study of the specimens revealed that this action did not hinder the formation of fibrocartilage inbetween the cylinders and these small defects were also covered by normal hyaline cartilage in 50% of cases and good quality cartilage in the other 45.8%.

Conclusion

In this animal study on sheep autogenous osteochondral transplantation by mosaicplasty technique, supported by cancellous bone which was cemented between the graft columns,

combined with free-range motion and activity resulted in a high success rate as scored by a comprehensive histopathological scoring system. Preservation of normal convexity of the grafted defect and avoiding impaction of the grafts was essential. It appears that the size of the defect is not the major limitation, but further animal and clinical investigations are required.

References

- 1 Hangody L, Feczko P, Bartha L, et al: Mosaicplasty for the treatment of articular defects of the knee and ankle. *Clin Orthop* 2001; **391** (suppl):S328-36.
- 2 Coutts RD, Healey RM, Ostrander R, et al: Matrices for cartilage repair. *Clin Orthop* 2001; **391** (suppl):S271-9.
- 3 Altman RD, Gottlieb NI, Howell DS: Cartilage degradation: Is there a place for chondroprotective agents? *Semin Arthritis Rheum* 1990; **19**:1-3.
- 4 Bobic V: Arthroscopic osteochondral autograft transplantation in anterior cruciate ligament reconstruction: A preliminary clinical study. *Knee Surg Sports Traumatol Arthrosc* 1996; **3**:262-4.
- 5 Bodo G, Hangody L, Szabo Z, et al: Arthroscopic autologous osteochondral mosaicplasty for the treatment of subchondral cystic lesion in the medial femoral condyle in a horse. *Acta Vet Hung* 2000; **48**:343-54.
- 6 Cain EL, Clancy WG: Treatment algorithm for osteochondral injuries of the knee. *Clin Sports Med* 2001; **20**:321-42.
- 7 Onstott AT, Moczo A, Harris NL: Osteochondral autotransfer-newer treatment for chondral defects. *AORN J* 2000; **71**:843-5, 848-51.
- 8 Hangody L, Sukosd L, Szabo Z: Repair of cartilage defects. Technical aspects. *Rev Chir Orthop Reparatrice Appar Mot* 1999; **85**:846-57.
- 9 Hangody L, Karpati Z, Tóth J, et al: Transplantation of osteochondral autografts of the weight-bearing surface of the knee joint and the patellofemoral joint in dogs. *Sportorvosi Szemle /Hungarian Rev Sports Med* 1994; **35**:117-23.
- 10 Hangody L, Karpati Z: A new surgical treatment of localized cartilaginous defects of the knee. *Hungarian J Orthop Trauma* 1994; **37**:237-42.
- 11 Hangody L, Karpati Z, Szerb I: Osteochondral autograft implantation in the treatment of knee chondropathy. First prize poster winner of the 6th Congress of ESSKA Berlin, 1994.
- 12 Hangody L, Karpati Z, Sükösd L: Autogenous osteochondral mosaic technique. *Rev Osteology* 1995; **3**:70-3.
- 13 Hangody L, Karpati Z, Szigeti I, Sükösd L: Clinical experience with the mosaic technique. *Rev Osteology* 1996; **4**:32-6.
- 14 Hangody L, Sukosd L, Szigeti I, et al: Arthroscopic autogenous osteochondral mosaicplasty. *Hungarian J Orthop Trauma* 1996; **39**:49-54.
- 15 Hangody L, Anthony Miniaci, Kish G: Mosaicplasty osteochondral grafting technique guide. 1996.
- 16 Lane JM, Brighton CT: Joint resurfacing in the rabbit using an autologous osteochondral graft. *J Bone Joint Surg* 1977; **59**:218-22.
- 17 Lindholm TS, Osteman K, Kimmunen P, et al: Reconstruction of the joint surface using osteochondral fragment. *Scand J Rheumatol* 1982; **44**(Suppl):5.
- 18 O'Driscoll SW: Current concepts review the healing and regeneration of articular cartilage. *J Bone Joint Surg* 1998; **80A**:1795-804.
- 19 Shahgaldi BF, AA Amis, Heatly FW, et al: Repair of cartilage lesions using biological implants: A comparative histological and biomechanical study in goats. *J Bone Joint Surg Br* 1991; **73B**:57-64.
- 20 Yamashita F, Sakakida K, Susu F, Talai S: The transplantation of an autogenic osteochondral fragment for osteochondritis dissecans of the knee. *Clin Orthop* 1985; **201**:43.