

# Paraganglioma of the Larynx: A Case Report

B. Khademi\*, L. Taghizadegan\*\*,  
B. Gandomi\*, M. Vasei\*\*

## Abstract

Paraganglioma of the larynx is a rare neoplasm which mostly arises from supraglottic area. Herein, we report on a 45-year-old woman presented with supraglottic laryngeal paraganglioma.

**Iran J Med Sci 2004; 29(1):47-49.**

**Keywords** • Paraganglioma • larynx • supraglottis

## Introduction

**P**araganglionic tissue has been demonstrated in more than 20 areas of the human body. Neoplasm or paraganglioma has been described in most of these sites.<sup>1</sup> While these tumors are most frequently occurred in carotid bifurcation (carotid body tumor), the inferior ganglion and cervical portion of the vagus nerve (vagal body tumor) and the temporal bone (jugular body tumor), they may affect head and neck tissues and involve the orbit, mandible, trachea, nasal cavity and larynx. To date, few laryngeal paragangliomas have been described.<sup>2</sup> Herein, we present a case of laryngeal paraganglioma and review the literature.

## Case Report

A 45-year-old woman with a 6-month history of hoarseness, mild respiratory distress and dysphagia was referred to Motahari ENT Clinic affiliated with Nemazee Hospital, Shiraz, Iran. On direct laryngoscopy, a submucosal mass was seen, pushing the right vocal cord medially. Contrast enhanced computed tomography (CT) scan showed a 4×3 cm irregular submucosal mass arising from the left side of the supraglottic area and causing obliteration of the air space in the right supraglottic area (Fig 1). The mass was totally resected through an anterolateral cervical approach. Histopathologic study revealed a highly vascular tumor composed of nests of cells producing typical Zellballen appearance. The main cells appeared round to polygonal with an amphophilic cytoplasm and moderately hyperchromatic nuclei with no prominent nucleoli. There were also angulated sustentacular cells located in the wall of nests with hyperchromatic dark spindle-shaped nuclei. Immunohistochemical staining showed round cells with intracytoplasmic chromogranin, neuron-specific enolase and synaptophysin, but were devoid of keratin and S100 (Fig 2). Cytoplasmic and nuclear S100 positivity was noted in sustentacular cells (Fig 3).

## Discussion

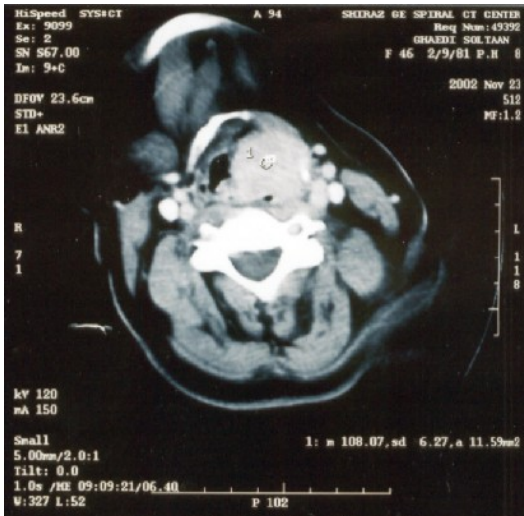
Paraganglioma originates from the paraganglionic cells of the parasympathetic system, which is regarded as a neuroendo-

\*Departments of Otolaryngology and  
\*\*Pathology, Shiraz University of  
Medical Sciences, Shiraz, Iran

**Correspondence:** B. Khademi, M.D,  
Department of Otolaryngology, Khalili  
Hospital, Shiraz, Iran.

**Tel/Fax:** +98- 711-6279372

**E-mail:** [Khademib@yahoo.com](mailto:Khademib@yahoo.com)

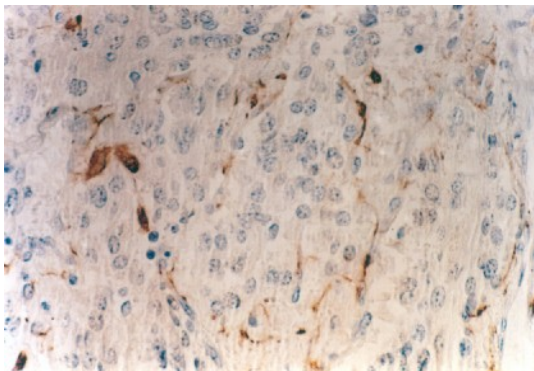


**Fig 1:** Contrast enhanced CT scan showing a 4x3 cm mass arising from left side of supraglottic area causing partial obliteration of the air space.

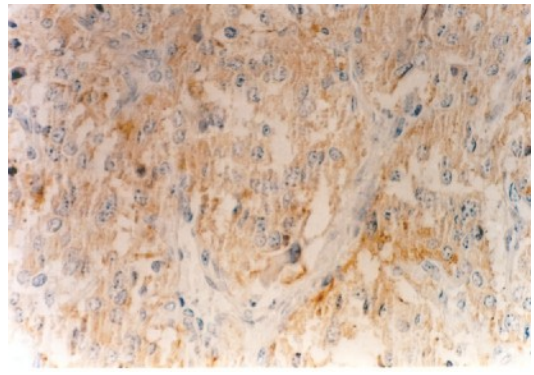
crine neoplasm of neural type.<sup>3</sup> The tumor is recorded in the second to ninth decades of life, and is three times more common in women than in men.<sup>4</sup>

The lesion is frequently localized in the supraglottic region, particularly in the right aryepiglottic fold, but subglottic tumors may occasionally occur. A wide variety of symptoms such as hoarseness, dysphagia, dyspnea, stridor, dysphonia, sore throat, and hemoptysis have been reported. As a rule, this tumor is nonfunctional and most reported cases of alleged functional paraganglioma were probably atypical carcinoid tumors.<sup>5</sup> Multiple paragangliomas of the head and neck with laryngeal involvement have also been recorded.<sup>6</sup>

Macroscopically, laryngeal paragangliomas have been described as being red or blue submucosal masses. On sectioning they are firm and rubbery with a red or brown cut sur-



**Fig 2:** Immunohistochemistry showing typical Zellballen appearance and cytoplasmic reactivity for chromogranin in the main cells (x400).



**Fig 3:** Immunohistochemistry showing cytoplasmic and nuclear S100 reactivity in sustentacular cells (x400)

face in which areas of hemorrhage and fibrosis may be seen. Microscopically, laryngeal paragangliomas have the same appearance as paragangliomas of other sites. The tumor is composed of two cell types: Chief cells and sustentacular cells. Chief cells are polygonal cells with inconspicuous nuclei and eosinophilic cytoplasm. There may be some pleomorphism, but mitoses are not usually seen.<sup>7</sup> These cells are packaged into the characteristic non-pathognomonic Zellballen or cell ball (Fig 2). Around the edge of the Zellballen are the second type of cells which are slender, spindle shaped sustentacular cells. The tumors are highly vascular. A fibrous capsule can frequently surround the tumor. The presence of vascular, capsular or perineural invasion does not necessarily indicate aggressive behavior.<sup>7</sup> Differentiation of paragangliomas from atypical carcinoids appears to be a difficult process. Accurate diagnosis is a must, because the former is considered as a benign process, whereas the latter acts quite lethally.<sup>7</sup> At first, it appeared that there were two types of laryngeal paragangliomas with one being rather innocuous, and the other acting more aggressively. Ferlito *et al*,<sup>4</sup> after extensive review of the cases and reclassifying the tumors, believed that aggressive group of laryngeal paragangliomas were actually atypical carcinoids.

Only 65 adequately studied laryngeal paragangliomas have been reported and most of these were located in the supraglottis.<sup>8</sup> We present another case of supraglottic laryngeal paraganglioma which after complete excision of the tumor exhibited no sign of recurrence over two years of follow-up.

## References

- 1 Batsakis JG: Tumors of the head and neck: Clinical and pathologic considerations. Baltimore: Williams and Wilkins, 1974;280-288.
- 2 Wetmore RF, Tronzo RD, Lane RJ, Lowry LD. Nonfunctional Paraganglioma of the Larynx. *Cancer* 1981;48:2717-2723.
- 3 Ferlito A, Rosai J: Terminology and classification of neuroendocrine neoplasms of the larynx. *ORLJ Otorhinolaryngol Relat Spec* 1991;53: 185-7.
- 4 Ferlito A, Barnes L, Wenig BM: Identification, classification, treatment and prognosis of laryngeal paraganglioma. Review of the literature and eight new cases. *Ann Otol Rhinol Laryngol* 1994;103:525-36.
- 5 Ferlito A, Friedmann I: The contribution of immunohistochemistry in the diagnosis of neuroendocrine neoplasms of the larynx. *ORL J Otorhinolaryngol Relat Spec* 1991;53:235-44.
- 6 Hartmann E: Chemodectoma laryngis. *Acta Otolaryngo l(Stockh)* 1960;51:528-32.
- 7 Ferlito A, Milroy CM, Wenig BM, Barnes L, et al: Laryngeal paraganglioma versus atypical carcinoid tumor. *Ann Otol Rhinol Laryngol* 1995;104:78-83.
- 8 A diagnostic and therapeutic approach to paragangliomas of the larynx. *Arch of Otol Head and Neck Surg* 2001;127(5):565-569.