

# Concomitant Celiac, Superior Mesenteric, Renal, and Aorto-bi-iliac Aneurysms

M. Lotfi, S.A. Nabavizadeh, A. Meshksar

## Abstract

Visceral artery aneurysms are rarely reported. They can occur in the context of a variety of underlying diseases. These aneurysms may coexist with non-visceral arterial aneurysms.

Here we describe an 80-year-old man with concomitant superior mesenteric, celiac, renal, and aorto-bi-iliac aneurysms. The patient was a hypertensive and hyperlipidemic old man with history of transient ischemic attack and atherosclerotic carotid plaques who developed multiple aneurysms most likely due to degenerative atherosclerotic vascular involvement. To the best of our knowledge, this constellation of aneurysms has not yet been reported.

**Iran J Med Sci 2008; 33(4): 248-251.**

**Keywords** • Mutiple • visceral aneurysms • atherosclerosis

## Introduction

**V**isceral artery aneurysms are rare vascular diseases whose pathogenesis and natural history remain incompletely understood. Although the introduction of precise diagnostic procedures has made the diagnosis of visceral artery aneurysms easier, they are still difficult to be detected due to their uncommon clinical presentations.

Here we describe an 80-year-old man with concomitant celiac, superior mesenteric, renal, and aorto-bi-iliac aneurysms. To the best of our knowledge, this constellation of arterial aneurysms has not yet been described.

## Case Presentation

An 80-year-old man was referred to our hospital with complaint of tarry stool and one episode of vomiting of coffee ground material. Comorbid conditions included hypertension, hyperlipidemia, and one episode of transient ischemic attack (TIA) 15 months prior to his present problem. He consumed hypertensive and lipid lowering drugs and also received anticoagulant and antiplatelet agents due to his previous TIA and presence of atherosclerotic carotid plaques.

His laboratory data included a prothrombin time of 21 s (INR=3.1). The sedimentation rate, VDRL, liver function test, complete blood count (CBC), and C-reactive protein were normal. Given the presence of bloody vomiting, the patient underwent an upper gastrointestinal endoscopy that revealed esophageal varicosities (grade I/IV) and a white based ulcer in lesser curvature of the stomach without active bleeding. Pathological examination of the biopsy specimen revealed mild chronic gastritis with no evidence of malignancy. Due to

Department of Radiology,  
Shiraz University of Medical Sciences,  
Shiraz, Iran.

### Correspondence:

Ali Nabavizadeh MD,  
Department of Radiology,  
School of Medicine,  
Shiraz University of Medical Sciences,  
Shiraz, Iran.

**Tel/Fax:** + 98 711 6263233

**Email:** [nabavia@gmail.com](mailto:nabavia@gmail.com)

Submitted: 17 January 2008

Revised: 12 March 2008

Accepted: 20 July 2008

the presence of esophageal varicosities and clinical suspicion of portal vein thrombosis, a Doppler ultrasonography of portal venous system was performed, which revealed normal diameter and flow in portal and splenic veins with no evidence of thrombosis. However aneurismal dilatation of celiac and superior mesenteric arteries and lower part of abdominal aorta and both iliac arteries were found incidentally during the ultrasonographic examination (figure 1).

Abdominal computed tomography (CT) was performed that revealed aneurismal dilatation of main celiac artery (20mm) and its main branches (figure 2). The aneurismal dilatation of celiac artery only involved the proximal celiac artery and had no significant extension into the splenic and hepatic branches. There was also aneurismal dilatation (21mm) of superior mesenteric artery (SMA) from the site of origin up to the distal part. The maximum anteroposterior (AP) diameter of SMA was 45 mm associated with significant circumferential intraluminal thrombosis with patent lumen measuring about 10mm in its narrowest portion. The diameter of abdominal aorta from hiatus down to 4 cm above the aortic bifurcation was normal with no thrombosis; however aneurismal dilatation of distal abdominal aorta with extension to both sides of common, external, and internal iliac arteries was also seen. No extension into the femoral arteries was noted. The AP diameter of distal abdominal aorta and right and left iliac

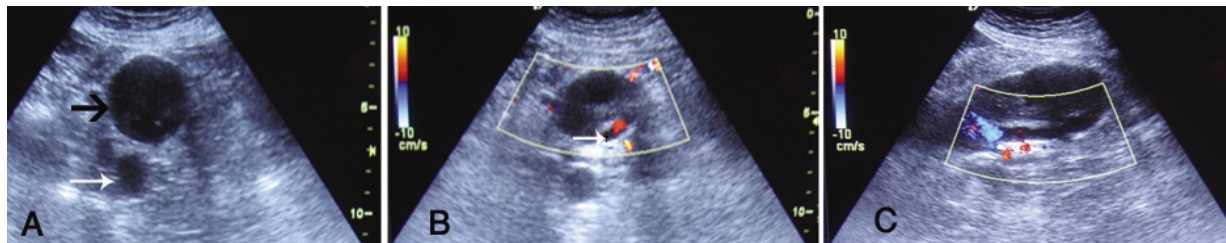arteries were 38, 41, and 41 mm respectively with circumferential intraluminal thrombosis in the latter vessels despite their patent lumen.

In addition to the above findings, engorgement of the left renal vein was also seen due to impingement between dilated SMA and aorta (nutcracker effect). Calcification of the wall of SMA, aorta, and both iliac arteries were notable.

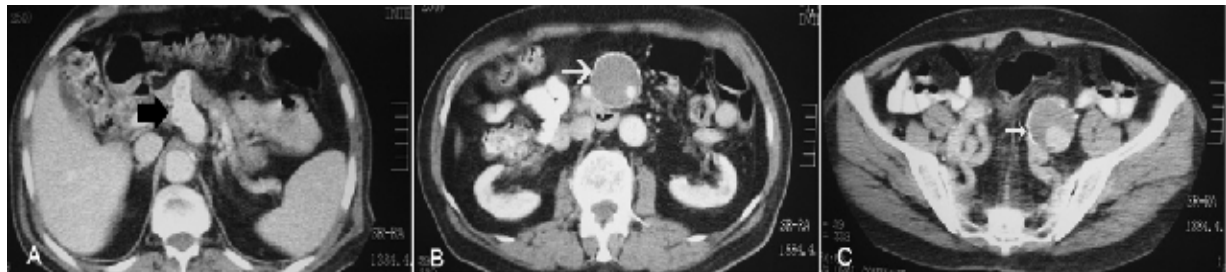
Because of the patient's concomitant medical problems, extreme age, and limited life expectancy, the patient and his family preferred conservative management and close clinical observation and regular follow-ups.

Six months later, magnetic resonance angiography (MRA) of abdomen revealed irregularity and tortuosity of abdominal aorta accompanied by aneurismal dilatation of distal abdominal aorta with extension to both common iliac arteries (figure3). Previously mentioned aneurismal dilatation of main celiac trunk and SMA were also seen in this study. There was also apparent dilatation of proximal part of right main renal artery, which was not detected in the previous abdominal CT scan. Because MRA is a flow related modality which only measures the internal aspect of a vessel, comparison of the size of aneurysm in the time interval between the two studies (by CT and MRA) was not possible.

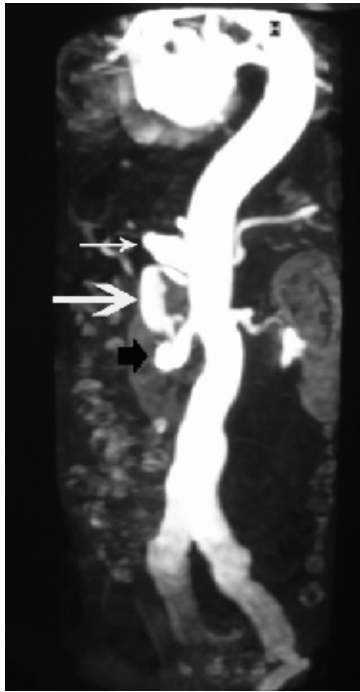
Since then; he has remained asymptomatic and stable, with no evidence of further expansion of his aneurysms in routine sonographic examinations.



**Figure 1:** Transverse grayscale sonogram (A) reveals aneurismal dilatation of superior mesenteric artery (black arrow), which is significantly larger than abdominal aorta (white arrow). Color Doppler sonogram (B, C) reveals significant circumferential intraluminal thrombosis of superior mesenteric artery with a narrow patent lumen (white arrow) both in transverse and sagittal views.



**Figure 2:** Axial contrast-enhanced tomogram reveals aneurysms of celiac (A, black arrow), superior mesenteric (B, white arrow), and both common iliac arteries (C, small white arrow). The superior mesenteric artery is significantly larger than abdominal aorta secondary to aneurismal dilatation.



**Figure 3:** Magnetic resonance angiography of abdomen showing irregularity and tortuosity of abdominal aorta accompanied by aneurysmal dilatation of distal abdominal aorta with extension to both common iliac arteries. Aneurysmal dilatation of main celiac trunk (small white arrow) and superior mesenteric artery (large white arrow) and apparent dilatation of proximal part of right main renal artery (black arrow) are also seen.

## Discussion

Celiac artery aneurysms are among the rare splanchnic artery aneurysms with fewer than 180 reported cases since its first description in 1745.<sup>1,2</sup> A gradual evolution in the cause of celiac artery aneurysms has occurred during the last century.<sup>1</sup> Prior to 1950, most celiac artery aneurysms were secondary to syphilis. Since 1950, most appear secondary to medial degeneration and atherosclerosis. Less common causes include trauma, aortic dissection, and mycotic aneurysms.<sup>1</sup> Celiac artery aneurysm often presents with epigastric abdominal pain and abdominal bruit.<sup>3</sup> Although some physicians avoided treatment, most authors believe that early intervention is warranted in most patients.<sup>4,5</sup>

Superior mesenteric artery aneurysms are the third most commonly encountered visceral artery aneurysm.<sup>3</sup> Unlike most visceral artery aneurysms, SMA aneurysms are often symptomatic. Typically, patients present with moderate to severe abdominal pain that is usually progressive in course making it difficult to be distinguished clinically whether the pain arises secondary to aneurysm expansion or to relative mesenteric ischemia.<sup>3</sup>

Historically, an infectious etiology has been

the most common cause of SMA aneurysms.<sup>3</sup> However, more recent case series have shown that infectious cause is less common.<sup>6,7</sup> Nonetheless, the SMA remains the most common site for infection of a peripheral muscular artery.<sup>8</sup> The etiology of SMA aneurysms in more recent case series implicates atherosclerosis as one of the most common pathologic findings.<sup>6,7</sup> Although some authors have considered the risk of rupture of superior mesenteric aneurysms to be quite small,<sup>7</sup> others believe that these aneurysms carry a definite rupture risk, which is higher in male patients. They concluded that all superior mesenteric aneurysms should be considered for repair in patients at good operative risk.<sup>6</sup>

Laminated thrombus formation within the aneurysm of the SMA has been shown to be a protective factor against thrombosis or rupture in some case series.<sup>6</sup>

Aneurysm formation may be due to cystic degeneration of arterial wall. Cystic medial necrosis is associated with Marfan syndrome. Furthermore, splanchnic artery aneurysm has been described in patients with Marfan syndrome.<sup>9</sup> However, our patient was not tall and did not show Marfanoid signs.

Ehlers-Danlos syndrome is another collagen-vascular disease that leads to aneurysm formation with associated cystic medial necrosis and has also been associated with celiac artery aneurysm.<sup>10</sup> Other causes of aneurysms formation including infectious etiologies and autoimmune disorders were also unlikely in our patient because he had no fever, no elevated white blood cell counts, and no evidence of infection elsewhere in the body.

Polyarteritis nodosa is a vasculitis that involves small and medium sized arteries. It can also lead to visceral artery aneurysm; however our patient did not show any other manifestation of this disease. Systemic lupus erythematosus, Behçet's disease, isolated cystic medial necrosis, and neurofibromatosis have also been associated with visceral artery aneurysms, but the patient's clinical manifestations did not correlate to any of the disease entities.<sup>3,6</sup> Our patient was a hypertensive hyperlipidemic old man with history of TIA and atherosclerotic carotid plaques, so the most possible predisposing factor seemed to be the atherosclerosis. The presence of calcification in the arterial walls was a further clue to the presence of degenerative atherosclerotic phenomenon. Association of visceral aneurysms with concomitant non-visceral arterial aneurysms is frequent,<sup>11</sup> and has been repeatedly described in the literature.<sup>12,13</sup> This has also occurred in our patient and he had concomitant

renal, and aorto-bi-iliac aneurysms.

It has been shown that MR angiography may be a useful noninvasive method for determining the presence of coexistent celiac, superior mesenteric, renal, and iliac atherosclerotic disease in patients with abdominal aortic aneurysms.<sup>14,15</sup> This modality also worked well in our patient by showing the celiac, superior mesenteric, and aorto-bi-iliac aneurysms plus the previously unsuspected right renal artery aneurysm.

**Conflict of Interest:** None declared

## References

- 1 Graham LM, Stanley JC, Whitehouse WM Jr, et al. Celiac artery aneurysms: historic (1745-1949) versus contemporary differences in etiology and clinical importance. *J Vasc Surg* 1985; 2: 757-64.
- 2 McMullan DM, McBride M, Livesay JJ, et al. Celiac artery aneurysm. *Tex Heart Inst J* 2006; 33: 235-40.
- 3 Messina LM, Shanley CJ. Visceral artery aneurysms. *Surg Clin North Am* 1997; 77: 425-42.
- 4 Shanley CJ, Shah NL, Messina LM. Common splanchnic artery aneurysms: splenic, hepatic, and celiac. *Ann Vasc Surg* 1996; 10: 315-22.
- 5 Matsuo R, Ohta Y, Ohya Y, et al. Isolated dissection of the celiac artery-a case report. *Angiology* 2000; 51: 603-7.
- 6 Stone WM, Abbas M, Cheryy KJ, et al. Superior mesenteric artery aneurysms: Is presence an indication for interventions? *J Vasc Surg* 2002; 36: 234-7.
- 7 Stanley JC, Wakefield TW, Graham LM, et al. Clinical importance and management of splanchnic artery aneurysms. *J Vasc Surg*.1986; 3: 836-40.
- 8 Ohmi M, Kikuchi Y, Ito A, Ouchi M. Superior mesenteric artery aneurysm secondary to infectious endocarditis. *J Cardiovascular Surg (Torino)* 1990; 31: 115-7.
- 9 Sarkar R, Coran AG, Cilley RE, et al. Arterial aneurysm in children: Clinicopathologic classification. *J Vasc Surg* 1991; 13: 47-56.
- 10 Parfitt J, Chalmers RT, Wolfe JH. Visceral aneurysms in Ehlers-Danlos syndrome: care report and review of literature. *J Vasc Surg* 2000; 31:1248-51.
- 11 Stone WM, Abbas MA, Gloviczki P, et al. Celiac arterial aneurysms: a critical reappraisal of a rare entity. *Arch Surg* 2002; 137: 670-4.
- 12 Abe H, Funaki S, Suzuki T, Makuuchi H. Thoracoabdominal aortic aneurysm combined with inferior mesenteric artery aneurysm and occlusion of celiac and superior mesenteric arteries. *Kyobu Geka* 2006; 59: 459-63.
- 13 Do Carmo G, Rosa A, Gama AD. Aneurysm of superior mesentric artery in the context of a multianeurismatic disease. Case report. *Rev Port Cir Cardiotorac Vasc* 2005; 12: 35-9.
- 14 Kaufman JA, Geller SC, Petersen MJ, et al. MR imaging (including MR angiography) of abdominal aortic aneurysms: comparison with conventional angiography. *Am J Roentgenol* 1994; 163: 203-10.
- 15 Carriero A, Iezzi A, Tonni G, et al. Abdominal aorta:role of angiography with magnetic resonance. *Radiol Med (Torino)* 1993; 85:170-5.