

Unusual Presentation of Squamous Cell Carcinoma on Long-Standing Sacrococcygeal Pilonidal Sinus

Shahram Bolandparvaz^{1,2},
Ali Akbar Mohammadi^{2,3}, Hooman Riazif^{2,3},
Ahmad Monabbati⁴, Bitia Geramizadeh⁴

Abstract

Pilonidal disease consists of a hair-containing sinus or abscess occurring most frequently in intergluteal cleft. This disease is generally benign. Although very uncommon entity, it seems reasonable to be aware of possible malignancy in longstanding cases. We report a case of squamous cell carcinoma in a 52-year-old man, with a prolonged history of pilonidal disease and ulceration since 3 months before referring to our clinic. We excised the cyst, and the pathologic evaluation reported moderate differentiated squamous cell carcinoma. So, re-operation on the lesion site to excise a 2-cm margin was performed and the defect was covered with Limberg cutaneous flap. We recommend early excision of pilonidal cysts to prevent possible malignant degeneration. Histological examination of the excised materials to prevent missing rare malignant cases is recommended.

Iran J Med Sci 2009; 34(2): 149-151.

Keywords • Pilonidal cyst • squamous cell carcinoma • wound • flap

Introduction

Pilonidal disease consists of a hair-containing sinus or abscess occurring most frequently in intergluteal cleft. The disease occurs primarily in young adults and is four times more common in men.¹ This disease is generally benign and malignancy is extremely rare in this setting,² however, few cases have been reported worldwide with different types of malignancy, most of which have been squamous cell carcinoma. Other reported malignancies include: basal cell carcinoma,² adenocarcinoma of sweat gland type,² giant condyloma acuminatum,³ myxopapillary ependymoma,⁴ and chordoma.⁵

Although very uncommon entity, it seems reasonable to be aware of possible malignancy in long-standing cases, especially atypical ones or those that present with ulceration, overgrowth, sanguinopurulent drainage, and inguinal adenopathy.² Early excision of pilonidal cyst, which is the conventional treatment of pilonidal disease, seems to be a reasonable approach to alleviate the concern of possible malignant degeneration in long-standing cases.

Herein we report a case of squamous cell carcinoma in a patient with a prolonged history of pilonidal disease.

¹Trauma Research center,
²Department of Surgery,
³Shiraz Burn Research Center,
⁴Department of Pathology,
Shiraz University of Medical Sciences,
Shiraz, Iran.

Correspondence:

Ali Akbar Mohammadi MD,
Department of Surgery,
Department of Surgery,
Shiraz Burn Research Center,
Shiraz University of Medical Sciences,
Shiraz, Iran.
Tel: +98 711 8219640-2
Fax: +98 711 8217090
Email: mohamadiaa@sums.ac.ir
Received: 8 June 2008
Revised: 2 November 2008
Accepted: 15 January 2009

Case Report

A 52-year-old man who was a retired military electronic technician, presented with malodor discharge from intergluteal cleft since 6 years ago. He noticed an ulcerated mass in the place since 3 months before, which gradually increased in size and had irregular borders (figure 1). He had a history of 35 pack-year cigarette smoking and 2-3 grams opium ingestion per day. No inguinal lymphadenopathy was detected. Laboratory evaluation for HIV infection was negative.

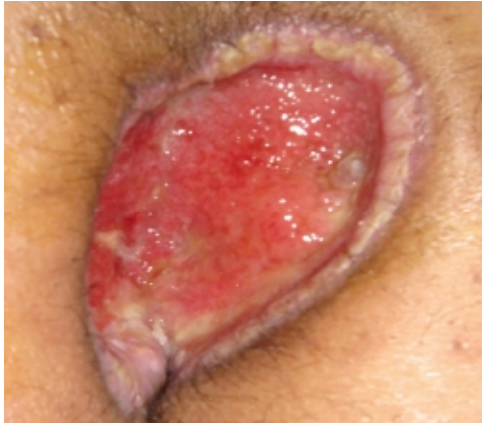

Figure 1: Ulcerative lesion in long-standing pilonidal sinus.

The lesion was excised and sent for pathologic examination, which reported moderate differentiated squamous cell carcinoma with involvement of tumor's inferior margin. So, re-excision with 3 cm margin was performed and the defect was covered with Limberg cutaneous flap. The specimen's margins were free of tumoral cells in the second pathologic examination. On histological investigation (figure 2), tumor cells were seen in a sinus tract and numerous inflammatory cells (plasma cells and lymphocytes) and foreign body type granuloma were detected around the sinus tract.

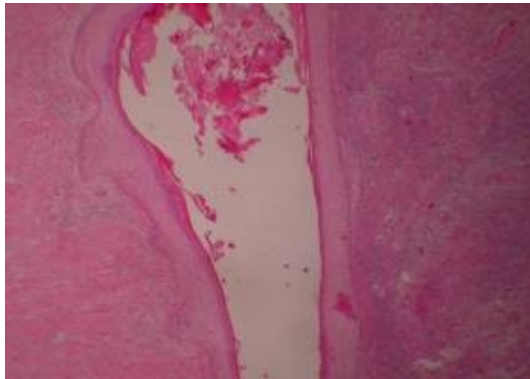


Figure 2: Low power view of sinus tract in the center surrounding islands of malignant epithelial cells.

Discussion

The development of squamous cell carcinoma is an extremely rare complication following recurrent pilonidal disease. Malignant transformation generally occurs over the long-standing sinus tracts or chronic infected wounds.⁴ Pathophysiology of this neoplastic transformation is mainly thought to be similar to Marjolin's ulcer.⁶ Malignant transformation should be taken into consideration for all long-standing recurrent pilonidal sinus disease and in any neighboring lesions with atypical presentation.⁷

Davis and co-workers reviewed 44 cases of malignancy arising from pilonidal disease. Of them, 36 were squamous cell carcinoma and all of them had occurred in the setting of long-standing pilonidal disease with the mean duration of antecedent disease of 23 years.²

The tumors arising from pilonidal disease tend to be slow growing, but with a tendency toward aggressive local invasion and metastasis.^{2,8} Ulceration, overgrowth, sanguinopurulent drainage, and inguinal adenopathy are gross symptoms suggesting malignant association. Presentation with inguinal adenopathy is a poor prognostic sign.^{2,9} In report by Davis and coworkers, five of six patients presented with inguinal metastases died within 16 months.² Some authors have suggested adjuvant chemotherapy and radiation therapy along with surgery to decrease the local recurrence rate.²

Absence of transitional cells to support the definitive transformation of pilonidal sinus cells in our pathologic slide might be due to complete development of malignant process. Likewise, despite no specific evidence of pilonidal cyst such as presence of hair follicles existed in our slide, significant inflammation and foreign body granuloma can strongly support the possibility of malignant transformation of pilonidal sinus in our reported case. On the other hand hair follicles cannot be found even in many typical pilonidal sinuses. Accordingly, the most possible origin of squamous cell carcinoma in this case is his long-standing pilonidal sinus.

Excision of a symptomatic pilonidal cyst is the conventional surgical approach for managing the disease. We recommend early excision and careful pathological review of the excised sample in long-standing and ulcerative pilonidal sinus. This could prevent infective complications and possible malignant transformation.⁹

Conflict of Interest: None declared

References

- 1 Hull TI, Wu J. Pilonidal disease. *Surg Clin North Am* 2002; 82: 1169-85.
- 2 Davis Ka, Mock Cn, Versaci A, Lentricchia P. Malignant degeneration of pilonidal cysts. *Am Surg* 1994; 60: 200-4.
- 3 Norris CS. Giant condyloma acuminatum (Buschke-Lowenstein tumor) involving a pilonidal sinus: a case report and review of the literature. *J Surg Oncol* 1983; 22: 47-50.
- 4 Barton S, Mirza M, Fielding J. A case of subcutaneous myxopapillary ependymoma presenting as a pilonidal sinus. *Surgeon* 2004; 2: 292-3.
- 5 Beattie GC, Millar L, Nawroz IM, Browning GG. A case of sacro-coccygeal chordoma masquerading as pilonidal sinus. *J R Coll Surg Edinb* 2000; 45: 254.
- 6 Cilingir M, Eroğlu S, Karacaoğlan N, Uysal A. Squamous carcinoma arising from chronic pilonidal disease. *Plast Reconstr Surg* 2002; 110: 1196-8.
- 7 Agir H, Sen C, Cek D. Squamous cell carcinoma arising adjacent to a recurrent pilonidal disease. *Dermatol Surg* 2006; 32: 1174-5.
- 8 Kim YA, Thomas I. Metastatic squamous cell carcinoma arising in a pilonidal sinus. *J Am Acad Dermatol* 1993; 29: 272-4.
- 9 Val-Bernal JF, González-Vela MC, Hermana S, et al. Pilonidal sinus associated with cellular blue nevus ,A previously unrecognized association. *J Cutan Pathol* 2007; 34: 942-5.