

Pacemaker Twiddler's Syndrome

M. Zamirian, M.B. Sharif Kazemi,
A.R. Moarref

Abstract

A 76-yr-old man with unipolar ventricular pacemaker, previously implanted in the right ventricular apex, presented with syncopal attack and twitching of the right pectoralis muscle. He finally was diagnosed as having Twiddler's syndrome. The patient had a pulse rate of 36/min and cannon waves in the neck veins. Chest radiography showed a dislodged pacing lead completely wrapped around the pulse generator. After uncoiling the lead it was positioned in the right ventricular apex and the pulse generator implanted and sewed tightly in a smaller pocket. After six months follow-up there was no further twiddling or pacemaker dysfunction.

Iran J Med Sci 2006; 31(1): 59-60.

Keywords • Twiddler's syndrome • pacemaker • syncopal attack

Introduction

Twiddler's syndrome (TS) is a very rare complication of pacemaker and implantable cardioverter defibrillator.¹ It is characterized by spontaneous, inadvertent or deliberate rotation of implanted pulse generator leading to lead dislodgement, fracture or both.² The condition typically presents with device malfunction.³ Herein we present a case of TS in whom inadvertent pacemaker generator rotation was resulted in complete coiling of pacemaker lead around the pulse generator causing total loss of capture beat.

Case presentation

A 76-yr-old man was brought to the emergency room with episodes of syncopal attack and complete atrioventricular block. A uniplar ventricular pacing lead was implanted in the right ventricular apex through right subclavian vein puncture. The patient was discharged two days later and was subsequently missed to follow-ups. Two months later he was readmitted to the emergency room due to syncopal attack and twitching of the right pectoralis muscle. Physical examination revealed a pulse rate of 36/min and cannon waves in the neck veins. Electrocardiogram revealed complete AV block and absence of pacemaker artifact.

Chest radiography showed a dislodged pacing lead which was completely wrapped around the pulse generator (Fig 1). He was brought to the catheterization room where a second procedure was done. After uncoiling the lead it was checked for any site of fracture. Afterward, a second subclavian puncture was performed and the same lead was positioned in the right ventricular apex. Finally the pulse generator was implanted in the same location and sewed tightly in a smaller pocket. During six-month follow-up there was no further twiddling or pacemaker dysfunction.

Division of Cardiology,
Department of Internal Medicine,
Nemazee Hospital,
Shiraz University of Medical Sciences,
Shiraz, Iran.

Correspondence:

Mahmood Zamirian MD,
Department of Internal Medicine,
Nemazee Hospital,
Shiraz University of Medical Sciences,
Shiraz, Iran.

Tel/Fax: +98 711 6261089

E-mail: drzamirian@yahoo.com

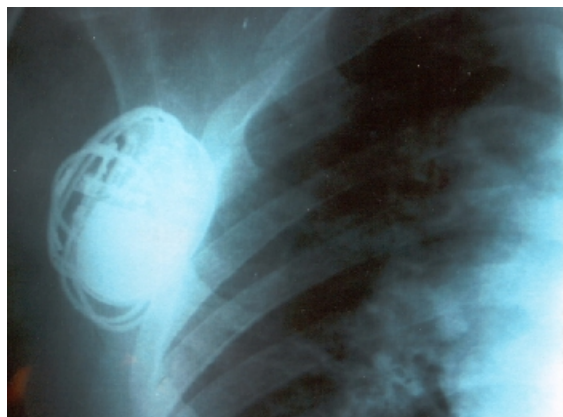


Fig 1: Detail of posteroanterior chest radiography showing the pulse generator and the completely wrapped pacemaker lead.

Discussion

Twiddler's syndrome is an extremely infrequent complication of pacemaker or implantable cardioverter defibrillator. It is a painless phenomenon and the majority of the patients, as our patient, deny the history of manipulation of their device.⁴⁻⁶ The syndrome is most often seen in those with untethered pulse generators, in obese females and those with large capacious pacemaker pockets and especially in elderly patients who have laxity of the subcutaneous tissues.⁵ Patients with psychiatric disorders are also prone to develop such a complication. Manipulation and rotation of the pulse generator can cause gradual dislodgement of the lead from the implanted site. If it is pulled high enough, the pacemaker tip, during its Journey, can stimulate the diaphragm, vagus nerve, phrenic nerve, pectoralis muscle and brachial plexus, and finally may wrap around the pulse generator.⁴⁻⁷

Our patient had twitching of the right pectoralis muscle and the pacemaker lead was completely wrapped around the pulse generator. Surgical exploration revealed that the size of the pocket exceeded far from the size of the pacemaker pulse generator, providing a good situation for pacemaker generator manipulation and rotation leading to lead displacement. TS may lead to a series of complications such as syncopal attack and lethal cardiac dysrhythmias, especially in pacemaker dependent

patients.⁶ Various preventive measures such as paying careful attention to the patient's complaints, being alert to the subtle lead change on the chest radiography may help the physician to recognize TS before causing dangerous events. Meticulous patients education before discharge, careful follow-up, especially during the first few months of implantation, stabilization of pulse generator with the use of smaller pocket and most importantly adequate fixation of the device by sewing the pacemaker body to the fascia in the surgical pocket, and finally using Dacron patch which stabilizes the pulse generator by promoting tissue in-growth,⁸ all will reduce the risk of development of Twiddler's syndrome.

References

- 1 Boyle NG, Anselme F, Monahan KM, et al. Twiddler's syndrome variants in ICD patients. *Pacing Clin Electrophysiol* 1998; 21: 2685-7.
- 2 Young KR, Bailey WM. Twiddler's syndrome: an unusual cause of pacemaker malfunction. *J La State Med Soc* 2002; 154: 152-3.
- 3 Bayliss CE, Beanlands DS, Baird RJ. The pacemaker-Twiddler's syndrome: a new complication of implantable transvenous pacemakers. *Can Med Assoc J* 1968; 99: 371-3.
- 4 Nicholson WJ, Tuohy KA, Tilkemeier P. Twiddler's Syndrome. *N Engl J Med* 2003; 348: 1726-7.
- 5 Khalilullah M, Khanna SK, et al. Pacemaker Twiddler's syndrome: a note on its mechanism. *J Cardiovasc Surg* 1979; 20: 95-100.
- 6 Avitall B, Stormo A, Barragry T, et al. Sudden cardiac death: Twiddler's syndrome with an implantable cardioverter defibrillator. *Am Heart J* 1994; 128: 833-6.
- 7 Kumar A, Mckay CR, Rahimtoola SH. Pacemaker Twiddler's Syndrome: an important cause of diaphragmatic pacing. *Am J Cardiol* 1985; 56: 797-9.
- 8 Robinson LA, Windle JR. Defibrillator Twiddler's syndrome. *Ann Thorac Surg* 1995; 59: 544-51.