

## ASSOCIATION OF BEHCET'S DISEASE WITH OSTEOGENESIS IMPERFECTA IN A TEN-YEAR-OLD GIRL

Sh. Samangoeei,<sup>\*</sup> S.M. Hakim,<sup>\*</sup> M. Mehryar<sup>\*\*</sup>

<sup>\*</sup>Department of Rheumatology, <sup>\*\*</sup>Department of Ophthalmology, Shiraz University of Medical Sciences, Shiraz

### ABSTRACT

Osteogenesis Imperfecta (OI) is a genetic disorder characterized by bones that break easily, often from little or no apparent cause. In this article, we present a patient suffering from OI, who had concomitant active Behçet's Disease (BD) with repeated oro-genital ulcers, skin postular eruptions and severe recurrent bilateral uveitis. This patient, is, to our knowledge the first reported case in literature.

*Im J Med Sci* 2001; 26(3&4):171-173

**Key Words** • Behçet's disease • osteogenesis imperfecta • uveitis

### Introduction

Osteogenesis Imperfecta (OI) is a rare genetically determined disorder of connective tissue characterized by hereditary bone fragility. The disease state encompasses a phenotypically and genotypically heterogeneous group of inherited disorders that result from mutations in the genes that code for type I collagen. Other manifestations include blue sclera, joint laxity, scoliosis and easy bruising. The skeletal manifestations tend to diminish after puberty.<sup>1</sup>

Incidence of OI is thought to be approximately 1 in 15,000 to 20,000 births. There is an extreme variability in the manifestations, indicating clinical as well as

genetic heterogeneity. Thus, the OI syndrome has been sub-classified using clinical and genetic criteria. Classification is based on the timing of fractures or on multiple clinical, genetic, and radiologic features. There are at least four recognized forms of the disorder, representing extreme variation in severity from one individual to another.<sup>2,3</sup>

Behçet's disease is a common medical problem along the "Old Silk Route", which spans the region from Japan and China in the Far East to the Mediterranean Sea, including countries such as Turkey and Iran.<sup>4</sup>

### Case Presentation

We are presenting a 10-year-old girl; a known case with osteogenesis imperfecta (OI) type III without blue sclera and deafness since 9.5 years ago with repeated bone fractures from infancy, (Fig.1), and subsequent orthopedic interventions, (Fig.2).

**Correspondence:** Sh. Samangoeei, M.D. No 37, 1<sup>st</sup> street, Behrouz street, Mohseni Square, Mirdamad Blvd. Tehran, Iran. Tel: +9821-2278394. E-mail: samangoeei\_sh@yahoo.com

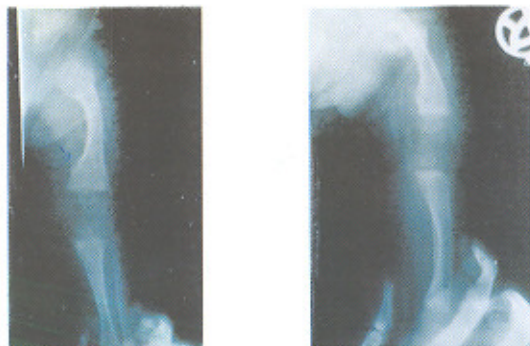


Figure 1: Radiographs illustrate the first two episodes of bone fractures in infancy.

kyphoscoliosis and short stature.<sup>3,5</sup> There was a negative family history for similar cases. Physical examination revealed a height of 110 cm, weight of 38 kg, normal teeth, and normal sclera without deafness. The diagnosis of OI was based on clinical findings and repeated laboratory work-ups including normal serum  $Ca^{2+}$  and  $PO_4^{3-}$ , normal levels of urinary calcium and phosphorous, normal ranges of serum alkaline phosphatase, serum parathyroid hormone and thyroid function tests.

Three years prior to admission, the patient developed recurrent oral ulcers, acne-form skin lesions, repeated attacks of genital ulceration and suffered anterior and posterior uveitis with retinal vasculitis in both eyes. She was HLA B51 positive, and pathergy test was negative. According to international diagnostic group criteria for Behçet's disease



Figure 3: The patient had repeated severe anterior uveitis in form of hypopyon (arrows).

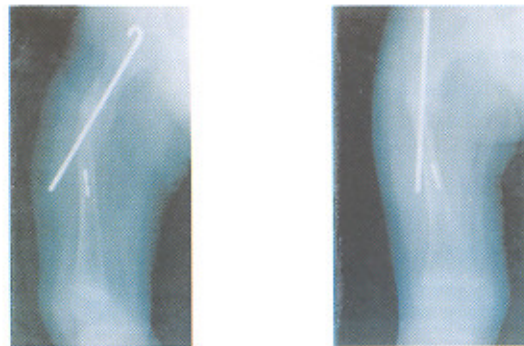


Figure 2: Orthopedic intervention for the management of repeated fracture.

BD, she was suffering from BD.<sup>5</sup>

Considering her bone disease, at that time, our first line of therapy for her severe uveitis was monthly pulses of IV cyclophosphamide 10 mg/kg/monthly plus, corticosteroid eye drops. Due to severe osteopenia no systemic corticosteroid was given initially. While she was in the third month of cyclophosphamide therapy, she developed repeated attacks of hypopyon (Fig. 3) in her left eye so that we were obliged to start systemic corticosteroids for her with calcium and vit. D and weight bearing exercise, the eye inflammation was continued, so we changed the eye treatments to cyclosporin 2.5 mg/kg/day, with methotrexate 5 mg im/week and corticosteroids first in high dose then with low dose according to severity of eye flare, was continued for another 12 months while she continued to have deterioration in her vision, recurrence of oral ulcer and genital lesion. At that time we discontinued her previous chemotherapy and it was replaced with chlorambucil (leukeran 0.2 mg/kg/day) with few courses of methyl prednisolon i.v pulses for the next 6 months. Despite of step wise aggressive different recommended chemotherapy for severe uveitis the eye inflammation was continuing and unfortunately she lost her visions in her both eyes after 6 months of last chemotherapies. Regarding treatment of (OI), no medical therapies have been demonstrated to alter the

growth, but recently it is shown that the intravenous administered biphosphonate pamidronate increased bone mass, and decreased fracture incidence in children with severe OI in age 3 to 15 year.<sup>6</sup> Surgical treatment is largely mechanical and directed toward preservation of function. The mainstays of care are active physical therapy and habilitation and appropriate orthopedic intervention that were performed in this patient previously.

### Conclusion

As far as we search in the medical literature, this patient is the first reported Behçet's disease patient associated with osteogenesis imperfecta.

### References

- 1 Sharpio JR: Heritable disorders of structural proteins. In: Shaun R, Harris ED JR, Sledge CB, eds. *Kelley's Text book of Rheumatology*. 6th ed. Philadelphia: W.B. Saunders, 2001:1438-44.
- 2 Byers PH: Osteogenesis imperfecta In: Royce PM, Steinmann B, eds. *Connective Tissue and Its Heritable Disorders: Molecular, Genetic, and Medical Aspects*. New York: Wiley-Liss (pub), 1993:317-50.
- 3 Kocher MS, Shapiro F: *J Am Acad Orthop Surg* 1998;6:342-5.
- 4 Davatchi F, Shahram F, Gharibdoost F, et al: Behçet's Disease: Analysis of 3,443 cases. *APLAR J Rheumatology* 1997;1:2-5.
- 5 The International Study Group for Behçet's Disease. Criteria for diagnosis of Behçet's disease. *Lancet* 1990;335:1078-80.
- 6 Glorieux FH, Bishop NJ, Plotkin H, et al: Cyclic administration of pamidronate in children with severe osteogenesis imperfecta. *N Engl J Med* 1998;339:947.