

Organizing Lobar Pneumonia: Report of a Case

M. Sokouti,* M. Milani,** V. Montazeri,***

Abstract

Organizing Lobar Pneumonia is a rare form of Bronchiolitis Obliterans Organizing Pneumonia. Herein, we report a rare case of organizing pneumonia involving lung, mediastinum and esophagus. A 16-year-old girl was referred to our center with clinical signs and symptoms of dysphagia and weight loss. The main abnormal radiologic and endoscopic findings were stricture of the lower third of esophagus and calcified lobar pneumonia of the lung. Pathologic examination of biopsies taken from esophageal stricture and resected lung revealed fibrosis and organizing lobar pneumonia. This combination, to our knowledge, has not been reported previously.

Iran J Med Sci 2003; 28(2):

Keywords • Pneumonia • esophageal stenosis • fibrosis • deglutition disorders.

Introduction

Bronchiolitis obliterans organizing pneumonia (BOOP) is a clinicopathological syndrome associated with a variety of disease entities.¹ Organizing Pneumonia (OP) was first recognized in 1982. The first report included 8 patients who presented with a short history of severe dyspnea, cough, malaise and weight loss associated with bilateral shadowing and raised ESR. In 1985 another group described an identical clinicopathologic disorder that was termed BOOP.² OP is a pathologic finding and nonspecific response common to various injuries to the lung of either definite or idiopathic etiology.³ It is classified into three clinical groups: (a) symptomatic (cryptogenic OP) (b) secondary (c) asymptomatic OP that presents as a focal nodule or solitary or rounded opacity.⁴ We describe the first case of Organizing Lobar Pneumonia with mediastinal, inferior pulmonary vein and esophageal involvement that produced severe dysphagia in a 16-year-old girl.

Case presentation

A 16-year-old girl was admitted to Imam Khomeini Hospital with a three-year history of dysphagia and weight loss. The patient had malaise, dysphagia and decreased pulmonary sounds in left lower hemithorax. She did not have any respiratory symptoms. Bronchoscopy was normal and BAL showed nothing. Chest x-ray showed calcification of the left lower lobe with mediastinal involvement. In esophagography a 4-5 cm long stricture was seen in the lower third of esophagus. (Fig 1) She had undergone two endoscopic examinations previously and pathologic examinations from stricture's site

*Department of Thoracic Surgery, Imam Khomeini Hospital, Tabriz University of Medical Sciences

**Department of Pathology Urmia University of Medical Science, Urmia, Iran

***Department Thoracic Surgery, Imam Khomeini Hospital.

Correspondence: M. Sokouti, M.D, Department of Thoracic Surgery, Imam Khomeini Hospital, Tabriz University

Tel: +98-411-3347054-58

E-mail: aaayda@hotmail.com

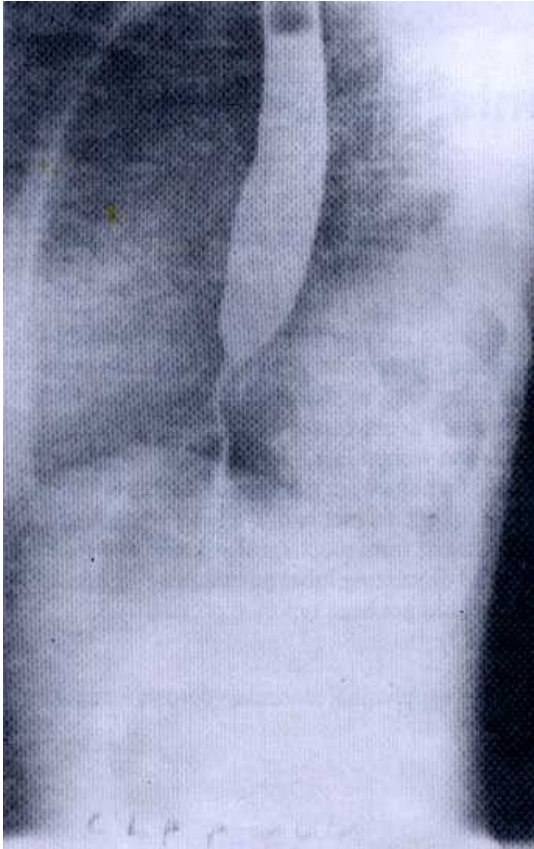


Figure 1: Organizing lobar pneumonia (Barium swallow and stricture of the lower third of esophagus)

had revealed fibrosis. ESR was elevated to 50 mm/h for the first and to 83 mm/h for the second hour.

We performed a left lower lobectomy and resection of mediastinal and esophageal fibrosis along with Heller myotomy of the esophagus to relieve the patient's dysphagia. Operative findings showed calcified organized lobar pneumonia, calcified inferior pulmonary vein and mediastinum, and fibrosis in the lower mediastinum encircling esophagus. Pathologic examination revealed organized lobar pneumonia with fibrosis of lung and mediastinum and inferior pulmonary vein. (Figs.2,3) Her dysphagia was relieved to some extent after lobectomy, however one year later she began to complain of dysphagia again. She underwent esophagoscopy biopsy, which revealed fibrosis. Esophageal dilatation was performed albeit of little benefit. One year later she was operated on, in another center. No resection was possible because of severe mediastinal and upper retroperito-

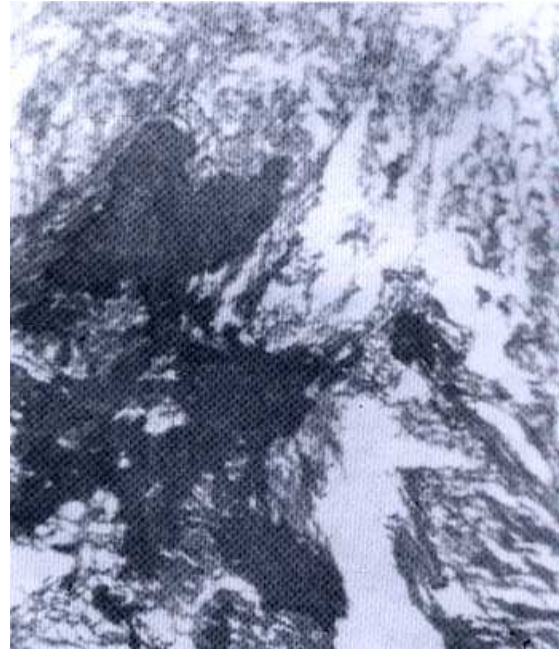


Figure 2: Organizing lobar pneumonia (Ossification) (10× 40 H&E)

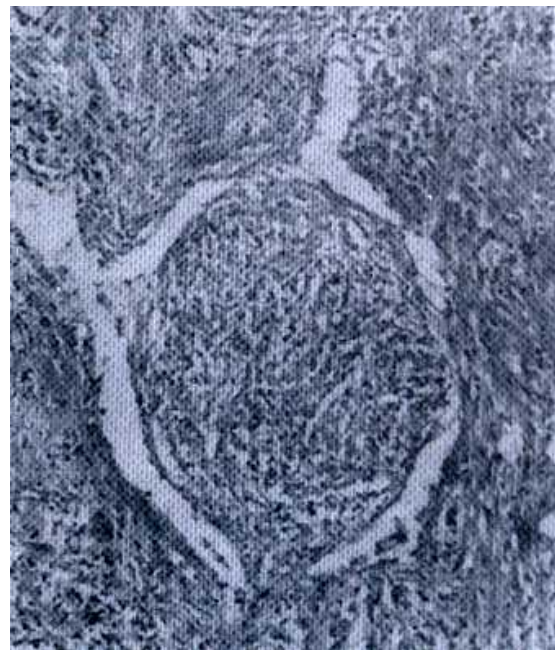


Figure 3: Organizing lobar pneumonia (Bronchiolitis Obliterans) (10× 40 H&E)

Organizing Lobar Pneumonia: Report of A rare case

neal fibrosis and adhesions. Numerous biopsies were taken, all revealed only fibrosis. A feeding jejunostomy was also done for her at the same time. She died 28 days after operation due to peritonitis, sepsis and severe malnutrition.

Discussion

Organizing Lobar Pneumonia has no symptoms and most of them are identified as a result of an incidental radiological finding. It has a good prognosis and seems to be a unique entity with differentiated characteristics.^{2,4} Sometimes the etiology is unknown while in other instances it can be seen in association with various specific inflammatory processes in the lung including granulomatous infection, pulmonary infections, aspiration pneumonia, bacterial infections, and hypersensitivity reactions. OP is diagnosed by lung biopsy, usually done to exclude malignant tumors, and no bacteria, fungi, or viruses are seen in the sputum. Bronchial alveolar washing is negative.³⁻⁵ Organizing pneumonia occurs as a nodule or mass ranging in size from 6 to 66 mm, with smooth, lobulated, spiculated margin. OP may simulate lung tumor with variable appearance on chest x ray and CT scan.^{5,6} Solitary pneumonia located in the upper lobes should be considered in the differential diagnosis of patients presenting with clinical and radiologic features of pulmonary tuberculosis.^{3,7} Evidence from studies using BAL and immunohistochemistry indicate that an autoimmune process has an important, though not clearly defined, role in initiating the disease.⁸ Interstitial fibrosis has been present in all reported cases. Pulmonary fibrosis with inflammatory cells may be present in the lumen of distal airspaces, alveoli, alveolar ducts, terminal and respiratory bronchioles and rarely arteriolar walls, which show intimal fibrosis, and muscular hypertrophy of the

media. Bronchiolar plugs, consist mainly of fibrin exudates undergoing organization.³

In our case a mass and organization of left lower lobe were seen with mediastinal and upper retroperitoneal involvement that produced severe dysphagia, being completely different from other cases reported hitherto.

References

- 1 Chang J, Han J, Kim DW, et al: Bronchiolitis obliterans organizing pneumonia: clinicopathologic review of a series of 45 Korean patients including rapidly progressive form. *J Korean Med Sci* 2002;**17(2)**:179-86.
- 2 Bronchiolitis obliterans organizing pneumonia. In: Fraser, Muller, Colman, Pare: *Diagnosis of Disease of the Chest*, 4th ed. Vol 3. Saunders. 1999: 2344-8.
- 3 Cordier JF, Loire R, Brune J: Idiopathic bronchiolitis obliterans organizing pneumonia: definition of characteristic clinical profiles in a series of 16 patients. *Chest* 1989;**96(5)**:999-1004.
- 4 Lohr RH, Boland BJ, Douglas WW, et al: Organizing pneumonia. Features and prognosis of cryptogenic, secondary, and focal variants. *Arch Intern Med* 1997;**157(12)**:1323-9.
- 5 Romero S, Baresso E, Aranda FI, et al: Organizing pneumonia adjacent to lung cancer : frequency and clinicopathologic features. *Lung Cancer* 2002;**35(2)**:195-201.
- 6 Yang PS, Lee KS, Han J, et al: Focal organizing pneumonia: CT and pathologic findings. *J Korean Med Sci* 2001;**16(5)**:573-8.
- 7 Heller J, Biner S, Isakov A, et al: TB or not TB: cavitary BOOP mimicking pulmonary tuberculosis. *Chest* 2001;**120(2)**:674-8.
- 8 Dunnhill Ms: Pulmonary fibrosis. *Histopathology* 1990;**16(4)**: 321-9.