

Nekam's Disease with Clinical Manifestation Simulating Darier's Disease: A Case Report

S. Shamsadini*, M. Hyatbakhsh
Abbasi**, M.H. Bagheri Kashani*

Abstract

Nekam's disease is a rare dermatosis characterized by a distinctive seborrheic dermatitis with prominent facial eruption. It is further associated with violaceous, papular, and/or nodular lesions on the extremities and trunk, typically arranged in a linear and reticulate pattern. Herein, describe a patient with Nekam's disease, which resembled Darier's disease in clinical manifestation. The patient responded partially to the treatment with oral isotretinoin.

Iran J Med Sci 2003; 28 (3):

Keywords • Nekam's disease • keratosis lichenoides chronica • Darier's disease

Introduction

Nekam's disease is a rare disorder, with only 50 cases reported in the world literature until 1998.¹⁻³ This disease was first described by Nekam in 1938.⁴ In recent years, the term has been commonly used to designate a condition previously referred to as lichen ruber acuminatus,⁴ or porokeratosis striata lichenoides of Nekam.^{4,5} This disorder is characterized by violaceous papular and nodular lesions which are often arranged in a linear and reticulate pattern on the dorsum of hands and feet, extremities, and buttocks. Seborrheic dermatitis-like scaling and telangiectasias of the scalp, face, and neck may also develop in this condition. Histologically, hyperkeratosis, parakeratosis, and hypergranulosis are seen. The epidermis is usually acanthotic, with mild liquefaction degeneration of basal keratinocytes. A band-like lymphocytic infiltrate with perivascular and periappendigeal involvement is present.¹⁻⁵

The more common Darier's disease (Darier-White disease, keratosis follicularis) is an autosomal dominant trait characterized by the eruption of keratotic papules in a seborrheic distribution. Involvement of flexures is seen in 80% of the patients. Virtually all patients have hand involvement, which includes nail dystrophy, palmar pits, and acrokeratoses. Darier's disease is characterized histologically by focal acantholytic dyskeratosis, in which suprabasal clefts lie beneath columns of acantholytic and dyskeratotic cells.⁶

Herein, we report on a patient with the typical histological features of Nekam's disease which clinically mimicked Darier's disease. The patient partially improved with isotretinoin therapy.

Case Presentation

A 42-year-old man presented with a 6-month history of asymptomatic

*Department of Dermatology, Kerman University of Medical Sciences

**Department of Internal Medicine, Kerman University of Medical Sciences

Correspondence: Shamsadini S, M.D, Department of Dermatology Afzalipoor Hospital Kerman Iran.
Tel: +98-0341 57272
E-mail: shamsadini@yahoo.com

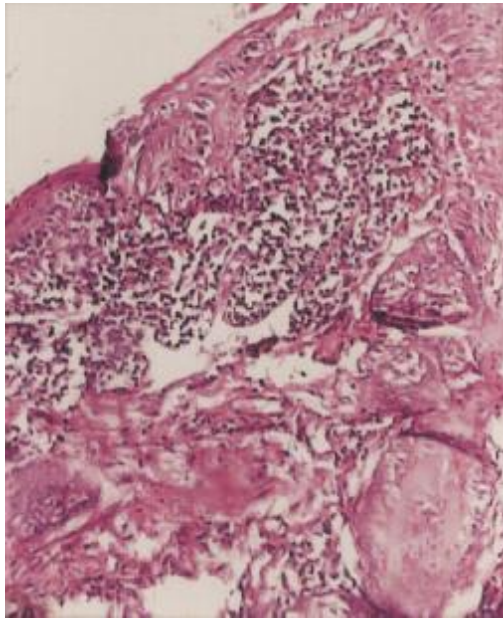


Figure 1: Pathological section of the skin lesion.

and widespread skin eruption that had appeared suddenly, first on his legs and later progressed to involve most of his trunk, upper and lower extremities, buttocks, and face. He was not taking any systemic medication. His family history was negative for a similar eruption. The lesions on the upper extremities and lower abdomen comprised lichenoid violaceous papules with a thin adherent keratotic plug arranged in a linear or reticular pattern. In addition, the lesions on the legs and buttocks and also in the popliteal areas coalesced into erythematous squamous or warty hyperkeratotic plaques. There were also pustule-like lesions on the forearms and legs. Marked diffuse hyperkeratosis was present on the plantar and lateral surfaces of both feet, along with warty lesions located in a linear configuration, on the periungual areas and to a lesser extent, on the volar and lateral aspects of the fingers and palms. Erythematous papules with greasy scaling and scattered papulopustules were present on the forearm and face. The scalp, hair, beard and mustache were affected with erythema and diffuse hair loss. The nails were involved in a pattern mimicking Darier's disease; showing distal fragility and wedge-shaped notching. Examination of the oral mucosa revealed erythematous papules with a rough surface and chronic severe erosions. A similar form of involvement was also observed on his genitalia. No significant alteration in the character of eruptions occurred upon exposure to sunlight; in fact, he felt that his lesions were more severe in

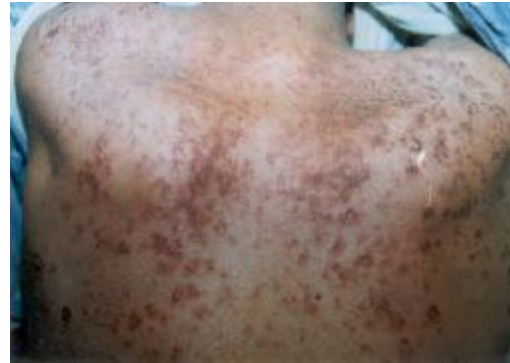

Figure 2: Porokeratotic lesion of the back skin.

winter. Examination of his joints was normal, although the patient complained of mild arthralgia in the ankles, knees and wrists. Ophthalmologic and neurological examinations were normal. No dental or bony abnormalities were observed. Complete blood count and differential leukocyte count, urinalysis, liver function tests, serum VDRL, chest and joint radiographs were all within normal limits or negative. Antinuclear antibody was not detected. Erythrocyte sedimentation rate was elevated (52 mm/hr) on one occasion and reverted to normal later on. Thyroid function tests showed no abnormalities. Three punch biopsy specimens from different skin lesions taken in three different dermatologic centers, revealed similar findings. Changes in the epidermis included irregular acanthosis, diffuse and follicular hyperkeratosis, spotty parakeratosis, and areas of mild liquefactive degeneration of the basal cells. The upper dermis contained a lichenoid infiltrate adherent to the epidermis. Histologically, it was composed of lymphocytes, histiocytes, plasma cells, and a few eosinophils. Perifollicular and perivascular infiltrates were also noted. No dyskeratotic cells and no follicular plugging were seen (Fig. 1). Initial, albeit, unsuccessful attempts to treat the lesions included topical application of keratolytics, corticosteroids and tar preparations. Treatment with isotretinoin, 40 mg daily, for 3 months resulted in mild improvement of lesions of the face and proximal limbs and significant improvement in the hands and feet. Three months after treatment, no more improvement was noticed, while the patient was still on the therapeutic regimen (Figs. 2, 3).

Discussion

Nekam's disease is considered by some to be a variant of lichen planus because of shared clinical and histologic features.⁷⁻⁹ However, a retrospective analysis of all published data suggests that

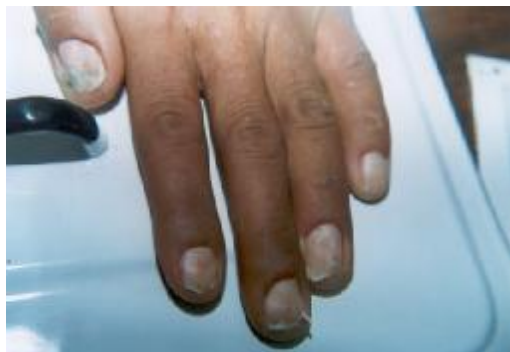

Figure 3: Nail notching with distal onycholysis and white and red bands.

Nekam's disease presents a unique clinical picture that helps distinguish these two entities.^{2,10} In our case, dirty papules on the chest associated with notching of the nails mimicked Darier's disease, but no dyskeratosis, follicular plugging, *corps ronds* or acantholysis were found in any of the three skin biopsies. The unusual combination of lichenoid keratotic papules arranged in plaques or in a characteristic linear/reticular pattern, together with an erythematous, scaly, midfacial eruption and palmo-plantar hyperkeratosis are adequate for the clinical diagnosis of Nekam's disease. Additional features that may occur less frequently include yellow discoloration of the nails,¹¹ nail dystrophies,^{2,3} oral, genital, and eye involvement (reviewed by Masouye and Saurat²), as well as the more rare nodular infiltration of the epiglottis, which may cause hoarseness. Other clinical features of Nekam's disease, also incompatible with a diagnosis of lichen planus, constitute resistance to systemic corticosteroid therapy and the absence of nail as well as the typical oral involvement. The eruption is usually asymptomatic, but in a few patients, it has been associated with severe pruritus. Systemic complaints are absent as a rule, as is any relationship to other diseases. Sclerodactyly was reported in a severe case of Nekam's disease with early onset.³ Reports of Nekam's disease are particularly rare in childhood,^{1,4,5,7} and no familial cases have been described. Although the course is chronic and progressive, a spontaneous resolution or remission, however has been reported in two cases.^{9,11} The histological features of Nekam's disease are variable and may also be found to some degree in other cutaneous disorders. However, the presence of parakeratosis and infiltration,

greater than that usually seen in lichen planus, may help in differentiation.⁸ Dyskeratosis, acantholysis, *corps ronds* and suprabasal cleft have not been reported in Nekam's disease. The disease is resistant to topical therapy, and most of case reports have confirmed the efficacy of systemic corticosteroid drugs, antimalarial agents, sulfones, gold, superficial x-ray therapy, and cyclosporin A. Although in some patients, PUVA^{9,10} and oral etretinate^{10,11} have induced a marked improvement, they have proved ineffective in others.^{3,11} In our patient, systemic therapy with dapsun (diaminodisulfone) was ineffective, while isotretinoin therapy led to partial improvement.

References

- 1 Nabai H, Mehregan AH: Keratosis lichenioides chronica. *J Am Acad Dermatol* 1980; **2(3)**:217-20.
- 2 Masouye I, Saurat JH: Keratosis lichenioides chronica: the centenary of another Kaposi's disease. *Dermatology* 1995; **191(3)**:188-92.
- 3 Van de Kerkhof PC: Spontaneous resolution of keratosis lichenoides chronica. *Dermatology* 1993; **187(3)**:200-4.
- 4 Nekam L: Sur la question du lichen moniliforme. *Presse Med* 1938; **51**:1000-3.
- 5 Kaposi M: Lichen tuber acuminatus et lichen tuber planus. *Arch Dermatol Syphilis (Berl)* 1895; **31**:1-32.
- 6 Dover JS: Pocket guide to cutaneous medicine and surgery, 1st ed, Philadelphia: Saunders, 1996: 645.
- 7 Petroszi JW: Keratosis lichenoides chronica: possible variant of lichen planus. *Arch Dermatol* 1976; **112(5)**:709-11.
- 8 Kersey P, Ivey FA: Keratosis lichenoides chronica is synonymous with lichen planus. *Clin Exp Dermatol* 1982; **7(1)**:49-54.
- 9 Braun-Falco O, Bieber T, Heider L: Chronic lichenoid keratosis: disease variant or disease entity? *Hautarzt* 1989; **40**:614-22.
- 10 Mehregan AH, Heath LE, Pinkus H: Lichen ruber moniliformis and lichen ruber verrucosus et reticularis kaposi. *J Cutan Pathol* 1984; **11(1)**:2-11.
- 11 Baran R, Pannizon R, Goldberg L: The nails in keratosis lichenoides chronica: characteristics and responses to treatment. *Arch Dermatol* 1984; **120(11)**:1471-4.