

T-Condylar Fracture of Distal humerus in 5-year-Old Child

E. Hasankhani

Abstract

T-Condylar fracture of the distal humerus is rare in the skeletally immature children and is very rare in young children, under 9 years of age. This fracture has been classified as: type A (minimally displaced or undisplaced), type B (displaced but not comminuted) and type C (displaced and comminuted). Herein, we report a T-Condylar fracture of the distal humerus in a 5-yr-old boy. This fracture was diagnosed by plain radiography, and was treated by open reduction and internal fixation, as a type B T-Condylar fracture of distal humerus.

Iran J Med Sci 2004; 195-197.

Keywords • T-Condylar • Fracture • Distal humerus • Children.

Introduction

T-Condylar fracture of the distal humerus is rare in skeletally immature children.^{1,2,5,7} The average age of patients reported in various studies is 11 years.^{2,4,5} The actual incidence of T-Condylar fracture of distal humerus in children aged under 10-years is very rare because it is either underdiagnosed or confused with other fractures of the distal humerus.^{1,2} This is specially through in type A fracture (minimally displaced or unplaced) because it is not diagnosed by plain radiography.

Case presentation

A 5-yr-old boy, who had elbow trauma with pain, swelling and joint dysfunction was admitted to the orthopedic department of Shahid Khamiab hospital, affiliated to Mashhad University of Medical Sciences, Mashhad Iran. Roentgenogram showed a displaced T-Condylar fracture of distal humerus (Fig 1A) and since closed reduction was not successful the patient underwent an open reduction and internal fixation. The fracture was exposed with posterior approach without osteotomy of the olecranon. It was a type B T-Condylar fracture (displaced but not comminuted). Open reduction and internal fixation was performed. First the articular surface was reconstructed to convert the T-Condylar fracture to a supracondylar fracture. After reestablishment of the articular integrity with three kirschner wires the distal fragments were secured to the proximal fragment, as a supracondylar fracture with two other kirschner wires (Fig 1B).

Discussion

T-Condylar fracture of the distal humerus is very rare in young children.^{1,2,5,6} Most reported cases so far have shown the age of

Department of orthopedic & spine surgery, Shahid Kamiab Hospital
Mashhad University of Medical Sciences
Mashhad, Iran

Correspondence:

Ebrahim Gh Hasankhani MD
Department of orthopedic & spine surgery, Shahid Kamiab Hospital,
Mashhad University of Medical Sciences
Mashhad Iran

Tel: +985116061281

Fax: +985118549234

E-mail: eghasankhani@yahoo.com

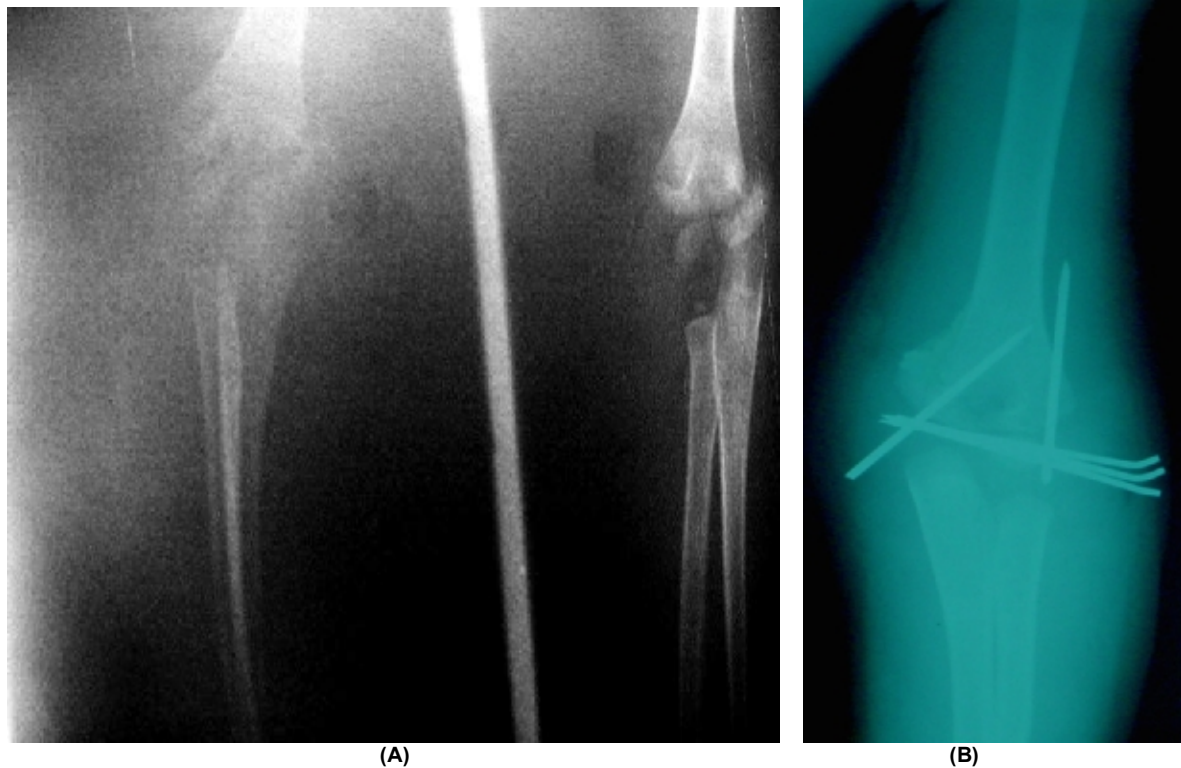


Fig 1: (A) a 5-years-old boy with intercondylar (T-condylar) fracture of the distal humerus. (B) x-ray control after open reduction and internal fixation.

patients over 9 years,^{2,4,6} and only in tow reports the age of patients were under 9-years.¹

This fracture in younger children is always clinically confused with supracondylar fracture, and plain radiography, also, has not much practical value because the articular surface is not visible, particularly when the fracture is not displaced.² This case was diagnosed with plain radiography because of significant displacement. C.T Scan and specially M.R.I are not tolerated by younger children and their volubility is in question,² and because of these difficulties, the T-Condylar fracture of distal humerus may be underdiagnosed.

Kanellopoulos et al. have reported closed reduction and percutaneous stabilization for T-Condylar fractures of distal humerus in children above 9 years old,⁹ whereas, in this case the closed reduction was not successful and we were obliged to open reduction and internal fixation. There are many studies about the methods of surgical exposure of the elbow fractures. Kasser et al. and Schemitsch et al. believe that the best approach for exposure of this fracture is the posterior longitudinal splitting of the triceps without osteotomy of the olecranon.^{3,8} Therefore, we had to use the triceps-dividing approach for open reduction and internal fixation.

Conclusion

This case was reported because, the T-Condylar fracture of the distal humerus is very rare in children under 9 years age, particularly the type B T-Condylar fracture that open reduction and internal fixation is necessary, has not been reported up to now.

References

- 1 Beghin JL, Bucholz RW, Wenger DR. InterCondylar Fractures of the humerus in young children, *JBJS (Am)* 1982; **64**: 1083-7.
- 2 Charles A, Rockwood, JR, MD: Fracture in children. 5thed. Philadelphia: Lippincott-Raven Co, 2001: 687-98.
- 3 Kasser JR, Richards K, Millis M. The triceps-dividing approach to open reduction of complex distal humerus fractures in adolescents: a cybex evaluation of triceps function and motion. *J Pediatr Orthop* 1990; **10**: 93-6.
- 4 Jarvis JG, D, Astous JL. The pediatric T-supracondylar fractures. *J Pediatr Orthop* 1984; **4**: 697-9.
- 5 Mihrano Tachdjian: Pediatric Orthopedics. 3d ed. Philadelphia: W.B. Saunders Co, 2002: 2202-3.

T-Condylar fracture of distal humerus

- 6 Papvasiliou VA, Beslikas TA. T-Condylar fractures of the distal humeral Condyles during childhood: An analysis of six cases. *J Pediatr Orthop* 1986; **6**: 300-3.
- 7 Re PR, Waters PM, Hresko T. T-Condylar fractures of the distal humerus in children and adolescents. *J Pediatr Orthop* 1999; **19**: 313-9.
- 8 Schemitsch EH, Tencer AF, Henley MB. Biomechanical evaluation of methods of internal fixation of the distal humerus. *Journal of orthop trauma* 1994; **8**: 468-75.
- 9 Kanellopoulos, Anastasios D. Yiannakopoulos, Christos K MD. Closed reduction and percutaneous stabilization of pediatric T-Condylar fractures of the humerus. *J Pediatr Orthop* 2004; **24**: 13-6.