

# Free Perforation of Sigmoid Colon Secondary to Invasive Mucormycosis in a Critically Ill Patient

R. Farhadieh, A. Salardini<sup>1</sup>

## Abstract

Mucormycosis is a clinical entity attributed to opportunistic fungal infection of order Mucorales. This includes several pathogenic subtypes. It commonly affects the rhinocerebral sites and the immunocompromized patients with devastating results. Visceral mucormycosis is a relatively rare complication. We report the first free sigmoid colon perforation secondary to invasive mucormycosis and discuss the risk factors, methods of diagnosis, and pathogenesis of this clinical entity.

**Iran J Med Sci 2008; 33(3): 180-182.**

**Keywords** • Mucormycosis • colon • perforation • immunosuppression

## Introduction

**M**ucormycosis is a rare opportunistic fungal infection of order Mucorales. It is characteristically present in rhinocerebrum or cutaneous sites and afflicts immunocompromized patients.<sup>1-3</sup> Reports of visceral mucormycosis affecting the gastrointestinal tract are rare.<sup>4</sup> After aspergillosis, mucormycosis is the second most common mycosis caused by filamentous fungi.<sup>2</sup> We report the first case of free perforation of the sigmoid colon secondary to invasive mucormycosis in a critically ill patient.

## Case History

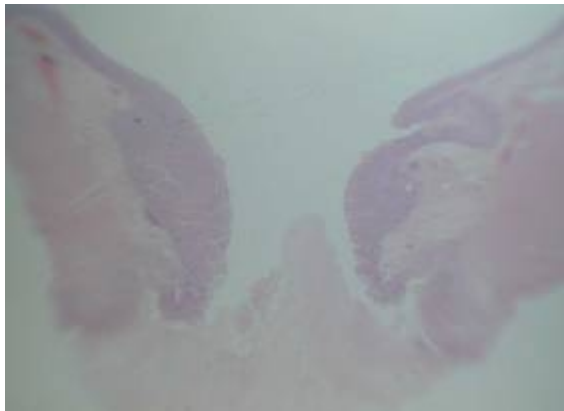
A 52-year-old man presented to the emergency department of a local hospital with a one-week history of worsening shortness of breath, on a background of chronic alcohol abuse and IgA deficiency, diagnosed following recurrent juvenile infections. He required respiratory support at the presentation, including an emergency tracheostomy before being transferred to the intensive care unit (ICU) at Prince of Wales Hospital, Australia. On admission to the ICU, bilateral pneumonia on imaging and secondary streptococcal sepsis on blood cultures were confirmed. Subsequent multi-organ failure ensued with acute renal failure. A subendocardial myocardial infarction (MI) and rapid atrial fibrillation (AF) further complicated the clinical scenario. He improved with supportive therapy and intravenous ceftriaxone (2 g/daily). On day 12 the patient clinically deteriorated with increased requirements for respiratory and cardiovascular support. His abdomen became distended. At this time a computed tomography (CT) scan of the abdomen was performed that demonstrated free gas in the peritoneal cavity. He was taken to the operating theatre. At operation, perforation of the sigmoid colon with fecal peritonitis was noted. Hartmann's procedure was performed.

Plastic and Reconstructive Surgery  
Registrar  
St Vincent's Hospital  
Melbourne, Australia.  
<sup>1</sup>Post Doctoral Research Fellow  
Yale University, USA.

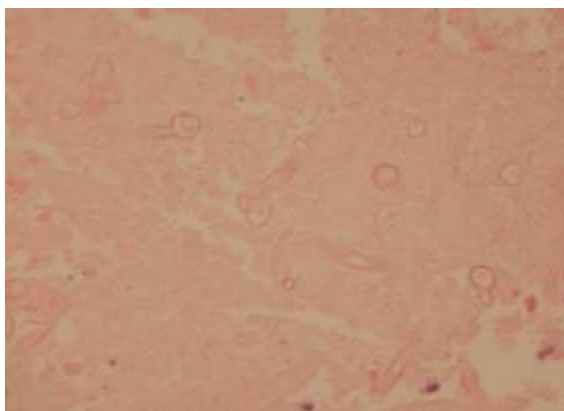
### Correspondence:

Rostam Farhadieh BSc(Med)  
Hons MB BS  
Plastic and Reconstructive Surgery  
Registrar  
St Vincent's Hospital  
Melbourne, Australia.  
**Tel:** +61 2 93822595  
**Fax:** +61 2 93822550  
**Email:** rostam74@yahoo.com.au  
Submitted: 3 September 2007  
Accepted: 4 August 2008

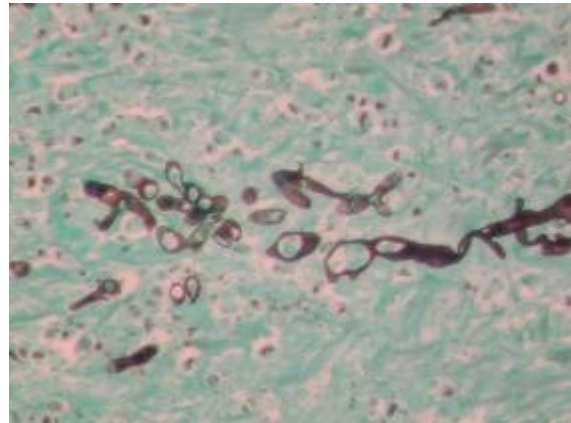
Pathological assessment of the resected bowel macroscopically demonstrated three small adjacent areas of infarction with perforation of one. No evidence of diverticular disease or other possible causes of perforation were noted. Microscopically, at all the three sites of infarction, non-septate, right angled branching filamentous fungi with a propensity for perivascular and intravascular distribution were noted. The diagnosis of invasive mucormycosis was made on the basis of these unique histopathological features (figs 1-3). Intravenous antifungal treatment was commenced with liposomal amphotericin (250 mg/d). The patient's post-operative course was protracted by surgical and medical complications. The most significant of these included a colonic bleed on day 12 post-operatively. This was isolated to a branch of the left colic artery and embolized in the angiography suite. Intermittent sepsis and two further episodes of rapid AF and subendocardial MI were amongst the other complications. By day 56 after his initial presentation all antifungal and antibacterial medications had been ceased and the patient was ready for discharge to a rehabilitation unit.



**Figure 1:** Section stained with periodic acid-Schiff demonstrating the site of perforation in the colon wall. ×10 Magnification.



**Figure 2:** Hematoxylin and eosin staining demonstrates the junction of infarcted and normal bowel tissue in the presence of fungal bodies on the infarcted side. ×125 Magnification.



**Figure 3:** Gomori methenamine-silver nitrate staining. ×125 Magnification.

## Discussion

Among the order Mucorales responsible for the clinical entity of mucormycosis; *Rhizopus*, *Absidia*, *Rhizomucor*, and *Mucor* are most commonly isolated from the clinical specimens. They all belong to the family Mucoraceae. These filamentous fungi are ubiquitous and are found in soil, plants, manure, and decaying material. Rhinocerebral mucormycosis is the most common manifestation of infection with this organism, and is classically associated with ketoacidosis.<sup>5</sup> Other clinical manifestations include pulmonary, cutaneous, and disseminated mucormycosis.

Mucormycosis of the gastrointestinal tract is extremely rare. It occurs in malnourished and immunosuppressed individuals and is much more common in the pediatric population, especially amongst premature neonates.<sup>6</sup> In this patient group, the mechanism of entry is thought to be ingestion. The most common gastrointestinal sites of involvement are the stomach, the ileum and the colon. Previous reports of necrotizing enterocolitis have been almost exclusively reported in premature neonates and less commonly in immunocompromized adults.<sup>7-10</sup> These adults were neutropenic, post-transplantation, and in two cases immunosuppressed because of acquired immunodeficiency syndrome (AIDS), and systemic lupus erythematosus (SLE) respectively.<sup>11-14</sup>

The current understanding of the mature host-pathogen interaction in mucormycosis places primary emphasis on phagocytosis as the main host defense against this fungus. The main susceptibility variables in this model include high levels of iron and acidity as well as the impairment of phagocytosis; often in the context of neutropenia or white cell dysfunction.<sup>15</sup> Our patient had a number of these risk factors including acidosis and possible white cell dysfunction secondary to systemic inflammatory response syndrome. Furthermore,

there are reported links between hypogammaglobulinemia and mucormycosis in two published case reports presenting in the rhinocerebrum and the lung.<sup>16,17</sup> Our case shows a similar coincidence of immunoglobulin deficiency and gastrointestinal mucormycosis. These observations may suggest an important role for immunoglobulins especially IgA in the body's anti-mucormycosis defenses.

Due to the rarity of mucormycosis, there is a conspicuous absence of clinical trials to guide the clinicians in their task. Our patient received liposomal amphotericin B, in part because of its better side effect profile with regards to kidney function and electrolyte abnormalities. Reversal of the underlying predisposing factors such as acidosis and hyperglycemia were also thought to aid the resolution of the infection. Time is of the essence in the treatment of mucormycosis. Perforation in this patient proved fortuitous as the surgical resection inevitably leads to the early surgical debridement of the infected tissue.

This is the first reported case of free colonic perforation secondary to invasive mucormycosis in the adult population. Previous reports of mucormycosis associated bowel perforation in the pediatric population have unfortunately been associated with high mortality. Due to the absence of reliable serological markers and difficulties in culturing the organism, the diagnosis of mucormycosis is often made by histopathology on the resected tissue or during postmortem.<sup>2</sup> Here we argue that the diagnosis of mucormycosis should be entertained, after more common pathologies are ruled out, in the immunosuppressed patients with acute abdomen, as to facilitate the early initiation of surgical intervention and antifungal treatment.

**Conflict of Interest:** None declared

## References

- 1 Jiménez C, Lumbreras C, Aguado JM, et al. Successful treatment of mucor infection after liver or pancreas-kidney transplantation. *Transplantation* 2002; 73: 476-80.
- 2 Eucker J, Sezer O, Graf B, Possinger K. Mucormycoses. *Mycoses* 2001; 44: 253-60.
- 3 Nosari A, Oreste P, Montillo M, et al. Mucormycosis in hematologic malignancies: an emerging fungal infection. *Haematologica* 2000; 85: 1068-71.
- 4 Thomson SR, Bade PG, Taams M, Chrystal V. Gastrointestinal mucormycosis. *Br J Surg* 1991; 78: 952-4.
- 5 Pillsbury HC, Fischer ND. Rhinocerebral mucormycosis. *Arch Otolaryngol* 1977; 103: 600-4.
- 6 Kecskes S, Reynolds G, Bennett G. Survival after gastrointestinal mucormycosis in a neonate. *J Paediatr. Child Health* 1997; 33: 356-9.
- 7 Diven SC, Angel CA, Hawkins HK, et al. Intestinal zygomycosis due to *Absidia corymbifera* mimicking necrotizing enterocolitis in a preterm neonate. *J Perinatol* 2004; 24: 794-6.
- 8 Nissen MD, Jana AK, Cole MJ, et al. Gilbert. Neonatal gastrointestinal mucormycosis mimicking necrotizing enterocolitis. *Acta Paediatr* 1999; 88: 1290-3.
- 9 Reimund E, Ramos A. Disseminated neonatal gastrointestinal mucormycosis: a case report and review of the literature. *Pediatr Pathol* 1994; 14: 385-9.
- 10 Siu KL, Lee WH. A rare cause of intestinal perforation in an extreme low birth weight infant-gastrointestinal mucormycosis: a case report. *J. Perinatol* 2004; 24:319-21.
- 11 Suh IW, Park CS, Lee MS, et al. Hepatic and small bowel mucormycosis after chemotherapy in a patient with acute lymphocytic leukemia. *J Korean Med Sci* 2000; 15: 351-4.
- 12 Vadeboncoeur C, Walton JM, Raisen J, et al. Gastrointestinal mucormycosis causing an acute abdomen in the immunocompromised pediatric patient-three cases. *J Pediatr Surg* 1994; 29: 1248-9.
- 13 Brullet E, Andreu X, Elias J, et al. Gastric mucormycosis in a patient with acquired immunodeficiency syndrome. *Gastrointestinal Endosc* 1993; 39: 106-7.
- 14 Hosseini M, Lee J. Gastrointestinal mucormycosis mimicking ischemic colitis in a patient with systemic lupus erythematosus. *Am J Gastroenterol* 1998; 93: 1360-2.
- 15 Spellberg BJ, Edwards K, Ibrahim A. Novel perspectives on mucormycosis: pathophysiology, presentation and management. *Clin. Microbiol Rev* 2005; 18: 556-69.
- 16 Yagihashi S, Watanabe K, Nagai K, Okudaira M. Pulmonary mucormycosis presenting as massive fatal hemoptysis in a hemodialytic patient with chronic renal failure. *Klin Wochenschr* 1991; 69: 224-7.
- 17 D.R. Doshi, E. Lu, Z.K. Ballas. NK cell dysfunction and hypogammaglobulinemia in a patient presenting with invasive rhinocerebral mucormycosis. *Journal of Allergy and Clinical Immunology*, 2004; 113: S128.