

Langerhans Cells in Skin Lesions of Leprosy

B. Azadeh¹, S. Dabiri²

Abstract

Background: Langerhans cells are important in the pathogenesis of leprosy. A recent study reported that these cells were almost absent in the epidermis overlying lepromatous lesions.

Objective: To investigate a possible relationship between the number of Langerhans cells and the histopathologic spectrum of lesions in patients with leprosy.

Methods: An immunohistochemical staining for S100 protein was used to study skin punch biopsies of patients with leprosy and to quantify S100-positive Langerhans cells in the epidermis.

Results: A progressively significant reduction in the number of Langerhans cells was found from tuberculoid to lepromatous skin lesions. Langerhans cells were significantly less frequent in lepromatous and borderline lepromatous as compared to either tuberculoid or borderline tuberculoid leprosy.

Conclusion: In view of the fact that adequate numbers of dendritic cells are recruited to the dermis, their maturation/migration to Langerhans cells in the epidermis is impaired in lepromatous leprosy.

Iran J Med Sci 2004; 29(2):51-55.

Keywords • Langerhans cells • dendritic cells • leprosy

Introduction:

Infection by the intracellular organism, *Mycobacterium leprae* leads to host immune responses, which range from apparently none (anergy) to severe reactions, resulting in a spectrum of clinicopathologic manifestations in leprosy.

Categories defined in this spectrum include polar lepromatous (LL), borderline lepromatous (BL), borderline tuberculoid (BT) and polar tuberculoid (TT). Tuberculoid leprosy indicates a strong T-cell immune response, activation of macrophages and few organisms in the tissue. The LL, at one end of the spectrum, is characterized by a markedly depressed cellular immune response with anergy to the lepromin test antigen (Mitsuda-negative reaction), numerous bacilli in the lesions forming globi in the diffuse foamy macrophages, giant cells with absence of epithelioid granulomata and rare T-lymphocytes.^{1,2} In the light of recent understanding of the nature of cellular immunity in such a response, it is now possible to delineate pathways involved in the pathogenesis of leprosy. The professional antigen-presenting cells in the skin, Langerhans cells and dermal dendritic cells, are important contributors

Departments of Pathology,

¹The Liverpool University,
Liverpool, UK and

²Kerman University of Medical Sciences,
Kerman, Iran

Correspondence: B. Azadeh, MD,
Department of Pathology,
Duncan building (5th Floor),
Royal Liverpool University Hospital,
Daulby Street Liverpool L69 3GA UK
Tel: +44151 7064456
Fax: +44151 7065859
E-mail: bazadeh@liv.ac.uk

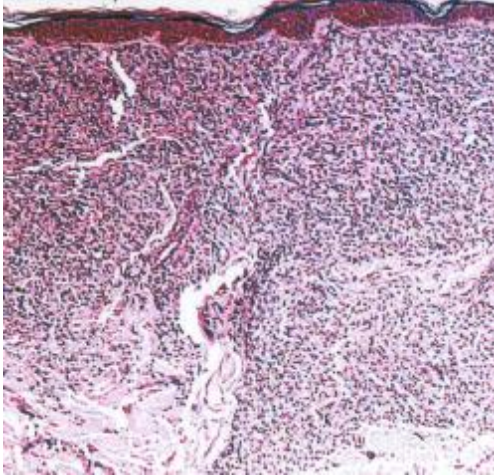


Fig 1: Lepromatous leprosy; inflammatory cells have diffusely infiltrated the dermis (hematoxylin and eosin).

to the ongoing immune responses through a battery of cellular and humoral interactions.^{3,4} In this article we report quantification of Langerhans cells in skin biopsies in leprosy using immunostaining for S-100 protein.

Materials and Methods

Samples

This study used formalin-fixed paraffin-embedded blocks of skin punch biopsies from the files of the Department of Pathology, Hamad Medical Corporation, Doha, Qatar, taken from 78 cases of leprosy visited in the period 1982–89. Biopsies without surface epithelium, or those consisting primarily of nerve and soft tissue were excluded. Clinicopathological features have been described elsewhere.⁵

Histopathologic diagnosis

hematoxylin-eosin stained sections were reviewed and the lesions were categorized into LL, BL, BT, and TT according to Ridley and Jopling's criteria.¹ Sections were stained by both Ziehl-Neelsen and Fites methods for detection of mycobacteria.

Immunohistochemistry

Sections were stained with polyclonal rabbit anti-S-100 protein antibody (DAKO, Carpinteria, CA) followed by secondary biotinylated goat anti-rabbit serum and avidin-biotin-peroxidase complex. Diaminobenzidine was used as the chromogen.

Quantification of epidermal Langerhans cells

All S100-positive dendritic cells in the epidermis and in hair follicles were considered to

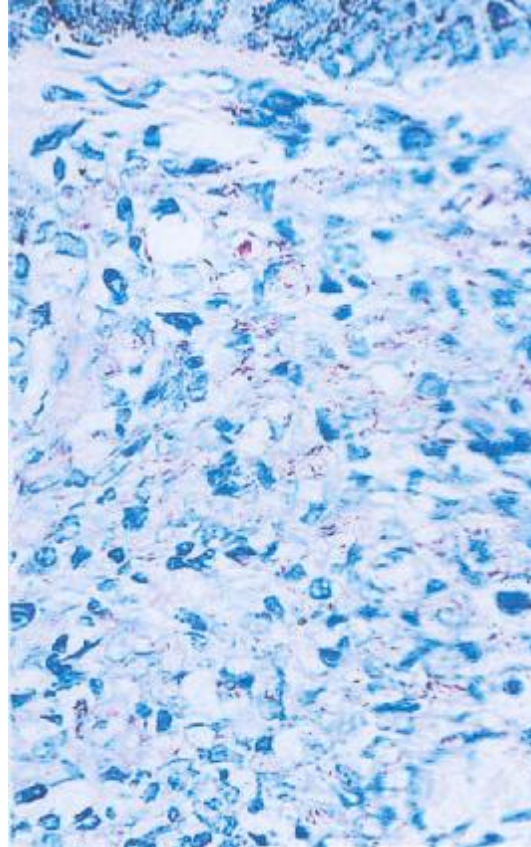


Fig 2: Globi of *M. leprae* in macrophages in lepromatous leprosy (Fite stain).

be Langerhans cells. Langerhans cells were counted in the epidermis in each half of a bisected skin punch biopsy and the result was divided by the maximum length of the epidermis. The Langerhans cell index for each case was the average of the counts in both halves of the biopsy expressed per linear millimeter of the epidermis.¹ Any positive cells present in the basal layer were not counted since there were very few dendritic cells in this region and the anti-S100 stain did not allow distinction between Langerhans cells and melanocytes. In the dermis it was not possible to differentiate dermal dendrocytes from Langerhans cells trafficking from the epidermis into the dermis. All S100- positive dendritic cells in the dermis were given a score of 1+ to 3+. The mean Langerhans cell index and dermal dendritic cell score for each category of leprosy was calculated by the sum of counts divided by the number of biopsies in that group. Although, strictly speaking, Langerhans cells should be identified ultrastructurally by their contents of Birbeck granules, our methods, in the context used, produces values, which are valid for comparing groups of skin lesions.

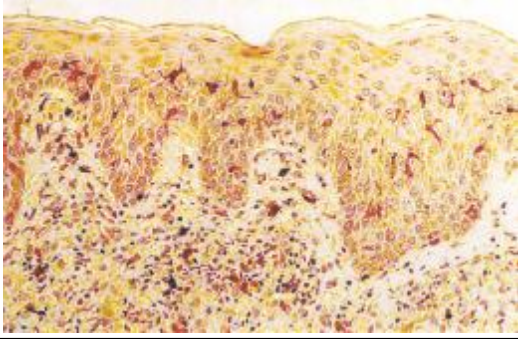


Fig 3: Numerous Langerhans cells in the epidermis in borderline tuberculoid leprosy (immunostaining for S100 protein).

Statistical analysis

Two-tailed Student's *t* tests were used to compare means between groups.

Results

More than 75% of the patients were from Indian subcontinent. Eighty-five percent were men. The mean age was 33.5 years for males and 32.9 years for females.

In lepromatous leprosy, the macrophages formed an extensive and diffuse infiltrate in the dermis (Fig. 1) and bacilli were abundant (Fig. 2). Langerhans cell densities in each biopsy were evaluated in the epidermis and in the hair follicles. The number of Langerhans cells in the hair follicles was generally comparable to that seen in the epidermis (Figs. 3, 4, 5), but the cells were more frequent at the junctions of the epidermis and hair follicles which were probably more vulnerable to antigen entry. On the other hand, dermal dendritic cells were abundant among inflammatory cellular infiltrates in the upper dermis, progressively decreasing in number towards the deep dermal layers. Dermal dendritic cells were rare in apparently adjacent normal adjacent dermis that did not contain inflammatory cellular infiltrates.

Results of quantitation of Langerhans cells in epidermis relative to histopathological subtypes of leprosy are shown in Figure 6. Langerhans cells were significantly less frequent in LL (1.76 ± 1.3) and BL (2.8 ± 2.09) as compared to either TT (4.58 ± 2.54) or BT (6.48 ± 3.76) ($p < 0.05$). There were no statistically significant differences in the numbers of Langerhans cells between BT and TT or between BL and LL. Mean scores for dermal dendritic cells were: LL 2, BL 1.9, BT 2.4, and TT 2.1.

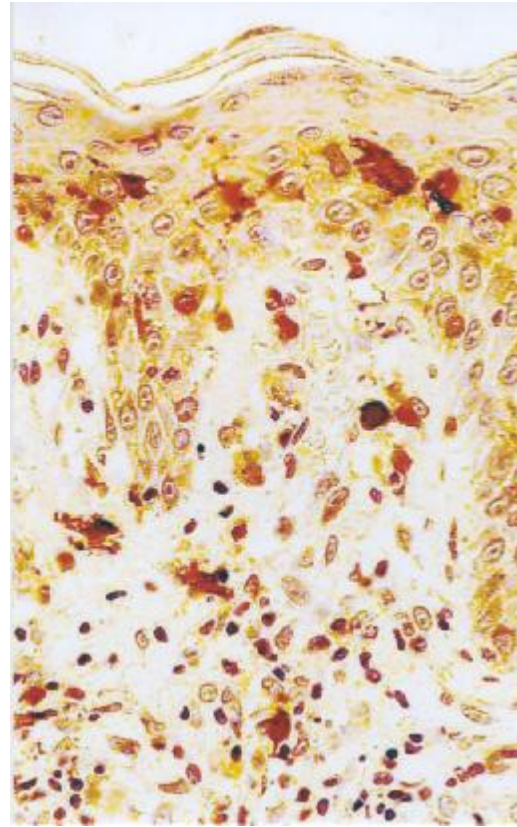


Fig 4: Dendritic processes of the Langerhans cells are extended to the intercellular spaces in close association with epidermal keratinocytes (immunostaining for S100 protein).

Discussion

Leprosy has a spectrum of clinical and histopathologic manifestations that is believed to be the result of cellular immune responses to intracellular *M. leprae*. Interactions between various cellular elements in these circuits result in interchangeable histopathologic pictures depending on the predominance of an effector pathway.⁷⁻¹⁴ It has been shown that antigen-presenting cells, depending on their numbers and types, are able to direct the effector mechanisms towards specific T helper responses.^{17,18} In addition, as a result of such interactions, recruitment and thus the number of antigen-presenting cells is affected by the predominant type of effector cells present in an inflammatory response. We have shown a significant reduction in the number of Langerhans cells in lepromatous leprosy compared to tuberculoid leprosy. Other workers have described similar findings. A recent study reported that Langerhans cells were almost absent in the epidermis overlying lepromatous lesions.¹⁵ An earlier study used a histochemical staining technique of ATPase for identifica-

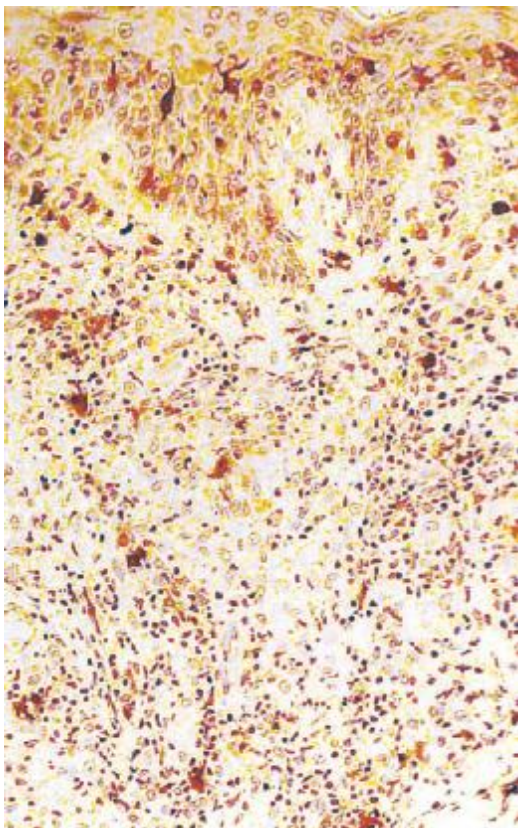


Fig 5: Dendritic cells in the dermis scattered around the peripheries of the granuloma in borderline tuberculoid leprosy (immunostaining for S100 protein).

tion of Langerhans cells in epidermal sheets separated from frozen skin biopsies. They also showed a marked reduction in the number of Langerhans cells in the epidermis of patients with lepromatous leprosy regardless of whether the biopsy specimen was taken from involved or uninvolved skin.¹⁶ These findings are probably due to the combined primary alteration of Langerhans cells by *M. leprae* and the secondary recruitment of the cells by ongoing T helper responses. It is likely that strong Th1 cellular responses result in recruitment of Langerhans cells to the site of skin lesions in tuberculoid leprosy. On the other hand, Th2 helper cells not only counteract this phenomenon but also suppress activation of Langerhans cells and down-regulate the activity of Th1 helper cells in lepromatous leprosy. Although dendritic cells in the dermis generally had higher scores in BT, there were no statistically significant differences in mean scores observed in the various forms of leprosy. This may further support the view that dendritic cells are recruited in adequate numbers but the maturation/migration to Langerhans cells in

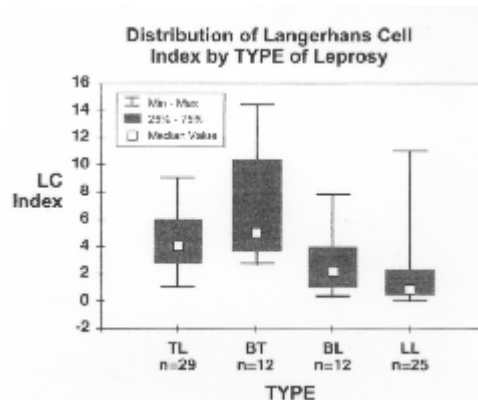


Fig 6: Comparison of Langerhans cell (LC) index between histopathologic types of leprosy. TL = tuberculoid leprosy, BT = borderline tuberculoid, BL = borderline lepromatous, LL = lepromatous leprosy.

the epidermis is impaired in lepromatous leprosy. It is hoped that further studies on specific markers (such as Langerin and CD1a) and activators of dendritic cells/Langerhans cells will elucidate the co-stimulatory role of these cells in the progression of skin lesions in leprosy.

References

- 1 Ridley DS and Jopling WH. Histologic classification and immunologic spectrum of leprosy. *Bull WHO* 1974; **51**: 451-465.
- 2 Abulafia J and Vignale RA. Leprosy: pathogenesis updated. *Int J Dermatol* 1999; **38**: 321-34.
- 3 Bauer J, Bahmer FA, Worl J, et al. A striking constant ratio exists between Langerhans cells and other epidermal cells in human skin. A stereological study using the optical disector method and the confocal laser scanning microscope. *J Invest Dermatol* 2001; **116**: 313-318.
- 4 Pieri L, Domenici L, Romagnoli P. Langerhans cells differentiation: a three-act play. *Ital J Anat Embryol* 2001; **106**: 47-69.
- 5 Mahmood SF, Azadeh B. Leprosy in Qatar. *Int J Dermatol* 1991; **30**: 125-126.
- 6 Prieto VG, Sadick NS and McNutt NS. Quantitative immunohistochemical differences in Langerhans cells in dermatitis due to internal versus external antigen sources. *J Cutan Pathol* 1998; **25**: 301-10.
- 7 Narayanan RB, Girdhar BK, Lavania RK, et al. In vitro studies on dermal granulomas of human leprosy: characterization of cells using monoclonal antibodies. *Int J Lepr Other Mycobact Dis* 1986; **54**: 268-72.

- 8 Yamamura M, Uyemura K, Deans RJ, et al. Defining protective responses to pathogens: cytokine profiles in leprosy lesions. *Science* 1991; **254**: 277-9.
- 9 Sehgal VN, Joginder, Sharma VK. Immunology of leprosy. A comprehensive survey. *Int J Dermatol* 1989; **28**: 574-84.
- 10 Kaplan G. The efficacy of a cell-mediated reaction in the disposal of *M. leprae* in human skin. *Immunol Lett* 1988; **19**: 223-7.
- 11 Damasco MH, Sarno EN, Lobao AS, et al. Effect of cutaneous cell-mediated immune response to rIFN gamma on mycobacterium. *leprae* viability in the lesions of lepromatous leprosy. *Braz J Med Biol Res* 1992; **25**: 457-65.
- 12 Modlin RL. Th1- Th2 paradigm: insights from leprosy. *J Invest Dermatol* 1994; **102**: 828-32.
- 13 Sehgal VN, Gupta RP, Kramakar S, et al. In situ characterisation of lymphocytic immunophenotypes and interleukin-2 receptors in cutaneous tuberculosis and leprosy: a comparative evaluation. *Clin Exp Dermatol* 1994; **19**: 312-16.
- 14 Howe RC, Wondimu A Demissew A, et al. Functional heterogeneity among CD4+ T-cell clones from blood and skin of leprosy patients. Identification of T-cell clones distinct from Th0, Th1 and Th2. *Immunology* 1995; **84**: 585-94.
- 15 Cuevas-Santos J, Contreras F, McNutt NS. Multibacillary leprosy lesions with macrophages positive for Factor 13a. *J Cutan Pathol* 1998; **25**: 530-37.
- 16 Gimenez MF, Gigli I, and Tausk FA. Differential expression of Langerhans cells in the epidermis of patients with leprosy. *Br J Dermatol* 1989; **121**: 19-26.
- 17 Hashimoto K, Maeda Y, Kimura H, et al. Mycobacterium *leprae* infection in monocyte-derived dendritic cells and its influence on antigen-presenting function. *Infect Immun* 2002; **70**: 5167-76.
- 18 Mariotti S, Teloni R, Iona E, et al. Mycobacterium tuberculosis subverts the differentiation of human monocytes into dendritic cells. *Eur J Immunol* 2002; **32**: 3050-8