

Kienbock's Disease in a Child

Masoud Shayesteh Azar, Seyed Ahmad Shahab Kowsarian, Mohammad Ali Mohseni-Bandpei, Atefeh Hadian

Abstract

Kienbock's disease, which is an idiopathic osteonecrosis and collapse of the lunate bone, is an uncommon disease in children. This report describes a case of an 11-year-old girl, who presented with avascular necrosis of lunate bone confirmed by radiographic and magnetic resonance imaging evidence. After a short period of casting, the case was fully recovered within one year. The signal change was confirmed by magnetic resonance imaging, and the deformity of lunate that was demonstrated by avascular necrosis. The patient wore a long arm cast for six weeks, and after one year radiographic pattern was normalized.

Iran J Med Sci 2011; 36(2): 133-135.

Keywords • Kienbock's disease • lunate • osteonecrosis • avascular necrosis

Introduction

Kienbock's disease is a condition that leads to osteonecrosis and collapse of the lunate bone.¹ It is the most common form of aseptic osteonecrosis in the upper extremity.² It usually involves the dominant hands of males between 20 and 40 years of age, and presents with wrist pain and decreased wrist motion.¹⁻⁴ It is not uncommon in children.⁵ Usually, only one wrist is affected in this disease.⁶ A smaller lunate diameter and height, a more radially inclined lunate tilting angle and a flatter radial inclination are important anatomical risk factors for Kienbock's disease.⁷ The etiology of Kienbock's disease is still controversial.^{1-3,5,7,8} It is generally agreed that the end point of the disease, which is fragmentation and collapse, is the consequence of osteonecrosis. Both extrinsic and intrinsic factors are the causes of the disease.³ Revascularization and actual reconstitution of external shape of the lunate are more elusive goals.⁴ Herein we describe a case of a 11-year-old girl, who presented with avascular necrosis of lunate bone, and after a short period of casting fully recovered within one year.

Case Presentation

The case is an 11-year-old girl, who had a history of six months continuous right (dominant) wrist pain. The patient's sporting activity was gymnastics from three years before. She had no history of fracture or dislocation. Tenderness on right lunate bone was detected on physical examination. Wrist joint had near normal range of motion. Neurologic and vascular examinations were normal. Hand grip strength had decreased but pinch strength was normal. Radiographs showed sclerosis of lunate bone, which was graded according to Lichtman and colleagues classification as the stage IIA of Kienbock's disease (figure 1).^{1,3}

Department of Orthopaedics,
Imam Khomeini Hospital,
Mazandaran, Iran.

Correspondence:

Masoud Shayesteh Azar MD,
Department of Orthopaedics,
Imam Khomeini Hospital,
Po Box: 48166-33131,
Mazandaran, Iran
Tel: +98 151 2260920
Fax: +98 151 2263754
Email: Mshayestehazar@yahoo.com

Received: 10 April 2010
Revised: 24 August 2010
Accepted: 3 October 2010

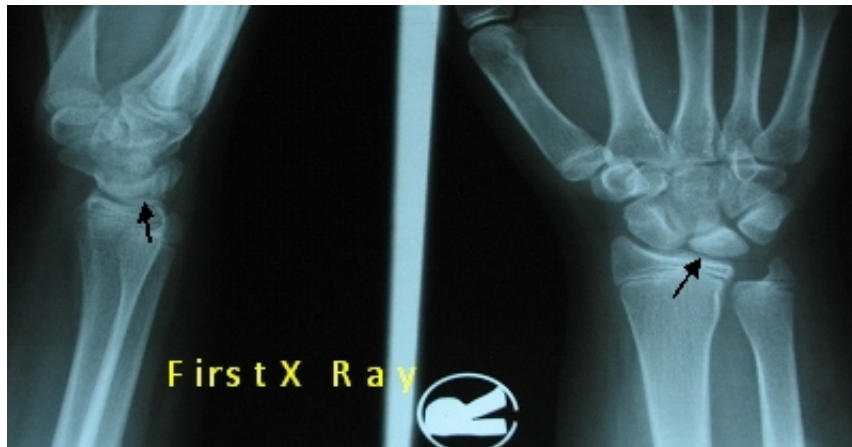

Figure 1: Radiographs showing sclerosis of lunate bone six months after the trauma.

Isotope scan with Tc 99m revealed increased lunate bone absorption and magnetic resonance imaging (MRI) confirmed signal change and deformity of lunate suggesting avascular necrosis (figure 2, 3). The patient wore a long arm cast for six weeks and stopped all of her sporting activities. In addition, she underwent physical therapy to improve hand grip strength. Clinically, wrist pain and other symptoms resolved. After one year, radiographic pattern returned to normal (figure 4), and clinical manifestations disappeared.

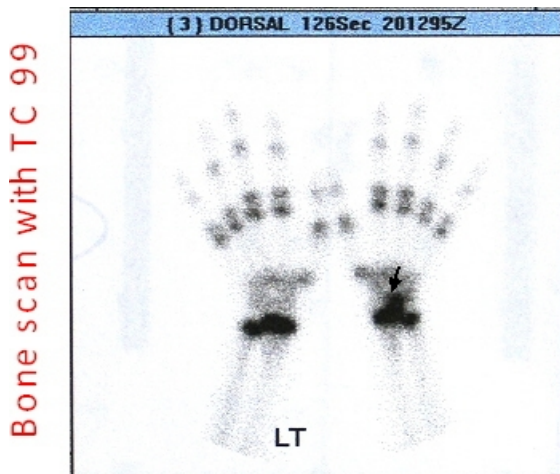

Figure 2: Bone scan with Tc 99m Isotope revealing increased lunate bone absorption six months after the trauma.

Discussion

Kienbock's disease (carpal lunate necrosis or lunatomalacia) is a process of unknown etiology resulting in osteonecrosis of the lunate bone.⁴ The most common clinical presentation is intermittent wrist pain, decreased wrist motion, and weakness of grip in the dominant hand.



Figure 3: Magnetic resonance imaging confirming signal change and deformity of lunate six months after the trauma.

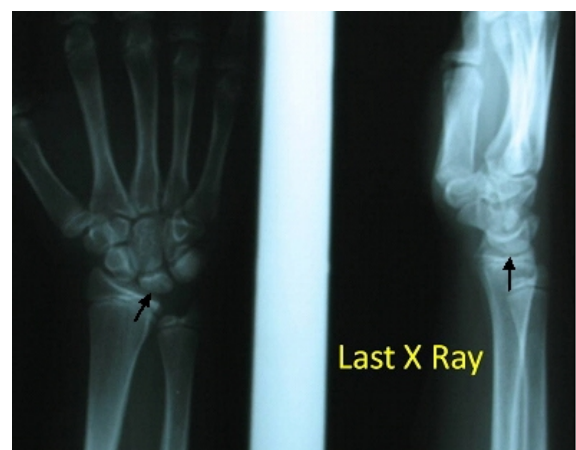


Figure 4: Radiographic pattern of the wrist twelve months after trauma showing the return to normality.

Usually, the pain is activity related and subsides with rest. In the early stages, when symptoms of disease are similar to wrist sprain,

diagnosis of the disease is difficult. The patients may not give a history of trauma, but the trauma may often exist in the distant past. At presentation, the patient may have swelling of wrist and tenderness in palpation of radiocarpal joint.

Motion is decreased in normal flexion/extension, and grip strength is commonly diminished to 50% of that of the other hand.³ There are limited number of published cases of kienbock's disease in childhood, but the incidence of the disease in children aging between 10 to 12 years is higher.⁷

In the early stages of the disease, the use of MRI, which is more specific and sensitive than bone scanning, can help in the diagnosis.^{1,3} In our patient, MRI confirmed signal change and deformity of lunate suggesting avascular necrosis.

Treatment of Kienbock's disease depends on the radiographic stage of the disease.¹ Koji Shigematsu treated an 11-year-old girl with Kienbock disease (stage IIIA) by temporary scaphotrapeziotrapezoidal pin fixation. The pins were removed after eight weeks. In follow up, movement of the wrist and grip strength improved, and pain disappeared. Revascularization of lunate was demonstrated on MRI.⁹

In another report by Ferlic, a 13-year-old boy with symptomatic stage III Kienböck's disease was treated successfully with a radial shortening procedure. This case showed evidence of lunate revascularization and remodeling after a radial shortening osteotomy.¹⁰ In the study of Almquist, twelve patients with early stages of Kienbock's disease and ulnar minus variant were treated by radial shortening procedures, and were followed for five to ten years. Eleven of the cases showed functional improvement. Grip strength and range of motion improved following surgery.¹¹ Luc De Smet,⁵ reported a case of a twelve-year-old girl with grip, which is similar to the present case. The case was treated conservatively, and during one year follow up favorable outcome was achieved, and the patient was pain free. The goal of surgical procedures is to unload the lunate and to decrease the compressive forces. These will result in the prevention of additional fragmentation and collapse, and theoretically improve revascularization of the lunate. Joint leveling is probably the most commonly used technique.^{1,4}

The case in the present study wore a long arm cast for six weeks, and was forbidden from all her sporting activities. Clinically, wrist pain and other symptoms resolved, and after one

year, radiographic pattern was normalized (figure 4). kienbock's disease rarely occurs in children, however, early diagnosis can result in simple nonoperative treatment, which is usually associated with a good outcome. Because of the disease's progressive and destructive effects on the wrist, it is important for physicians to take the announcement of the condition, try to diagnose it, and refer the patients to expert authorities in the early stages.

Conflict of Interest: None declared

References

- 1 Hurley RT, McKee MD. Kienböck's disease: an unusual cause of wrist pain in a 13-year-old girl. *Can J Surg* 2008; 51: E13-4.
- 2 Horch RE, Unglaub F, Dragu A, Kneser U, Bach AD. Kienböck's disease. Diagnosis and therapy. *Chirurg* 2008; 79: 452-60.
- 3 By Brian Divelbiss, Mark E. Baratz. Kienböck disease. *Journal of the American Society for Surgery of the Hand* 2001; 1: 61-72.
- 4 Ferlic RJ, Lee DH, Lopez-Ben RR. Pediatric Kienböck's disease: case report and review of the literature. *Clin Orthop Relat Res* 2003; 408: 237-44.
- 5 De Smet L. Kienböck's disease in a 12-year-old girl. *Acta Orthop Belg* 2003; 69: 361-2.
- 6 Yazaki N, Nakamura R, Nakao E, et al. Bilateral Kienbock's disease. *J Hand Surg Br* 2005; 30: 133-6.
- 7 Irisarri C. Aetiology of Kienböck's disease. *J Hand Surg Br* 2004; 29: 281-7.
- 8 Thienpont E, Mulier T, Rega F, De Smet L. Radiographic analysis of anatomical risk factors for Kienböck's disease. *Acta Orthop Belg* 2004; 70: 406-9.
- 9 Shigematsu K, Yajima H, Kobata Y, et al. Treatment of Kienböck disease in an 11-year-old girl with temporary fixation of the scaphotrapeziotrapezoidal joint. *Scand J Plast Reconstr Surg Hand Surg* 2005; 39: 60-3.
- 10 Ferlic RJ, Lee DH, Lopez-Ben RR. Pediatric Kienböck's disease: case report and review of the literature. *Clin Orthop Relat Res* 2003; 408: 237-44.
- 11 Almquist EE, Burns JF Jr. Radial shortening for the treatment of Kienböck's disease--a 5- to 10-year follow-up. *J Hand Surg Am* 1982; 7: 348-52.