

The Efficacy of Implant of Octacalcium Phosphate in Combination with Bone Matrix Gelatin on Bone Regeneration in Skull Defects in Rat

F. Sargolzaei-Aval¹, A. Sobhani²,
M.R. Arab¹, S.A. Sarani,¹ M.H. Heydari³

Abstract

Background: In several conditions we have face cranial bone defects. Reconstruction of these defects remains one of the most challenging problems encountered by craniofacial surgeons.

Objective: To evaluate bone repair in cranial bone defects by use of an implant made of octacalcium phosphate in combination with bone matrix gelatin (OCP/BMG).

Methods: We used 40, 5–6-week-old male Sprague-Dawley rats. A full thickness standardized trephine defect—5-mm in diameter—was made in the rat parietal bone and OCP/BMG was implanted into the defect. No OCP/BMG particles were implanted in control group that was otherwise treated identically. After sacrificing the rats chronologically and processing the tissues by routine histological procedures, 5- μ m thick sections of bone were stained and examined under light microscope.

Results: On the 5th day of implantation, inflammatory cells were seen around the implanted materials, especially around the OCP particles. By the end of 21st day, almost all of the OCP/BMG particles were absorbed and bone trabeculae, bone marrow cavities and bone marrow tissues were seen. In the control group, at the end of 21th day, a few areas of new bone were seen near to the defect margins and host bone, however, in much less amount than in the experimental group.

Conclusion: Implant of OCP/BMG appears to stimulate new bone regeneration in bone defects. These biomaterials can be used for repair of cranial bone defects.

Iran J Med Sci 2004; 29(3): 124-129.

Keywords • Bone Regeneration • Octacalcium Phosphate • Bone Matrix Gelatin • Rat

Introduction

Reconstruction of bony defects of the craniofacial region remains one of the most challenging problems encountered by craniofacial surgeons.¹ Several types of implants and composite bone graft substitutes consisting of osteo-inductive proteins and biocompatible delivery matrix have been used to fill such defects.^{2,3}

Departments of Anatomy,
¹Zahedan University of Medical Sciences, Zahedan, Iran.
²Tehran University of Medical Sciences, Tehran, Iran.
³Fasa Faculty of Medical Sciences, Fasa, Iran.

Correspondence:

Fereydoon Sargolzaei-Aval PhD
PO Box: 98165-343,
Zahedan, Iran
Tel/Fax: +98 541 2448584
E-mail: fsargolzaei@yahoo.com

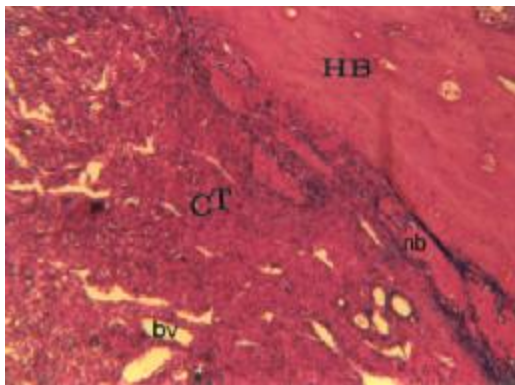


Fig 1: Photomicrograph of untreated control group on day 21; a narrow margin of new bone (NB) attached to the host bone (HB) is observed. All of the defects were filled by connective tissues (CT) H&E, x160.

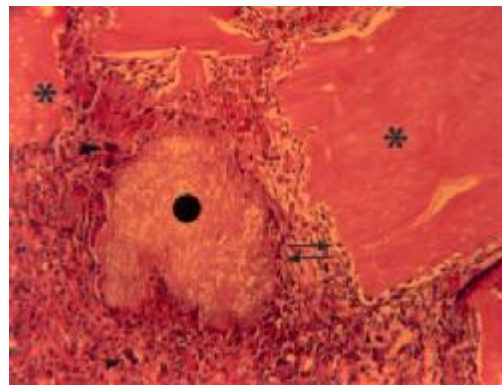


Fig 2: Photomicrograph of treated group on day 5; spindle-shaped cells (arrow) surrounded the BMG (-) and OCP (•) particles, and occasionally multinucleated giant cells (arrow heads) are observed around the implants (H&E, x160).

One type of such implants is calcium phosphate components. These materials have been used successfully in bone repair, because of their biocompatibility and their chemical and physical resemblance to the inorganic hydroxyapatite component of bone.⁴⁻⁸ Biological apatite in bone tissue has been suggested to be formed via precursor phases. It is generally accepted that hydroxyapatite (HA) in hard tissues, such as bone and tooth enamel, is calcium deficient carbonate apatite. In supersaturated calcifying solution, calcium deficient HA has been shown to precipitate via the formation of one precursor such as octacalcium phosphate. For that reason, it is believed that precursor phase may participate in biological mineralization, such as octacalcium phosphate.^{9,10} It has previously been reported that synthetic octacalcium phosphate (OCP) granules can stimulate bone formation, if implanted in the subperiosteal region and areas of skull defect in rats.¹¹⁻¹⁴

Another substance, also known to induce bone is bone matrix gelatin (BMG), a complex insoluble substance composed of type I collagen and a heterogeneous group of noncollagenous proteins.¹⁵⁻¹⁷ One of these proteins is bone morphogenic protein (BMP) which persuades local mesenchymal cells to differentiate into bone forming cells, a process known as osteoinduction. This protein is suggested to be responsible, in part, for the osteoinductive properties of BMG.¹⁸

Because of abilities of both OCP and BMG to enhance bone formation, the plasticity of OCP and its ability to adsorb protein,¹⁹ and the necessity for a carrier for BMP we hypothesized that OCP can be used as an effective carrier for BMP to enhance bone repair. Therefore, the objective of the present study is to examine the efficacy of an implant made of

OCP in combination with BMG (OCP/BMG) on skull defects as compared to untreated controls.

Materials and Methods

Animals

Forty 5–6-week-old male Sprague-Dawley rats weighting between 125 and 150 g were used. The rats were obtained from Animal Research Center of Pasteur Institute, Tehran, Iran. They were kept under a standard light-dark schedule and relative humidity. Stock diet and tap water were available *ad libitum*.

Preparation of Implants

Octacalcium phosphate (OCP) was prepared according to the method described by Legeros.²⁰ In brief, 250 ml of 0.04 M Ca (CH₃CO₂)₂·H₂O solution was slowly added to 250 ml of 0.04 M NaH₂PO₄·2H₂O solution over a period of one hour. The solution was stirring at 400 rpm at 67.5°C. Ground granules of OCP between 32 and 48 mesh (particle size: 300–500 µm) were used for implantation. The saved granules were sterilized by being heated at 120 °C for 2 hrs and implanted. Previous studies have shown that heat does not affect physical properties such as crystalline structure of the specific surface area of the granules of OCP.¹⁹ Bone matrix gelatin (BMG) was prepared by the method previously described by Jurist,¹⁶ which was modified by the method of Wei-Qi Yan.¹⁷ Briefly, shafts of femora and tibiae from 4-week-old male Sprague Dawley rats were cut into chips. Liquid nitrogen was used to freeze the bone shafts after their removal and while they were being cut into chips to avoid possible denaturation of proteins, the bone chips were extracted in chloroform-methanol (1:1) for 4 hr at 25 °C, demineralized

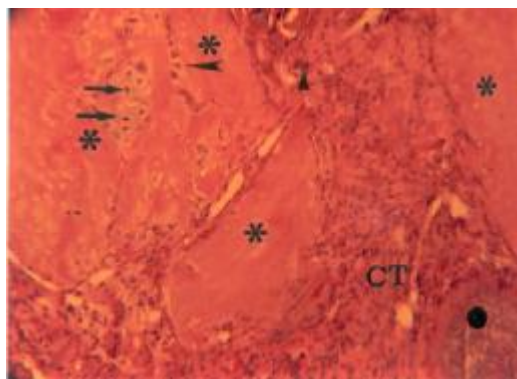


Fig 3: Photomicrograph of treated group on day 7; a few clusters of cartilage cells (arrows) can be seen between the BMG particles (*). In addition, round-shaped cells (long arrow head) can be seen between BMG particles (H&E, x160).

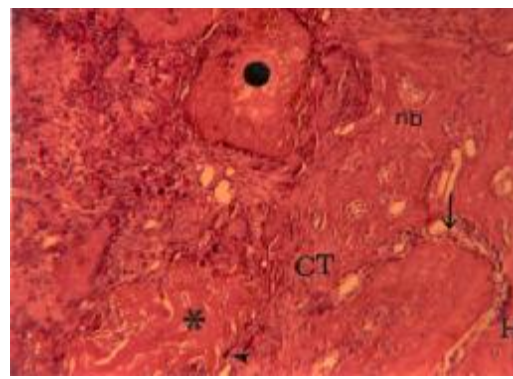


Fig 4: Photomicrograph of treated group on day 14; newly-formed bone (nb) initiated near to the defect margins and host bone (HB). Osteoblasts (arrow) and multinucleated giant cells (arrow head) can be observed on the surface of new bone and BMG particles (H&E, x100).

in 0.6 N of hydrochloric acid at 4 °C for 72 hr, and gelatinized in 6 M of lithium chloride at 2 °C for 24 hr. The bone chips then were auto digested at 37 °C for 48 hr in phosphate buffer (pH 7.4) with 10 mM of sodium azide and 5 mM of iodoacetic acid as a protease inhibitor.^{16,17} The bone chips then were pulverized with a sample chamber and sifted. Particles sized 75-500 µm were collected by the testing sieve, lyophilized, sterilized in ethylene oxide, and stored in sterile glass containers.

Experimental Periods

The rats were randomized into two groups of equal size: OCP/BMG treated group (n=20) and untreated control group (n=20). Five rats from each group were sacrificed and fixed at 5th, 7th, 14th and 21st days after the implantation of OCP or a control group.

Implantation Procedure

The animals were anesthetized with intraperitoneal injection of ketamine hydrochloride (Ketolar™) at a dose of 60 mg/kg body weight, supplemented by ether inhalation. An elliptical skin incision about 15-mm long was made aseptically along the left temporal line. The dissection was carried down to the calvarium. Periosteum of the calvarium was ablated and a full-thickness standardized trephine defect, 5 mm in diameter, was made in the parietal bone under continuous saline buffer irrigation. Extreme care was exercised to avoid injury to the dura mater. In treated animals OCP/BMG combination (in ratio1:4) was implanted into the trephine defect and covered with surgical. A similar procedure was followed in control group but nothing was implanted into the trephine defect.

Tissue Preparation

The rats were anesthetized by intraperitoneal injection of ketamine hydrochloride (60 mg/kg body weight). They were then fixed with 4% paraformaldehyde in 0.1 M phosphate-buffer saline (PBS, pH 7.4) by perfusion through the aorta. The implants were resected together with the surrounding bone and tissues and kept in the same fixative overnight at 4 °C. The specimens were decalcified in a mixture of 10% formic acid, 2.9% citric acid, and 1.8% trisodium citrate dehydrate for three weeks as described elsewhere.¹¹ The samples were dehydrated in a graded series of ethanol and embedded by paraffin. Serial sections of 5 µm thicknesses were cut horizontally and stained with H&E and alcian blue and studied under light microscope (Olympus AX-800).

Results

In the control group, at the day 21, the defects were filled by dense fibrous connective tissue. A narrow margin of new bone formation could be seen around the edges of the defects (Fig1).

On the 5th day post-implantation, the resected specimens from experimental animals showed infiltrated with spindle-shaped connective tissue cells with occasion multinucleated giant cells, especially around the OCP particles (Fig 2). By day 7, a few clusters of cartilage cells dispersed between the BMG particles in the central position of the defects (Fig 3) were apparent. New bone formation was observed, by the day 14, at the margin of the defects (Fig 4), and on the implanted OCP/BMG particles, far away from the margin defects. Osteoblasts were visible on newly-formed bone and around the implanted particles (Figs 4, 5). Some implanted particles were surrounded by multinucleated giant cells (Fig

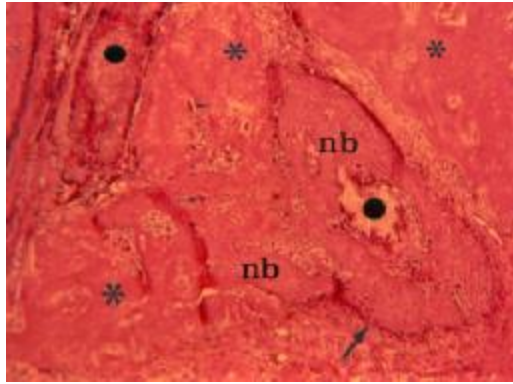


Fig 5: Photomicrograph of treated group on day 14; newly-formed bone is observed on the implanted particles (•,*) especially on the OCP particles (•), away from the margins. Some of the implanted particles and newly-formed bone are surrounded by osteoblasts (arrow) and multinucleated giant cells (short arrow) (H&E, x100).

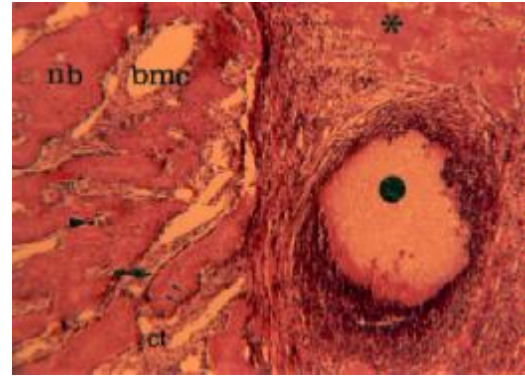


Fig 6: Photomicrograph of treated group on day 21; further apposition of new bone (nb) can be seen that have filled the defect. Bony trabeculae are surrounded by osteoblasts (arrow). Many osteocyte (short arrow) and well-developed bone marrow cavity (bmc) can be observed (H&E, x160).

5). On day 14, no cartilage was seen in the defects of the experimental animals. Newly-formed bone filled the defects on the day 21. The bone matrix became more compact and bone trabeculae, bone marrow cavities and tissues were more obvious in the experimental animals as compared to the controls (Fig 6). At the end of the study, most of the implanted particles were absorbed and replaced by newly-formed bone.

Discussion

Since autograft materials may not be available in sufficient amounts, repair of large bony defects in the craniofacial region is a challenging task for surgeons.²¹ Recent studies have advocated the use of other alloplastic materials with osteoinductive properties, such as demineralized bone matrix (DBM) and BMG,^{16-18, 22-24} and materials with osteoconductive properties, such as hydroxyapatite (HA) and β -tricalcium phosphate (β -TCP).²⁵⁻²⁷ Furthermore, previous studies have indicated that synthetic OCP granules stimulate bone repair when implanted in the skull defect of rats.¹⁴

A novel delivery system including OCP/BMG was used in this study. Our experiment demonstrated that OCP/BMG composite could enhance bone repair through augmentation of the host bone regeneration. It also showed resorption of the implanted materials in the early stage of bone formation. Previous studies have confirmed that the implanted OCP can serve as a core for initiating bone formation and shows the osteoinductive ability as well as the osteoconductive properties, if it is implanted in the critical-sized calvarial defect of rats.^{28,29} A critical-size bone defect is de-

defined as the size of an osseous defect that does not heal spontaneously with bone during the lifetime of the animal unless some osteogenic, osteoconductive, or osteoinductive material is placed in or onto the defect.² The advantage of BMG is attributed to its content and diffusibility of the BMP and other osteoinductive cytokines, which interact with undifferentiated osteogenic precursor cells in the host bed and that cause them to differentiate into functionally active osteogenic elements.^{16,17} For these reasons, we proposed that OCP, in addition to acting as an osteoinductive material for the promotion of bone ingrowths, could be used as an effective carrier for BMP so that it is released from BMG.

The present study indicated that the size of the implanted materials reduces with time. It suggests that resorption of the implants is perhaps enhanced by combining BMG and OCP. A previous study showed that the multinucleated giant cells (MNGCs) around the implanted materials, especially OCP, share ultrastructural features with osteoclast.³⁰ The recent study has demonstrated that osteoinductive cytokines may act directly on the osteoclast progenitor cell population to stimulate differentiation.³¹ BMP released from OCP/BMG may stimulate MNGCs to differentiate further and resorb the implanted materials. However, it is not clear how OCP/BMG implants surrounded directly by newly-formed bone are resorbed. The implants may also be resorbed by the MNGCs after being exposed by the remodeling process of surrounding bone. In the present study, the size of implants was decreased with time; however the implants still remained in the newly-formed bone up to 3 weeks of implantation. They might be resorbed further with the

passage of time. The number of MNGCs around the implants seemed to decrease with time as the implanted materials become surrounded by newly-formed bone.

Our study demonstrated that OCP combined with BMG could synergistically enhance bone repair as well as resorption of the implants in the early stages of bone formation. The combination of OCP/BMG could be a suitable bone substitute which is expected to be resorbed within a relatively short time and replaced by newly-formed bone in the meantime. Finally, we propose that OCP could also be used as an effective carrier for other osteoinductive cytokines in clinical application.

References

- 1 Toriumi DM, Robertson K. Bone inductive biomaterials in facial plastic and reconstructive surgery. *Fac Plast Surg* 1993; **9**: 29-36.
- 2 Schmitz JP, Hollinger JO. The critical size defect as an experimental model for craniomandibulofacial nonunions. *Chin Orthop* 1986; **205**: 299-308.
- 3 Kent JN, Misiak DJ, Kinnebrew MC: Alloplastic materials for augmentation in cosmetic surgery. In: pettersen LJ ed:principles of Maxill of acial Surgery, 2nd ed. philadelphia: J.B. Lippincott, 1992: 1769-813.
- 4 Hon T, Carranza FA, Kenney EB. Calcium phosphate ceramics in dentistry:a review of the literature. *J West Sco.periodontol Periodontol Abstr* 1984; **32**: 88-108.
- 5 Jarcho M, Calcium phosphate ceramics as hard tissue prosthetics. *Clin Orthop* 1981; **157**: 259-78.
- 6 Drobeck HP, Rothstein SS, Gumaer KL, Sherer AD, Slighter RG. Histologic observation of long term soft tissue responses to implanted, mulifaceted particles and discs of hydroxylpatite. *J Oral Maxillofac Surg* 1984; **42**: 143-9.
- 7 Metsger DS, Driskell TD, Paulsrud JR. Tricalcium Phosphate ceramic--a resorbable bone implant: review and current status. *J AM Dent Assoc* 1982; **105**: 1035-8.
- 8 Froum S, Stahl SS. Human intraosseous healing responses to the placement of tricalcium phosphate ceramic implants. II. 13 to 18 months. *J Periodontol* 1987; **58**: 103-9.
- 9 Nelson DG, Mc Lean JD. High-resolution electron microscopy of octacalcium phosphate and its hydrolysis products. *Calcif Tissue Int* 1984; **36**: 219-32.
- 10 Brown WE, Eidelman N, Tomazic B. Octacalcium Phosphate as a precursor in biomineral formation. *Adv Dent Res* 1987; **1**: 306-13.
- 11 Sasano Y, Kamakura S, Nakamura M, Suzuki O, et al. Subpriosteal implantation of octacalcium phosphate (OCP) stimulates both chondrogenesis and osteogenesis in the tibia, but only osteogenesis in the parietal bone of a rat. *Anat Rec* 1995; **242**: 40-6.
- 12 Sasano Y, Kamakura S, Homma H, Suzuki O, et al. Implanted octacalcium phosphate (OCP) stimulates osteogenesis by osteoblastic cells and/ or committed osteoprogenitors in rat calvarial periosteum. *Anat Rec* 1999; **256**: 1-6.
- 13 Kamakura S, Sasano Y, Nakamura M, Suzuki O, et al. Initiation of alveolar ridge augmentation in the rat mandible by subperiosteal implantation of octacalcium phosphate. *Arch Oral Biol* 1996; **41**: 1029-38.
- 14 Kamakura S, Sasano Y, Homma H, Suzuki O, et al. Implantation of octacalcium phosphate (OCP) in rat skull defects enhances bone repair. *J Dent Res* 1999; **78**: 1682-7.
- 15 Anastassiadus T, Puzic O, Puzic R. Effect of solubilized bone matrix components on cultured fibroblasts derived from neonatal rat tissues. *Calcif Tissue Res* 1978; **26**: 173-9.
- 16 urist MR, Iwata H, Peter L, Cocotte RL, et al. Bone Morphogenesis in Implants of Insoluble Bone Gelatin. *Proc Natl Acad Sci USA* 1973; **70**: 3511-5.
- 17 Yan WQ, oka M, Nakamura T. Bone bonding in bioactive glass ceramics combined with bone matrix gelatin. *J Biomed Mater Res* 1998; **42**: 258-65.
- 18 Mizutani H, Urist MR. The nature of bone morphogenic protein (BMP) fractions derived from bovine bone matrix gelatin. *Clin Orthop* 1982; **171**: 213-23.
- 19 Suzuki O, Nakamura M, Miyasaka Y, et al. Maclura pomifera agglutinin-binding glycoconjugates on converted apatite from synthetic octacalcium phosphate implanted into subperiosteal region of mouse calvaria. *Bone miner* 1993; **20**: 151-66.
- 20 Legeros RZ. Preparation of octacalcium phosphate (OCP): a direct fast method. *Calcif Tissue Int* 1985; **37**: 194-7.
- 21 Furuzawa T, Mizunuma K, Yamashita S, Takahashi T. Investigation of early bone formation using resorbable bioactive glass in the rat mandible. *Int J Oral Maxillofac Implants* 1998; **13**: 672-6.
- 22 Yamashita K, Takagi T. Ultrastructural observation of calcification proceeding new bone formation induced by demineralized bone matrix gelatin. *Acta Anat* 1992; **143**:

- 261-7.
- 23 Rabie AB, Deng YM, Samman N, Hagg U. The effect of demineralized bone matrix on the healing of intramembranous bone grafts in rabbit skull defects. *J Dent Res* 1996; **75**: 1045-51.
 - 24 Wang J, Glimcher MJ. Characterization of matrix-induced osteogenesis in rat calvarial bone defect: I. Differences in the cellular response to demineralized bone matrix implanted in calvarial defects and in subcutaneous sites. *Calcif Tissue Int* 1999; **65**: 156-65.
 - 25 Okuda K, Nakajima Y, Irie K, Sugimoto M, et al. Transforming growth factor beta1 coated beta-tricalcium phosphate pellets stimulate healing of experimental bone defects of rat calvariae. *Oral dis* 1995; **1**: 92-7.
 - 26 Alper G, Bernic S, Yazdi M, Nimni ME. Osteogenesis in bone defects in rats: the effects of hydroxyapatite and demineralized bone matrix. *Am J Med Sci* 1989; **298**: 371-6.
 - 27 Ohgushi H, Okumura M, Tamai S, et al. Marrow cell induced osteogenesis in porous hydroxyapatite and tricalcium phosphate: a comparative histomorphometric study of ectopic bone formation. *J Biomed Mater Res* 1990; **24**: 1563-70.
 - 28 Kamakura S, Sasano Y, Homma H, Suzuki O, et al. Implantation of octacalcium phosphate nucleates isolated bone formation in rat skull defects. *Oral dis* 2001; **7**: 259-65.
 - 29 Kamakura S, Sasano Y, Nakajo S, Shimizu T, et al. Implantation of octacalcium phosphate combined with transforming growth factor-beta1 enhances bone repair as well as resorption of the implant in rat skull defects. *J Biomed Mater Res* 2001; **57**: 175-82.
 - 30 Kamakura S, Sasano Y, Homma H, Nakamura M, et al. Multinucleated giant cells recruited by implantation of Octacalcium phosphate (OCP) in rat bone marrow share ultrastructural characteristics with osteoclasts. *J Electron Microsc* 1997; **46**: 397-403.
 - 31 Sells Galvin RJ, Gatlin CL, Horn JW, Fuson TR. TGF-beta enhances osteoclast differentiation in hematopoietic cell cultures stimulated with RANKL and M-CSF. *Biochem Biophys Res Commun* 1999; **265**: 233-9.