

Bilateral Pulmonary Thromboembolism: An Unusual Presentation of Infection with Influenza A (H1N1) Virus

Parviz Saleh¹, Hamid Noshad²

Abstract

Swine flue is a highly contagious acute respiratory disease caused by a subtype of influenza A virus. Herein we present three patients with H1N1 infection complicated with pulmonary thromboembolism. The patients had chest pain and unexplained dyspnea. Imaging studies showed bilateral hilar predominance. Computed tomographic angiography confirmed bilateral thromboembolism (an unusual presentation of H1N1 infection). We did not find any predisposing factor including endothelial damage, stasis, or hypercoagulable state in these patients. They did not receive any medication. After anticoagulation and treatment with oseltamivir, all the patients were discharged in good condition. To the best of our knowledge bilateral pulmonary thromboembolism has not been reported in English language literature in patients with swine flu infection. Appropriate diagnosis and treatment will be life saving in this condition.

Iran J Med Sci 2010; 35(2): 149-153.

Keywords • H1N1 • Influenza A • thromboembolism • angiography

Introduction

Swine flue is a highly contagious acute respiratory disease caused by a subtype of influenza A virus.¹ In 2009 many cases of human to human transmission by H1N1 subtype were reported. Up to the time of writing this report, the disease spread rapidly all around the world with high mortality.² The disease presents typically with fever, cough, sore throat, chills, headache, rhinorrhea, dyspnea, myalgia, arthralgia, fatigue, vomiting, and diarrhea.³

Most of affected patients have mild disease, however, a small percentage of the patients suffer from sever complications, which may lead to death. Respiratory problems especially acute respiratory disease, which is a life threatening complication are more remarkable.⁴

Laboratory findings in swine flue are lymphopenia, elevated serum LDH and creatine phosphokinase levels, and thrombocytopenia.⁵

Previous studies have described the findings in the lung imaging as unilateral or bilateral opacities, focal, multi focal, and diffuse ground glass involvement with consolidation, or interstitial markings. In most cases, the manifestations are similar to severe acute respiratory syndrome (SARS). In some reports, mediastinal lymphadenopathy has been described.⁶

Several rare complications such as Guillain-Barre syndrome have been reported from patients with Swine flu infection.⁶

¹Department of Infectious Disease,

²Department of Internal Medicine,
Tabriz University of Medical Sciences,
Tabriz, Iran.

Correspondence:

Hamid Noshad MD,
Department of Internal medicine,
Tabriz University of Medical Sciences,
Tabriz, Iran.

Tel: +98 411 5415023

Fax: +98 411 3338789

Email: hamidnoshad1@yahoo.com

Received: 14 December 2009

Revised: 10 February 2010

Accepted: 7 March 2010

In 2009, pulmonary thromboembolism was reported as a rare complication of such infection.⁷ Also in 2000, acute pulmonary microthromboembolism was found in patients with influenza A infection.⁸ However, we did not find any report of bilateral pulmonary thromboembolism in English language literature. Herein we present three patients with such a rare complication of such infection.

Cases History

From October to December 2009, of the patients admitted to Sina hospital, Tabriz, Iran, with the diagnosis of H1N1 infection, three patients had chest pain and unexplained dyspnea. Simultaneously they had fever, headache, vertigo, abdominal pain, and rhinorrhea. RT-PCR testing for Swine flu was performed, which confirmed the diagnosis. Computed tomographic (CT) angiography revealed bilateral pulmonary thromboembolism.

Case 1

A 68-year-old man with H1N1 infection admitted to our hospital. RT-PCR testing confirmed H1N1 infection. Chest radiography showed bilateral hilar predominance (figure 1). Because of dyspnea and chest pain, CT angiography was requested. The imaging study revealed filling defects in left inferior lobar artery as well as filling defects in lateral and postero-inferior lobar artery of the right lung (figure 2a). Lymphadenopathy was apparent in both hilar

regions. Alveolar ground glass opacities were seen peripherally.

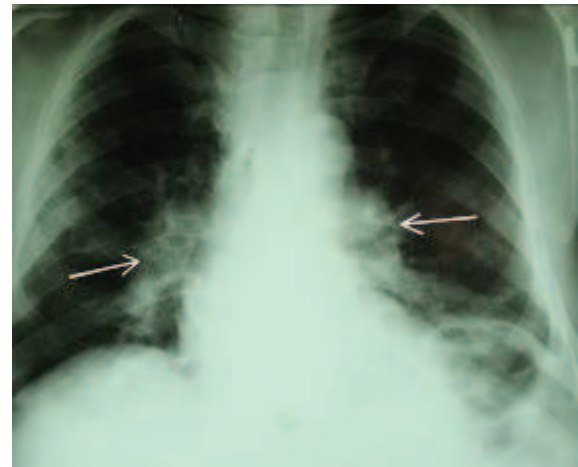


Figure 1: Chest radiography showing bilateral predominance.

Case 2

A 30-year-old woman admitted because of the signs and symptoms related to swine flu infection. Evaluation with RT-PCR confirmed the H1N1 infection. Dyspnea, chest pain, and low blood pressure led us to request a CT angiography, which revealed bilateral thromboembolism. We found filling defect in distal left artery extended to upper and lower inferior segments. Another partial filling defect was seen in lateral and posterior segments of lower right artery (figure 2b). Perihilar ground glass appearance associated with collapse consolidation was detected in basal area of right lung (figure 3).

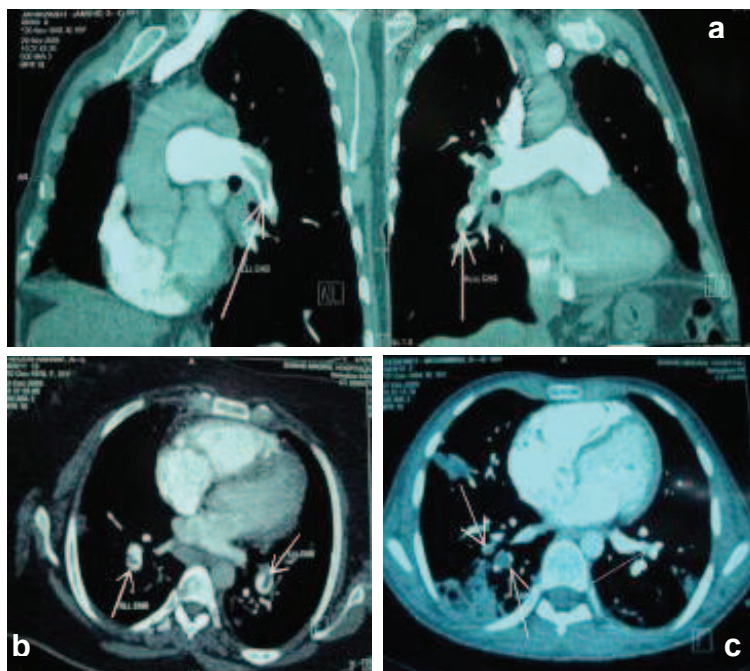


Figure 2: CT scan showing bilateral thromboembolism in both pulmonary arteries of reported patients.

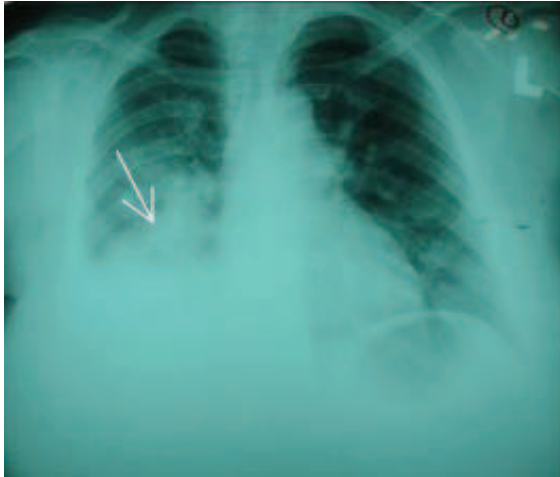

Figure 3: Chest radiography showing ground glass and collapse consolidation.

Case 3

A 16-year-old boy with signs related to H1N1 infection admitted to our hospital. Evaluation with RT-PCR test confirmed the swine flu infection. After two days his condition was deteriorated by shortness of breathing and chest pain. Chest radiography showed bilateral hilar predominance. CT angiography revealed bilateral thromboembolism (figure 2c).

Lower limbs Doppler sonography of all patients could not reveal any deep vein thrombosis. Serum levels of protein C, protein S, and antithrombin III were in normal range. We were not able to find any predisposing factor such as endothelial damage, stasis, or hypercoagulable state. The patients did not receive any medication. Abdominal sonography did not provide any remarkable findings. We did not find any detectable malignancy. Vital signs and laboratory data are shown in table 1.

The patients were treated with heparin (10000 U intravenously) in the initial phase and then 1000 U per hour. Warfarin (5 mg, orally) was started for all of them. After five days INR and prothrombin time (PTT) were in the therapeutic range. Chest pain and dyspnea diminished. Treatment with oseltamivir (75 mg twice daily orally) was started and after 10 days the signs and symptoms related to swine flu infection were also relieved. After 14 to 20 days the patients discharged without any other complications. Any significant problem was not found in their follow-up visits.

Discussion

Novel swine-origin influenza A (H1N1) virus, commonly known as swine flu, rapidly spread worldwide. The clinical manifestations are diverse and include flu-like symptoms such as fever, cough, sore throat, body aches, headache, chills, and fatigue. In addition, nausea, vomiting, and/or diarrhea have been reported.⁵

In addition to the chest radiography, clinical suspicion of pulmonary thromboembolism may necessitate chest CT with contrast. Several patients with severe form of the disease were diagnosed with acute pulmonary thromboembolism during their hospital stay.⁹ In one patient, a large embolus required an interventional procedure for mechanical fragmentation of the embolus.⁹ Although sepsis and acute respiratory distress syndrome are known to cause hypercoagulable states, acute pulmonary thromboembolism is not a common complication of influenza infection.⁹ Van Wissen and colleagues,¹⁰ conducted a study on the frequency of influenza in a cohort of patients

Table 1: Vital signs and laboratory data of the three patients

Vital signs & laboratory data	Patient 1	Patient 2	Patient 3
Blood pressure (mmHg)	130/80	110/80	100/80
Respiratory rate (/min)	28	40	35
Heart rate (beat/ min)	90	98	100
Body temperature (°C)	39.5	38.9	38.3
Blood pH	7.40	7.50	7.40
PCO ₂ (mmHg)	33	37	21
PO ₂ (mmHg)	99	98	91
O ₂ sat	92%	90%	81%
HCO ₃ (meq)	22	28.4	21
PT (Second)	13	13	14
PTT(Second)	35	42	38
INR	1	1.1	1.1
CPK(IU)	91	312	70
Hb (mg/dl)	10.2	13	12.3
WBC (/μL)	9500	8700	6500
Lymphocyte	50%	48%	45%
PLT (/μL)	179000	110000	100000

with a clinical suspicion of pulmonary thromboembolism and found that influenza A infection was less common (1%) among patients with proven pulmonary thromboembolism than those without pulmonary thromboembolism (4.3%). They concluded that influenza infection was not an important risk factor for pulmonary thromboembolism. There is a report of two patients with influenza A (H3N2) who developed acute pulmonary thromboembolism diagnosed by lung CT.⁸ The study of laboratory-confirmed swine-origin influenza A (H1N1) virus from Mexico did not show high incidence of pulmonary thromboembolism.³ Knowledge of this complication, which presumably is secondary to a hypercoagulable state, is important not only for the clinicians but also for the radiologists to avoid missing emboli on contrast-enhanced CTs performed for other reasons.

Diagnosis of pulmonary embolism is generally established when the patient has characteristic pulmonary perfusion abnormalities in the setting of an appropriate clinical history and with no concurrent cardiopulmonary disease on chest radiography.¹¹ In a report, the initial evaluation including positive pulmonary perfusion scan of four young black women suggested the diagnosis of pulmonary emboli. A syndrome of respiratory tract viral infection was then developed and further evaluation by angiography and perfusion scans contradicted the diagnoses of pulmonary emboli. All of the patients had substantial convalescent-phase complement-fixation titers to influenza A.¹²

One report presented two patients with rapidly progressive hypoxemia associated with influenza A (H3N2) virus infection, who were diagnosed as having influenza related acute pulmonary microthromboembolism by testing serum D-dimer, lung perfusion and ventilation scans, and CT of the chest. They were successfully treated by anti-coagulant therapy. The report suggested that acute-onset pulmonary microthromboembolism should be considered in some patients with sudden, unexplained dyspnea during an outbreak of influenza infection and prompt diagnosis is essential to save the patients' lives from acute death associated with influenza.⁸

During the 2-month period, 40 patients admitted to our medical center with the diagnosis of H1N1 infection. Of them, three patients (7.5%) had bilateral pulmonary thromboembolism. Our patients initially showed the clinical manifestation of influenza such as fever, cough, rhinorrhea, and myalgia. RT-PCR testing confirmed the H1N1 infection. Delay in diagnosis and appropriate treatment of the

pulmonary embolism may lead to increased mortality and morbidity. It must be emphasized that our patients simultaneously had other pulmonary findings such as bilateral ground glass opacities due to H1N1 infection. The finding of ground glass opacities was supported by the observation that the underlying lung structure was discernible for most of these foci. Ground glass opacities are generally attributable to the partial displacement of air from partial filling of air spaces, thickening of interstitial tissues by fluid or cells, partial alveolar collapse, or increased capillary blood volume.¹³

Initial radiographic findings in our patients suggested differential diagnoses such as atypical infections (with mycoplasma or legionella), beginning of ARDS, eosinophilic pneumonitis, or hypersensitivity pneumonitis.¹⁴ Pulmonary edema was rejected because of the physical examinations and electrocardiographic findings. In pulmonary edema perihilar distribution of confluent ground glass opacities and associated pleural effusion may be seen.¹⁵ Previous studies described a variety of different lung involvements caused by swine flu. Bilateral patchy opacities were described in all patients.^{16,17} Many patient with mediastinal lymphadenopathies were also reported.¹⁶ Bilateral ground glass and alveolar peripheral opacities were also reported in both lungs.¹⁸ Bilateral thromboembolism has not been reported in H1N1 infection so far. We did not find any predisposing factor such as endothelial damage, hypercoagulable state and stasis, medication use or protein C, protein S or antithrombin III deficiency for thromboembolic event in our patients.¹¹ Doppler sonography did not show lower limbs deep vein thrombosis. It seems that bilateral pulmonary thromboembolism can be a rare finding in patients with swine flu infection.

Certain limitations for the present case analysis should be considered. Firstly, a single case presentation cannot suggest a generalized pattern to prove a pathologic mechanism. Other cases must be reported and compared. Secondly, although our patients received anticoagulation and anti-viral therapy and discharged with good general condition, we cannot predict the outcome of this form of lung involvement in patients with H1N1 virus infection.

Conclusion

This article described a unique form of pulmonary involvement (bilateral pulmonary thromboembolism) that has not been reported previously in swine flu infection. Early diagnosis and treatment may lead to an excellent outcome.

Conflict of Interest: None declared

References

- 1 Neumann G, Noda T, Kawaoka Y. Emergence and pandemic potential of swine-origin H1N1 influenza virus. *Nature* 2009; 459: 931-9.
- 2 Sullivan CJ, Jordan MC. Diagnosis of viral pneumonia. *Semin Respir Infect* 1988; 3: 148-61.
- 3 Perez-Padilla R, de la Rosa-Zamboni D, Ponce de Leon S, et al. Pneumonia and respiratory failure from swine-origin influenza A (H1N1) in Mexico. *N Engl J Med* 2009; 361: 680-9.
- 4 Monto AS, Whitley RJ. Seasonal and pandemic influenza: a 2007 update on challenges and solutions. *Clin Infect Dis* 2008; 46: 1024-31.
- 5 Gaydos JC, Top FH Jr, Hodder RA, Russell PK. Swine influenza a outbreak, Fort Dix, New Jersey, 1976. *Emerg Infect Dis* 2006; 12: 23-8.
- 6 Asburay AK. Guillain-Barré syndrome: historical aspects. *Ann Neurol* 1990; 27: S2-6.
- 7 Agarwal PP, Cinti S, Kazerooni EA. Chest radiographic and CT findings in novel swine-origin influenza A (H1N1) virus (S-OIV) infection. *AJR Am J Roentgenol* 2009; 193: 1488-93.
- 8 Ohrui T, Takahashi H, Ebihara S, et al. Influenza A virus infection and pulmonary microthromboembolism. *Tohoku J Exp Med* 2000; 192: 81-6.
- 9 Schultz MJ, Haitsma JJ, Zhang H, Slutsky AS. Pulmonary coagulopathy as a new target in therapeutic studies of acute lung injury or pneumonia--a review. *Crit Care Med* 2006; 34: 871-7.
- 10 Van Wissen M, Keller TT, Ronkes B, et al. Influenza infection and risk of acute pulmonary embolism. *Thromb J* 2007; 5: 16.
- 11 Turpie AG, Chin BS, Lip GY. Venous thromboembolism: pathophysiology, clinical features, and prevention. *BMJ* 2002; 325: 887-90.
- 12 Lynn DJ, Wyman AC, Varman VM. Influenza A infection simulating pulmonary embolism. *JAMA* 1977 238: 1166-8.
- 13 Hansell DM, Bankier AA, MacMahon H, et al: Fleischner Society: glossary of terms for thoracic imaging. *Radiology* 2008; 246: 697-722.
- 14 Ujita M, Renzoni EA, Veeraraghavan S, et al. Organizing pneumonia: perilobular pattern at thin-section CT. *Radiology* 2004; 232: 757-61.
- 15 Müller NL, Ooi GC, Khong PL, et al. High-resolution CT findings of severe acute respiratory syndrome at presentation and after admission. *AJR Am J Roentgenol* 2004; 182: 39-44.
- 16 Novel Swine-Origin Influenza A(H1N1) Virus Investigation Team, Dawood FS, Jain S, Finelli L, et al. Emergence of a novel swine-origin influenza A (H1N1) virus in humans. *N Engl J Med* 2009; 360: 2605-15.
- 17 Remy-Jardin M, Remy J, Giraud F, Watinne L, Gosselin B. Computed tomography assessment of ground-glass opacity: seminology and significance. *J Thorac Imaging* 1993; 8: 249-64.
- 18 Mollura DJ, Carrino JA, Matuszak DL, et al. Bridging radiology and public health: the emerging field of radiologic public health informatics. *J Am Coll Radiol* 2008; 5: 174-81.