

Histopathologic Changes of Extraocular Muscle Fibers after Injection of Botulinum Toxin

A. Attarzadeh, F. Sharifi, S.M. Owji¹,
M. Eghtedari, M.R. Talebnejad

Abstract

Background: Use of botulinum toxin is becoming a popular way in treatment of some forms of strabismus. To evaluate the morphological changes in the orbital surface layer muscles of the rabbit eye following a single injection of botulinum toxin.

Methods: 10 white Dutch rabbits weighing 2–3 kg received either 10 units (group 1; n=5) or 20 units (group 2; n=5) of botulinum toxin into the superior rectus muscle of right eye. The superior rectus muscle of the left eye in each rabbit was considered as control. The diameter of at least 20 muscle fibers of the orbital layer of the superior rectus muscle was measured with an ocular micrometer on histological sections after extirpation 2 and 10 days, and 4, 8 and 12 weeks after the injection.

Results: Marked decrease in size of muscle fibers was observed, especially on 2 and 10 days post-injection. It was more severe in animals which received 20 units of the toxin. In both groups, between 4 and 12 weeks after injection, the size of some fibers returned back to normal; rarely, the fibers became hypertrophic while atrophic changes were still present. Hypertrophy of neuromuscular end-plate was seen accompanied with atrophic changes. Fibrosis around the muscle fibers was rarely seen.

Conclusion: Injection of botulinum toxin into extraocular muscles causes atrophic changes which seems to be more severe with higher doses. The effect of botulinum toxin has been persisted up to 8 weeks.

Iran J Med Sci 2007; 32(2): 80-84.

Keywords • Botulinum toxin • extraocular muscle • rabbit • myofiber

Introduction

Botulinum toxin is used in many fields of medicine including ophthalmology, plastic surgery, gynecology, etc.^{1,2} It was shown that use of botulinum toxin is an effective pharmacologic therapeutic alternative to the surgical management of strabismus.^{3,4} Paralysis is usually seen within the first two days and intensified during the first week. The paralysis lasts for weeks. The paralytic action of botulinum toxin has been attributed to blockade of neuromuscular synaptic transmission by interfering with the mechanisms related to the release of the neurotransmitter acetylcholine evoked by nerve impulses.⁵ A decrease in the calcium-dependent fusion of synaptic vesicles into the presynaptic membrane is the effect of toxin on neuromuscular transmission which is a prerequisite

Department of Ophthalmology,
¹Pathology,
Shiraz University of Medical Sciences,
Shiraz, Iran.

Correspondence:
Fatemeh Sharifi MD,
Department of Ophthalmology,
Shiraz University of Medical Sciences,
P.O. Box: 71348-43984,
Shiraz, Iran.
Tel/Fax: +98 711 6279373
Email: F_Sharify7@yahoo.com

for the quantal release of acetylcholine.⁶ Recent evidence indicates that toxin acts by proteolysis and that the blockade of neurotransmitter release induced by botulinum toxin type A is brought about through cleavage of SNAP₂₅, a synaptic membrane protein that is involved in the vesicle exocytosis process.⁷ Previous studies have demonstrated that, in short-term, paralysis with botulinum toxin results in terminal sprouting of the motor nerves.⁸ The time course of this nerve sprouting is muscle-dependent. The duration of paralysis also seems to vary, lasting from three to 12 months, although the mean duration in most long-term studies is approximately three months. These may be due to long-term or permanent structural changes in muscle fibers.⁹ In the early seventies, Duchen investigated the light microscopic and ultrastructural changes in mouse muscles and the motor endplates following injection of botulinum toxin.¹⁰ He observed a number of degenerative changes in muscle fibers which were different from those seen following surgical denervation. Furthermore, in contrast to limb skeletal muscles, little evidence of muscle atrophy has been reported after botulinum injection into the extraocular muscles (EOMs).¹¹ The particular interest will be whether botulinum toxin results only in functional blockade of neuromuscular transmission in EOM, or it can also produce myopathic changes in muscle fibers. In this study, we reported histopathologic changes in the orbital surface layer of the EOM fibers of rabbit eyes during 12 weeks following the injection of a single dose of either 10 or 20 units of botulinum toxin.

Materials and Methods

This study was performed on 10 white Dutch rabbits weighing 2–3 kg. The animals were anesthetized with intramuscular injection of 10 mg/kg of ketamine (Rotexmedic Tritan, Germany) and 2 mg/kg of xylazine (Celactar, Bayer, Tokyo, Japan). All rabbits were treated in accordance with the statements regarding the care and use of animals approved by the Association for Research in Vision and Ophthalmology Resolution on the use of animals in research and under supervision of ethics committee of Shiraz University of Medical Sciences.

Rabbits were divided into two groups. In group 1 (n=5) 0.1 mL of botulinum toxin containing 10 units (Dysport, Ipsen, Wrexham, UK) was injected under direct visualization by a 27G needle into the belly of the right superior rectus muscle, 10 mm from the insertion site. Group 2 (n=5) rabbits were given 0.1 mL containing 20 units of the toxin in the same way. Superior rectus muscle of the left eye in each rabbit, was considered as control. Two and 10 days, and 4, 8, and 12 weeks after the injections, both superior rectus muscles of one rabbit in each group were carefully disinserted from the globe and extirpated from the orbit under deep anesthesia.

The muscle was divided into two equal parts. After stretching on a filter paper to prevent shrinkage, a section was made 5mm from the insertion site. One section was fixed in 10% phosphate-buffered formalin dehydrated and embedded in paraffin. 5µm thick cross sections were prepared and stained with Hematoxylin and Eosin (H & E). Another piece of each sample, which obtained from the insertion site was fixed in 3% cacodylate buffered glutaraldehyde, post-fixed in osmium tetroxide, dehydrated through use of ascending concentrations of alcohol solutions and embedded in epoxy resin. The semithin 1-µm-thick sections were then stained with toluidine blue and examined under light microscope.

The diameter of at least 20 myofibers of the muscle was measured with an ocular micrometer on histological sections and compared with controls in the samples which were obtained two days, 10 days, 4, 8 and 12 weeks after the injection. Different histopathologic changes were searched for and recorded for each sample. Masson-Trichrom stain was used on five-µm-thick sections for evaluation of possible fibrotic changes. Data were presented as mean ± SD and analyzed with SPSS (ver 11.5). A P<0.05 was considered as statistically significant.

Results

In both study groups, the mean diameter of fibers in orbital surface layer of superior rectus muscles showed great variability after injection of botulin (table 1). Significant (p< 0.000) decrease in the size of each muscle fiber was observed, especially after two and 10 days

Table 1: The mean±SD diameter of muscle fibers of superior rectus muscle of cases treated with 10 units (group 1) and 20 units (group 2) of botulin and controls between two days and 12 weeks after injection.

Group	Time after injection of botulin				
	2 days	10 days	4 wks	8 wks	12 wks
Group 1 (10 units)	27.45±5.64	26.50±7.54	26.45±7.60	28.07±7.87	33.08±7.19
Group 2 (20 units)	23.00±8.10	23.70±7.18	24.46±9.18	25.40±6.67	32.73±7.73

The mean±SD diameter of fibers in the control group was 34.83±4.37 µm

post-injection. Although the change was more noticeable in group 2, the difference was not statistically significant (figs 1). Between four and 12 weeks post-injection in both groups, the size of some of the fibers returned back to normal; in some cases, it even become hypertrophied, while atrophic changes was still present. Hypertrophy of neuromuscular end-plate was seen concurrently with atrophic changes. Pathologic changes were associated with peripheral orientation of the sarcolemmal nuclei, increase in the endomysial and perimysial connective tissues as well as hypertrophy of the neuromuscular end-plates (fig 2). Moreover, there was endomysial infiltration of mononuclear cells in both groups, especially on day two post-injection. The cross striations of each fiber were not changed in the injected groups in comparison with controls. However, occasionally, splitting of the myofibers was seen in the injected groups.

Meanwhile, degrees of fibrosis around muscle fibers were present 8–12 weeks after injections in both groups. Masson trichrom staining confirmed perimysial fibrosis. Individual muscle fiber hypertrophy gradually became evident between four and 12 weeks post-injection. Replacement of 40% of the atrophic with hypertrophic fibers was

seen in comparison with normal muscles (15% hypertrophied fibers). The difference between each group and control was statistically significant ($p < 0.000$).

The mean diameter of fiber cells on the side treated with botulin was 28.31 μm in group 1 and 25.87 μm in group 2, on two days of injection. The value on the control side was 34.83 μm ($p < 0.001$).

On second day post-injection, 80% of fibers on the treatment side had a diameter $< 33 \mu\text{m}$, while only 25% of those on the control side were $< 33 \mu\text{m}$ which is the lower limit of normal. Between 10 days and eight weeks after injection, the toxin-treated side had a diminished fiber diameter in the orbital layer than the control side. Although the atrophic changes in cases treated with 20 unit of toxin were more pronounced, the difference between the two groups was not statistically significant.

Twelve weeks after injection, 30%–40% of muscle fibers in both toxin-treated groups had diameters $> 36.59 \mu\text{m}$ —the upper limit of 75% of normal fibers—whereas only 25% of the fibers on the control side did so; this observation indicated hypertrophic changes in treatment groups.

The intermediate layer of muscle fibers

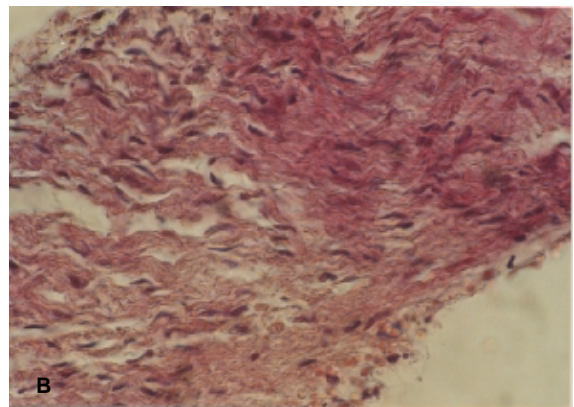
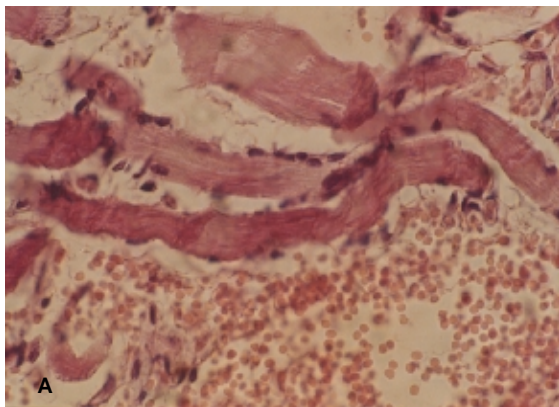


Fig 1: Histopathologic changes of the superior rectus muscle fiber after botulinum toxin injection: a) eight weeks post-injection atrophy and peripheral orientation of sarcolemmal nuclei are apparent. b) 12 weeks post-injection marked fibrosis in the perimysial connective tissue is present. (H&E $\times 400$)

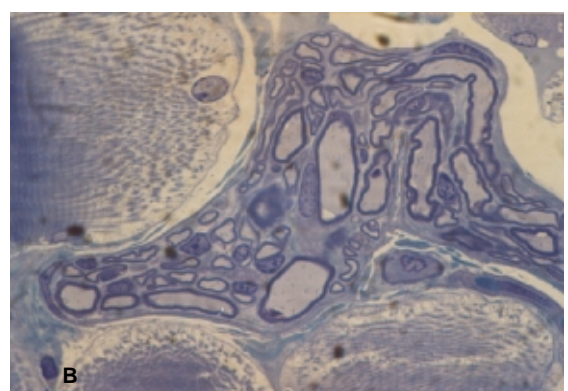
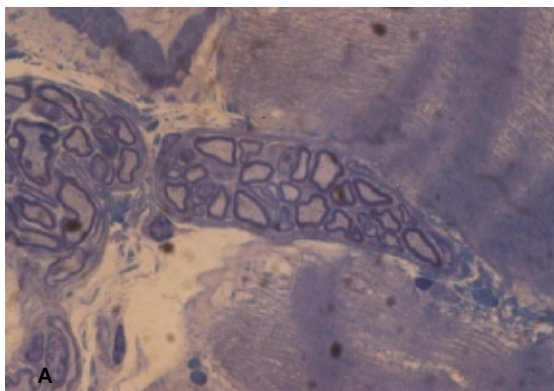


Fig 2: Neuromuscular end-plate of superior rectus muscle. a) normal muscle fiber. b) eight weeks post-injection with botulinum toxin hypertrophy of neuromuscular end-plate is apparent (toluidine blue of semi-thin plastic sections, $\times 1000$)

which normally contains relatively larger diameter fibers compared with the orbital layer, in our study, was not severely affected by botulinum toxin.

Discussion

The present study demonstrated a change in the size of EOM fibers in the rabbit after injection of botulin. The atrophic changes were intense in cases treated with 20 units rather than 10 units of toxin. Spencer and McNeer reported that orbital singly innervated muscle fibers became hypertrophied during 1–4 weeks and appeared normal 6–8 weeks after injection of the toxin in the monkey EOM.¹¹ Ohtsuki, et al, showed that fiber atrophy occurred at early stages in orbital layer and that some hypertrophy of orbital layer myofibers were detected five weeks after the injection due to recovery from the effects of toxin.¹²

In our study, muscle fibers showed changes compatible with early atrophy followed by an increase in their diameter toward the pre-injection sizes; some of them even continued their growth so that their diameter surpassed normal diameter after 12 weeks after injection and became hypertrophied. However, the bulk of muscle did not reach its original size. This is a discrepancy between our results and that reported by Spencer and McNeer with regard to the structural alternations in the orbital layer muscle fibers. One reason for this difference might be the site of sampling. Spencer and McNeer analyzed muscles in the end-plate region, while we studied the cross-section at a site 15 mm from the muscle insertion.

To the best of our knowledge, some microscopic changes observed in our study (e.g., peripheral orientation of sarcolemmal nuclei, and increase in endomysial and perimysial connective tissues) were not previously been reported.

The intermediate fibers were not been affected significantly in our study comparing with previous reports.³ Spencer and McNeer infrequently observed infiltration of mononuclear inflammatory cells while we observed frequently endomysial infiltration of mononuclear cells, especially on day two post-injection.

One study demonstrated that axonal sprouting begins within 24 hours of muscle inactivity.¹³ By eight days after toxin injection, evidence of renewed muscle activity due to neurite sprouting from the affected nerve was present. Ugalde, et al, reported that the initiation of sprouting is within 24 hours of botulinum administration which may play a role in activating the satellite cells.¹⁴ We observed hypertrophy of neuromuscular end-plates eight weeks after injection. Cross striation were lost to a variable

degree in the muscle fibers in report of Hassan, et al.¹⁵ While we observed normal cross striation in injected muscles. Late fibrosis observed in our study, has not previously been reported.

In conclusion, botulinum toxin injection into EOM of rabbit causes some atrophic changes including decrease in muscle fiber diameter, peripheral orientation of sarcolemmal nuclei, increase in endomysial and perimysial connective tissue which is more intense two to 10 days post-injection. The effects seem to be dose-dependent. Some muscle fibers would retain their normal size within two to eight weeks post-injection. While some fibers would be hypertrophied by the end of 12 weeks post-injection. Fibrosis around the muscle fibers could be a rare complication that may interfere with normal movement of muscles in long-term.

Acknowledgments

The authors would like to acknowledge Dr Nader Tanideh from Shiraz University of Medical Sciences Animal Lab for his help in managing animals and Mrs Hamideh Jabedarbashy and Miss Mahboobeh Mokhbery for their cooperation in preparing the semi-thin plastic sections from resin blocks for light microscopic study. Also, we thank Ms Marzieh Hashemi for typing the manuscript.

References

- 1 Koman LA, Mooney JF 3rd, Smith B, et al. Management of cerebral palsy with botulinum-A toxin: preliminary investigation. *J Pediatr Orthop* 1993; 13: 489-95.
- 2 Comella CL, Jankovic J, Shannon KM, et al. Comparison of botulinum toxin serotypes A and B for the treatment of cervical dystonia. *Neurology* 2005; 65: 1423-9.
- 3 Biglan AW, Burnstine RA, Rogers GL, et al. Management of strabismus with botulinum A toxin. *Ophthalmology* 1989; 96: 935-43.
- 4 Scott AB. Botulinum toxin injection into extraocular muscles as an alternative to strabismus surgery. *Ophthalmology* 1980; 87: 1044-9.
- 5 Simpson LL. The origin, structure, and pharmacological activity of botulinum toxin. *Pharmacol Rev* 1981; 33: 155-88.
- 6 Hirokawa N, Heuser JE. Structural evidence that botulinum toxin blocks neuromuscular transmission by impairing the calcium influx that normally accompanies nerve depolarization. *J Cell Biol* 1981; 88: 160-71.
- 7 Blasi J, Chapman ER, Link E, et al. Botulinum neurotoxin A selectively cleaves

- the synaptic protein SNAP-25. *Nature* 1993; 365: 160-3.
- 8 Alderson k, Holds JB, Anderson RL. Botulinum-induced alteration of nerve-muscle interaction in the human orbicularis oculi following treatment for blepharospasm. *Neurology* 1991; 41: 1800-5.
 - 9 Brin MF. Dosing, administration, and treatment algorithm for use of botulinum toxin A for adult-onset spasticity .Spasticity Study Group. *Muscle Nerve Suppl* 1997; 6: S208-20.
 - 10 Duchen LW. Changes in motor innervation and cholinesterase localization induced by botulinum toxin in skeletal muscle of the mouse: differences between fast and slow muscles. *J Neurol Neurosurg Psychiat* 1970; 33: 40-54.
 - 11 Spencer R, McNeer KW. Botulinum toxin paralysis of adult monkey extraocular muscle: Structural alterations in orbital, singly innervated muscle fibers. *Arch Ophthalmol* 1987; 105: 1703-11.
 - 12 Ohtsuki H, Hasebe S, Okano M, Furuse T. Morphological changes in the orbital surface layer muscle of the rabbit eye produced by botulinum toxin. *Ophthalmologica* 1998; 212: 53-60.
 - 13 Holds JB, Alderson K, Fogg SG, Anderson RL. Motor nerve sprouting in human orbicularis muscle after botulinum A injection. *Invest Ophthalmol Vis Sci* 1990; 31: 964-7.
 - 14 Ugalde I, Christiansen S, McLoon LK. Botulinum toxin treatment of extraocular muscles in rabbits results in increased myofiber remodeling. *Invest ophthalmol Vis Sci* 2005; 46: 4111-20.
 - 15 Hassan SM, Jennekens FG, Veldman H. Botulinum toxin-induced myopathy in the rat. *Brain* 1995; 118: 533-45.