

Asymptomatic Cardiac Hydatid Cyst

M. Jannati, M.H. Nematti, J. Zamani,¹
S. Amooee²

Abstract

Echinococcus is endemic in some parts of the world but cardiac involvement with hydatid cyst is rare. Here, we report a 55-year-old man who developed right ulnar fracture and was scheduled for surgery. During routine preoperative evaluation abnormal findings in ECG were found. In echocardiography, a large mass was detected in the inferior wall of the left ventricle. Coronary angiography showed normal findings. The patient underwent cardiac surgery to excise the mass which later on identified as a hydatid cyst.

Iran J Med Sci 2006; 31(4): 232-234.

Keywords • Echinococcus, cardiac, hydatid cyst

Introduction

Echinococcus is endemic in some areas of the world, particularly in Argentina, Uruguay, New Zealand, Greece, North Africa, and Iceland. But cardiac involvement with hydatid cyst is rare.¹ Cardiac cysts represent 0.5-2% of all hydatid cysts in humans, but they are usually associated with fatal complication.² The usual host of *Echinococcus granulosus* is dog. Sheep is the usual intermediate host, but occasionally, human may serve as an intermediate host if they accidentally ingest ova from contaminated dog feces.²

Intra myocardium of the interventricular septum or left ventricular free wall are the usual sites for cardiac cyst involvement, but occasionally right atrium or ventricle as well as tricuspid valve may be involved too.³ A myocardial cyst may degenerate and calcify, develop daughter cysts, or rupture into pericardium or the heart chambers.⁴ Rupture of the cyst is the most serious complications. Rupture of the cyst into the pericardium may induce acute or advanced chronic constrictive pericarditis.²

Rupture of the cyst into the cardiac chambers may result in systemic or pulmonary emboli. In case of right-sided cysts rapid and progressive pulmonary hypertension may occur. This is due to subsequent embolization of high numbers of scolices into the pulmonary circulation. The liberation of hydatid fluid into the circulation may also produce fatal circulatory collapse in response to anaphylactic reactions to protein constituents of the fluid.⁵ The occurrences of these symptoms depend on the location, the size, and the integrity of the cardiac cyst.

It is estimated that about 10% of those patients infected with cardiac hydatid cyst may not have any obvious clinical symptoms.¹ However, in patients with left ventricular involvement, ECG may reflect the location of the cyst by showing changes in T wave that accompanied with loss of QRS waves, while atrioventricular conduction defects, or right bundle branch blocks, may be seen with the involvement of the interventricular septum.²

Department of Surgery,
Cardiac surgery ward,
²Department of Obstetric & Gynecology,
Faghihi Hospital,
¹Department of Internal Medicine,
Cardiology ward,
Nemazee Hospital,
Shiraz University of Medical Sciences,
Shiraz, Iran.

Correspondence:

Mansour Jannati MD,
Department of Surgery,
Faghihi Hospital,
Shiraz University of Medical Sciences,
Shiraz, Iran.
Tel: +98 711 6263053
Fax: +98 711 2332365
E-mail: Janatim@sums.ac.ir

Cardiac echinococcosis may also be associated with acute myocardial infarction due to compression or complete obstruction of the coronary arteries present in the area of the cyst.³ Therefore, coronary angiography should routinely be performed in all patients with cardiac echinococcosis.

Case Report

A 55-year-old man who was completely asymptomatic scheduled for an elective orthopedic operation due to right ulnar fracture. Abnormal findings were found in his ECG (Fig 1). Echocardiography showed a large mass in the inferior wall of the left ventricle (Fig 2). Further evaluation showed normal coronary angiography, normal spleen and liver, and lack of eosinophilia.

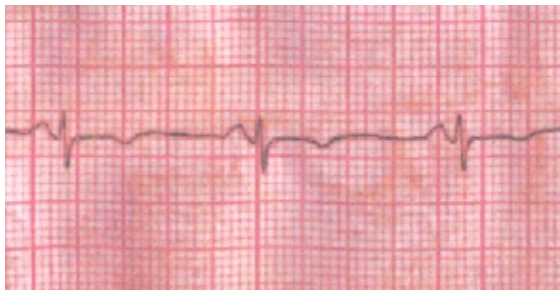


Fig 1: EKG: T inversion in Inferior leads

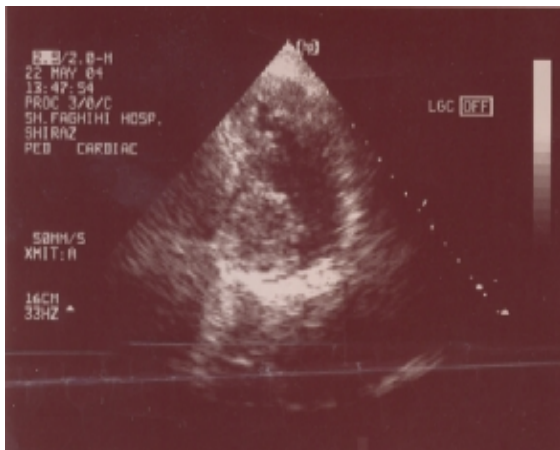


Fig 2: Echocardiography: Apical tow chamber view

The patient was operated using cardiopulmonary bypass technic with moderate systemic hypothermia (25-30°C). The heart was arrested by infusion of cold cardioplegic solution to excise the large mass of hydatid cyst that was attached to the left ventricular wall. Post-operative course was without incident and the patient was discharged from the hospital after seven days. He was advised to take albendazole for five years and have a routine follow up by a cardiologist.

Discussion

Echinococcus is endemic in many parts of the world, but cardiac involvement with hydatid cyst is uncommon, occurring in less than 2% of cases.¹ Cardiac echinococcosis is mostly symptomatic. These symptoms include angina because of the pressure effects of the cyst on the coronary arteries, dyspnea, and palpitation.^{4,6}

Mortality rates of asymptomatic cases of cardiac cyst involvement, following perforation of the cyst, are relatively high.^{4,6} This due to acute anaphylactic reactions and cardiogenic shocks, which may occur in these patients. Nardo and colleagues reported a symptomatic case of cardiac involvement who presented with Q and T negative waves in the inferior leads.⁷

In the past decades, the treatment of hydatid disease has been limited to surgical excision,⁸ Nonetheless, new experiences suggest that benzimidazole derivatives such as albendazole or mebendazole, are useful drugs for the treatment of hydatid cyst.⁹ Guven and colleagues reported a asymptomatic case which was successfully treated with albendazole.¹⁰

Despite the availability of valuable medical treatments, the adjunctive surgical excision is generally recommended for both symptomatic and asymptomatic patients. This is because of the high risk of rupture of the cyst and its serious consequences.¹

Our patient, because of the possible sever complications of rupture of the cyst, was in a dangerous condition. Therefore, we surgically removed the cyst to prevent the systemic emboli and fatal circulatory collapse, which may occur in such cases.⁶ We also recommended him to take albendazole for a period of five years to prevent the possibility of recurrences of the cyst.

Therefore, the presence of Q waves and T negative waves in the inferior leads, even in the absence of cardiac ischemic symptoms, in patients living in endemic regions should be suspected for echinococcosis.

References

- 1 Salih ok, Celik Sk, Topcuoglu MS, et al. Surgical treatment of hydatid cysts of the heart: A report of 3 cases and a review of the literature. *Can J Surg* 1998; 41: 321-7.
- 2 Iglesias Lf, Zabalay Morales M, Marcos G, et al. Pericarditis secondary to the rupture of a hydatid cyst. *Rev Esp cardiol* 1999; 52: 135-8.
- 3 De paulis R, Seddio F, Colagrande L, et al. Cardiac echinococcosis causing coronary

- artery disease . *Ann Thorac Surg* 1999; 67: 1791-3.
- 4 Kucukarslan N, Savas Oz B, Demirkilic U, Tatar H. An asymptomatic cardiac echinococcus cyst case. *The Internet Journal of Thoracic and Cardiovascular Surgery* 2005; 7.
 - 5 Ozer N, Aytemir K, kuru G, et al. Hydatid cyst of the heart as a rare cause of embolization: report of 5 cases and review of published reports. *J Am Soc Echocardiogr* 2001; 14: 299-302.
 - 6 Kaplan M, Demirtas M, Cimen S, Qzler A. Cardiac hydatid Cysts with intracavitary expansion. *Ann Thorac Surg* 2001; 71: 1587-90.
 - 7 De Nardo A, Monea P, Adornato EM. Multiple intracardiac hydatid cysts with clinical picture simulating mitral stenosis and inferior myocardial necrosis. *G Ital Cardiol* 1999; 29: 1218-21.
 - 8 Miralles A, Bracamonte L, Pavie A, et al. Cardiac echinococcosis. Surgical treatment and results. *J Thorac cardisvasc Surg* 1994; 107: 184-90.
 - 9 Franchi C, Di Vico B, Teggi A. Long-term evaluation of patients with hydatidosis treated with benzimidazole carbamates. *Clin Infect Dis* 1999; 29: 304-9.
 - 10 Guven A, Sokmen G, Yuksel M, et al. A case of asymptomatic cardiopericardial hydatid cyst. *Jpn Heart J* 2004; 45: 541-5.