

Hereditary Spherocytosis Unmasked by Human Parvovirus B19 Induced Aplastic Crisis in a Family

Samin Alavi¹, MD;
Nahid Arabi¹, MD;
Mohammad Kaji Yazdi¹, MD;
Mohammad Taghi Arzani¹, MD;
Farahnaz Zohrehbandian², MSc

Abstract

Human parvovirus (HPV) B19 induced aplastic crisis in a family leading to the diagnosis of hereditary spherocytosis (HS) is a very rare condition being barely reported in the literature. We herein report a 4-year-old girl, her brother, and their mother who all presented with progressive pallor and jaundice after a febrile illness. The HPV B19 was diagnosed using polymerase chain reaction (PCR) and positive serology for specific anti-HPV B19 IgM. They were further diagnosed with having HS. The clinical importance of this report is that in the case of an abrupt onset of unexplained severe anemia and jaundice, one should consider underlying hemolytic anemias mostly hereditary spherocytosis complicated by HPV B19 aplastic crisis. Herein, we report the occurrence of this condition, simultaneously in three members of a family. The distinguished feature of this report is that all affected family members developed some degrees of transient pancytopenia, not only anemia, all simultaneously in the course of their disease.

Please cite this article as: Alavi S, Arabi N, Yazdi MK, Arzani MT, Zohrehbandian F. Hereditary Spherocytosis Unmasked by Human Parvovirus B19 Induced Aplastic Crisis in a Family. *Iran J Med Sci.* 2015;40(5):461-464.

Keywords • Hereditary spherocytosis • Parvovirus B19 • Pancytopenia

Introduction

Human parvovirus (HPV) B19, being first discovered and introduced in 1975, is a non-enveloped single-stranded DNA virus from the Parvoviridae family.¹ The virus is transmitted by respiratory droplets and the prevalence is estimated to be high since most of the individuals are infected by the age of 15.² The clinical syndrome associated with HPV B19 strongly depends on the host; for instance those suffering from hemolytic disorders, including sickle cell disease, hereditary spherocytosis (HS), autoimmune hemolysis, thalassemias, and paroxysmal nocturnal hemoglobinuria (PNH) are susceptible to aplastic crisis.² The virus has a predilection for infecting the erythroid progenitor cells of the bone marrow resulting in their lysis and aplastic anemia.² Thus, the bone marrow in these patients appears without erythroid precursors but with normal myeloid series.³

The HPV B19 induced aplastic crisis can unmask several hereditary hematological disorders that have been normally compensated. Among these conditions, HS has been extensively reported.⁴⁻⁶ When HPV B19 infects the bone marrow erythroid cells of these patients, decompensation occurs and thus the patient presents with signs and symptoms of abrupt onset severe anemia.⁴⁻⁶ Several similar sporadic cases have been reported

¹Pediatric Congenital Hematologic Disorders Research Center, Mofid Children's Hospital, Shahid Beheshti University of Medical Sciences, Tehran, Iran;

²Keyvan Virology Laboratory, Tehran, Iran

Correspondence:

Samin Alavi, MD;
Mofid Children's Hospital,
Dr Shariati Ave, Opposite Hosseinieh
Ershad, Tehran, Iran
P.O. Box: 15468-15514

Tel: +98 21 22227020

Fax: +98 21 22220254

Email: s.alavi@sbmu.ac.ir

Received: 07 August 2013

Revised: 30 September 2013

Accepted: 17 November 2013

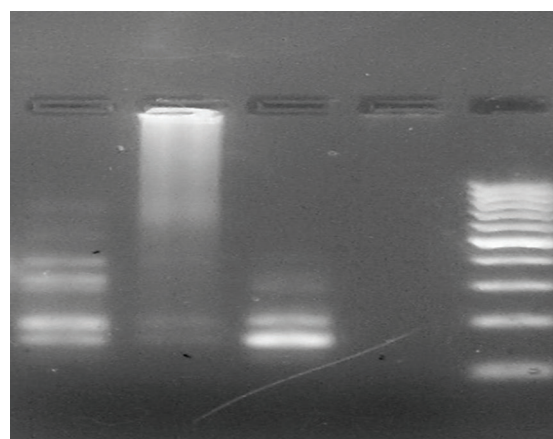
by now, but familial HPV B19 induced aplastic crisis leading to the diagnosis of HS in all family members is a very rare condition being only reported three times in the literature.⁷⁻⁹ We herein, report HPV B19 induced aplastic crisis in an asymptomatic and undiagnosed family of three with HS demonstrating pancytopenia on peripheral blood.

Case Report

A 3.5-year-old girl, the youngest child of a 4-member family, was presented with severe pallor and high fever without localizing sign with 5 days duration. On physical examination, she had jaundice in the sclera and the spleen was palpable about 3 cm below the costal margin. Family history was negative for consanguinity in parents. Her mother also looked pale with icteric sclera. There was a positive history of splenectomy in her grandmother. The following day, her 14-year-old brother presented with high fever of unknown origin and severe pallor. On physical examination, he was febrile (39 °C) and had a mild prominence of frontal and maxillary bones and jaundiced sclera. The spleen was enlarged to the level of the umbilicus. His past-history was negative for any medical illnesses. Four days later, their mother developed aggravation in her pallor and jaundice. Physical examination revealed an enlarged spleen with the tip of spleen palpated about 3 cm below the costal margins. The hematological indices of these three patients are summarized in Table 1.

According to the family history and positive findings on physical examination (jaundice and splenomegaly), a work-up for hemolytic anemias, including Hb electrophoresis, osmotic fragility, and autohemolysis test was performed for each patient. The results were consistent with the diagnosis of HS. Knowing HPV B19 as the most common causative agent in the development of aplastic crisis in hemolytic anemias; specifically hereditary spherocytosis polymerase chain reaction (PCR) for HPV B19, DNA was performed which was positive in all three patients (Figures 1 and 2). Their sera were also found to be positive for specific anti-HPV B19 IgM. Bone marrow aspiration

of the girl revealed normal marrow cellularity with mild erythroid hyperplasia and clusters of erythroid nests heralding the recovery of the erythroid series already affected by parvovirus B 19 infection. In contrary, cellularity was severely decreased in all three lineages in the boy implicating suppression of all hematopoietic lineages. Both siblings received intravenous immunoglobulin (IVIG) in a dosage of 1 gr/kg along with blood transfusion, twice for each. The girl recovered after 3 days with reticulocytosis of 16%, while the boy recovered 8 days later with reticulocytosis of 8%. Their mother also had to receive blood transfusion because of having Hb of 3.6 gr/dL. The boy and his mother had splenectomy done after 2 months.



Sister Brother Control+ Control- ladder 100 bp

Figure 1: PCR for parvovirus B19. From left to right; the siblings, their positive and negative control, and the ladder.

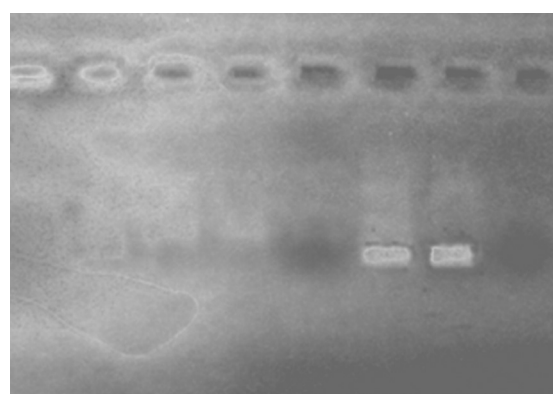


Figure 2: PCR of the mother and positive control.

Table 1: The hematological indices of the three patients admitted to our department with severe pallor and fever of unknown origin

Indicies	WBC (×10 ⁹ /μL)	Hb (mg/dL)	RBC (×10 ⁹ /μL)	Platelet (μL)	Reticulocyte (%)
Girl	7500	3.3	1.7	237,000	0.1
Boy (1 day after)	1900	4.6	2.2	75,000	<1.0
Mother (4 days later)	2500	3.6	–	90,000	0.5

Discussion

These family members were typical examples of the occurrence of aplastic crisis due to HPV B 19 complicating HS simultaneously in a family. Only three previous reports have shown that HPV B19 can induce aplastic crisis and unmask the HS in a family. Previously, Green et al.⁷ in 1984 reported an adult sibling pair with HS who developed aplastic crisis after a febrile illness, which was further diagnosed to be HPV B19 infection. The diagnosis of HPV B19 was developed based on specific IgM antibody in their sera, as PCR was not available. They also found that the children of one of the patients also developed HPV B19 induced aplastic crisis, which was resolved with supportive care. These two adult patients were treated by blood transfusion and supportive care and were discharged after 6-8 days of hospital care.⁷ In a similar report, McLellan and Rutter in 1987 reported HPV B19 induced aplastic crisis in two teenage sisters leading to the diagnosis of HS.⁸ They both presented with progressive fatigue, dizziness and pallor after a febrile illness. They also had a history of splenectomy in their mother at the age of 11 years. They both were diagnosed to have HPV B19 and underwent splenectomy and supportive care until recovery. In 1962, Chanarin et al. reported aplastic crisis in 3 members of a family (2 sisters and the father).⁹ The 10-year-old girl presented with 7 days history of fever of unknown origin, jaundice, and dark urine. The same illness was reported in 2-year-old sister and 32-year-old father who both had HS. The 10-year-old girl was treated with repeated transfusions, splenectomy, and supportive care for 92 days. Based on laboratory investigations, the authors first assumed that the megaloblastic hematopoiesis accompanied by urinary excretion of large amounts of urocanic acid following oral dose of histidine hydrochloride was responsible for aplastic crisis in these patients with HS. However, the authors reached the conclusion that HPV B19 was responsible for the aplastic crisis in this family with HS. As HPV B19 was first discovered in 1975¹ and this family was reported in 1962,⁹ thus the etiology was misdiagnosed.

In the present study, we described a family with HS that all three members developed aplastic crisis secondary to HPV B19 infection leading to the detection of asymptomatic HS. These patients were members of the same household contacts. Those patients with HS, who remain undiagnosed, usually have mild hemolysis and the disease remains undiagnosed until the compensation is interrupted because of some environmental stressors such as infections.⁴⁻⁶

The distinguished feature of our report is the occurrence of some degrees of leukopenia, neutropenia and thrombocytopenia in two of our patients (the mother and his son). There are few reports of mild transient pancytopenia due to HPV B19 infection^{10,11} and recent report on persistent severe aplastic anemia in a previously healthy adult.¹² However, none of them occurred in members of a single family and one of them was persistent in a healthy subject.

One of the theories behind the etiology of transient pancytopenia in HPV B19 infections is that the virus could be responsible for the temporary arrest of hematopoiesis that leads to aplastic crisis in persons with chronic hemolytic anemia. The other hypothesis is the occurrence of HPV-associated hemophagocytosis leading to pancytopenia.^{13,14} Among our three patients, two showed transient pancytopenia with more severity in the 14-year-old boy; nevertheless, they didn't show any evidence of hemophagocytosis in bone marrow aspirate.

According to available reports in the literature indicating probable efficacy of IVIG in the treatment of patients with HPV B19 infections and its effect on replication on virus, IVIG was applied in two cases.^{15,16} However, we cannot draw any conclusion on whether the fast recovery of the patients was a positive impact of IVIG or spontaneous recovery of HPV B 19 that is expected in HS patients, albeit happened very soon in our patients.

Conclusion

HPV B19 induced aplastic crisis in a family leading to the diagnosis of hereditary HS is a very rare reported event in the literature. The distinguished feature of this report is that all affected members of a family developed some degrees of transient pancytopenia, not only anemia, all simultaneously in the course of their disease. However, it was transient and the recovery happened very soon in all of them within 10 days, which was attributed to the usage of IVIG.

Conflicts of Interest: None declared.

References

1. Cossart YE, Field AM, Cant B, Widdows D. Parvovirus-like particles in human sera. *Lancet*. 1975;1:72-3. doi: 10.1016/S0140-6736(75)91074-0. PubMed PMID: 46024.
2. Servant-Delmas A, Lefrere JJ, Morinet F, Pillet S. Advances in human B19 erythrovirus biology. *J virol*. 2010;84:9658-65.

- doi: 10.1128/JVI.00684-10. PubMed PMID: 20631151; PubMed Central PMCID: PMC2937825.
3. Gallagher PG FB. Hereditary Spherocytosis, Elliptocytosis, and Related Disorders. In: Beutler E CB, Lichtman AM, Kipps TJ, Seligsohn U, editors. *Williams Hematology*. New York: McGraw-Hill; 2001. p. 508-39.
 4. Carzavec D, Gaćina P, Vasilj A, Katović SK. Aplastic crisis induced by human parvovirus B19 as an initial presentation of hereditary spherocytosis. *Coll Antropol*. 2010;34:619-21. PubMed PMID: 20698139.
 5. Tavit B, Ozdel S, Ozkasap S, Yarali N, Tunc B. Aplastic crisis induced by human parvovirus B19 infection as an initial presentation of hereditary spherocytosis. *Indian J pediatr*. 2010;77:1191-2. doi: 10.1007/s12098-010-0204-0. PubMed PMID: 20872096.
 6. Oh SE, Kim JH, Choi CH, Park KH, Jung JY, Park YL, et al. An adult with aplastic crisis induced by human parvovirus B19 as an initial presentation of hereditary spherocytosis. *Korean J Intern Med*. 2005;20:96-9. PubMed PMID: 15906963; PubMed Central PMCID: PMC3891423.
 7. Green DH, Bellingham AJ, Anderson MJ. Parvovirus infection in a family associated with aplastic crisis in an affected sibling pair with hereditary spherocytosis. *J clin pathol*. 1984;37:1144-6. doi: 10.1136/jcp.37.10.1144. PubMed PMID: 6092438; PubMed Central PMCID: PMC498956.
 8. McLellan NJ, Rutter N. Hereditary spherocytosis in sisters unmasked by parvovirus infection. *Postgrad Med J*. 1987;63:49-50. doi: 10.1136/pgmj.63.735.49. PubMed PMID: 2823243; PubMed Central PMCID: PMC2428214.
 9. Chanarin I, Burman D, Bennett MC. The familial aplastic crisis in hereditary spherocytosis. Urocanic acid and formiminoglutamic acid excretion studies in a case with megaloblastic arrest. *Blood*. 1962;20:33-40. PubMed PMID: 13878015.
 10. Anderson MJ, Higgins PG, Davis LR, Willman JS, Jones SE, Kidd IM, et al. Experimental parvoviral infection in humans. *J Infect Dis*. 1985;152:257-65. doi: 10.1097/00006454-198601000-00036. PubMed PMID: 2993431.
 11. Hanada T, Koike K, Takeya T, Nagasawa T, Matsunaga Y, Takita H. Human parvovirus B19-induced transient pancytopenia in a child with hereditary spherocytosis. *Br J Haematol*. 1988;70:113-5. PubMed PMID: 2846031.
 12. Rajput R, Sehgal A, Jain D, Sen R, Gupta A. Acute Parvovirus B19 Infection Leading to Severe Aplastic Anemia in a Previously Healthy Adult Female. *Indian J Hematol Transfus*. 2012;28:123-6. doi: 10.1007/s12288-011-0112-0. PubMed PMID: 23730023; PubMed Central PMCID: PMC3332267.
 13. Boruchoff SE, Woda BA, Pihan GA, Durbin WA, Burstein D, Blacklow NR. Parvovirus B19-associated hemophagocytic syndrome. *Arch Intern Med*. 1990;150:897-9. doi: 10.1001/archinte.1990.00390160137028. PubMed PMID: 2158284.
 14. Yilmaz S, Oren H, Demircioğlu F, Firinci F, Korkmaz A, Irken G. Parvovirus B19: a cause for aplastic crisis and hemophagocytic lymphohistiocytosis. *Pediatr Blood cancer*. 2006;47:861. doi: 10.1002/psc.20807. PubMed PMID: 16514614.
 15. Crabol Y, Terrier B, Rozenberg F, Pestre V, Legendre C, Hermine O, et al. Intravenous immunoglobulin therapy for pure red cell aplasia related to human parvovirus b19 infection: a retrospective study of 10 patients and review of the literature. *Clin Infect Dis*. 2013;56:968-77. doi: 10.1093/cid/cis1046. PubMed PMID: 23243178.
 16. Koduri PR, Kumapley R, Valladares J, Teter C. Chronic pure red cell aplasia caused by parvovirus B19 in AIDS: use of intravenous immunoglobulin—a report of eight patients. *Am J Hematol*. 1999;61:16-20. PubMed PMID: 10331506.