

Giant Chondroid Syringoma of the Upper Nasal Orbital Rim

E. Shirzadeh, A.R. Ghasemi Aryan

Abstract

The present study describes clinical manifestation, histopathologic findings and differential diagnosis of a first-reported case of giant chondroid syringoma (CS) of the upper nasal orbital rim. A 35-yr-old man with cranial palsy (CP) and a tumor of 3×3×4 cm in the upper nasal orbital rim of the left eye was referred to the eye clinic. The tumor was reported to have developed gradually over the years. It was removed under general anesthesia and no recurrence was observed during the one-year follow-up without any complaint from the patient. Macroscopic examination showed a whitish, irregular and relatively soft nodule of 3×2.5×2 cm. and with calcificated spots on its section. Microscopically, tubules of various sizes were observed which were surrounded by cellular stroma and distinct areas of chondroid proliferation with no malignant changes. CS may assume a giant size, appearing as hard, slow-developing cutaneous and subcutaneous nodules on differential diagnosis. Despite favorable prognosis, the recurrence of CS is reported only in those patients whose tumors are not completely removed.

Iran J Med Sci 2004; 29(4):192-194.

Keywords • Chondroid • Syringoma • Benign Mixed • Supraorbital

Introduction

Chondroid syringoma (CS) or benign mixed tumor of the skin is an uncommon and subcutaneous tumor composed of pleomorphic components of both epithelial and mesenchymal appearance which can be mistaken for other nodular disorders of the skin.^{1,2} It originates in the sweat glands, usually occurring more in head and neck than in other areas with its surgery being elective.³⁻⁵ Its incidence in men is twice that of women. It is usually found as a painless subcutaneous mass and desired to be removed due to cosmetic reasons.

Case presentation

This report is meant to present the clinical manifestations, histopathologic findings and differential diagnosis of a giant CS of the upper nasal orbital rim in the left eye which to our knowledge is the first case to be reported. The patient was a 35-yr-old man with cranial palsy (CP), slight mental retardation and residing in a village of Sabzevar, Iran. He suffered, for years, from a relatively large mass of 3×3×4 cm at the upper nasal orbital rim with extension toward nasal bridge and was referred to the clinic. The tumor had developed gradually. Upon clinical examination, it appeared as a relatively hard mass, having

Department of Ophthalmology
Sabzevar School of Medical Sciences,
Sabzevar, Iran

Correspondence:
Ebrahim Shirzadeh MD
Department of Ophthalmology
Sabzevar School of Medical Sciences,
Sabzevar, Iran
Tel: +98 571 2226700
Fax: +98 571 2221523
E-mail: dreshirzad@yahoo.com

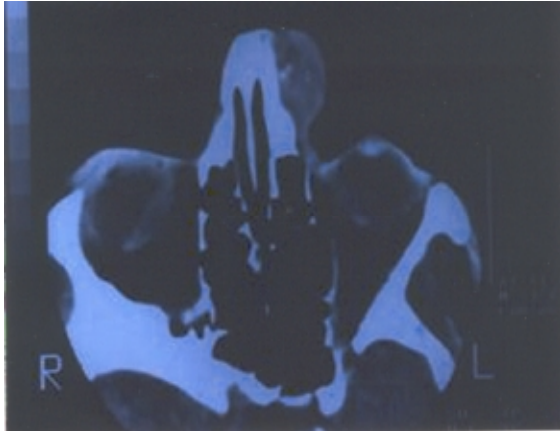

Fig1: Calcification of the tumor without any defect or bone reaction.

the same color as the skin and almost a clear border which was loosely attached to underlying tissue. The encapsulated tumor was completely removed under general anesthesia for cosmetic reasons. The mass which appeared to be lobulated and yellowish with a relatively hard consistency was sent to the laboratory for histopathological examination.

On CT-scan examination from both axial and coronal views, no defect and bone reaction was observed at the locus of the tumor (Fig. 1). Macroscopically, the tumor appeared as a relatively soft, irregular, creamy color nodule measuring 3×2.5×4 cm, with calcified spots found on its section. However, microscopic examination of the tumors showed a combination of tubules of different sizes surrounded by cellular stroma and distinct areas of chondroid proliferation without any malignant changes (Fig 2).

Discussion

Numerous skin and subcutaneous tumors including tumors originating from sweat glands have already been described. Chondroid syringoma is an uncommon tumor originating from eccrine or apocrine glands which is usually overlooked at first glance. This term was first used by Hirsh and Helwing instead of pleomorphic adenoma of the skin.⁶

These tumors are usually found in sizes smaller than 4-5 mm and often in colorless or yellowish small nodules in head and neck.¹ Its Giant type measuring 8×7×6.5 cm is a relatively rare tumor which was found in the axilla of a 64-yr-old man by Harrison and colleagues.⁷ De Fata and colleagues also reported a giant scrotum CS measuring 4.2 cm in a 76-yr-old man.³ In addition, a giant mixed tumor of 6 cm diameter was described by Kakuta M and colleagues.⁸ It has also been frequently reported to occur in cheek,⁸ eyelid,^{6,9}

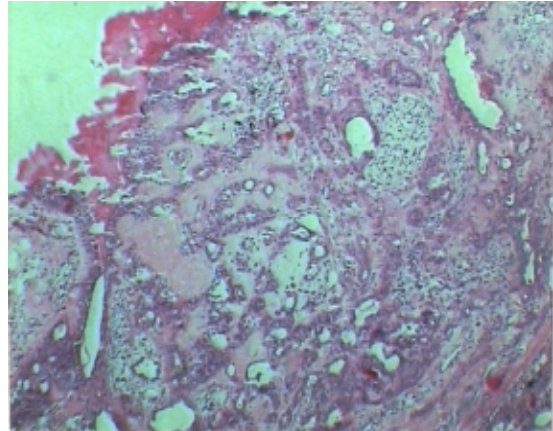


Fig2: (H&E stain-100x) A combination of tubules, cellular stroma fibroblast and chondrocyte cells with ossificated areas.

upper lip,¹⁰ and nose.¹¹ However, to our knowledge this is the first report of a mixed tumor of the upper nasal orbital rim which is the second common site and virtually constituted ¼ of all dermoid cysts.¹²

The present case was initially diagnosed as dermoid cyst but was subsequently shown to be a CS by histopathologic examination. Therefore, it is to be considered in the differential diagnosis of dermoid cysts, lipoma, pilar cyst, etc.¹³

In conclusion chondroid syringoma is an uncommon tumor and is usually overlooked on primary examinations. It may be considered as dermoid cyst by an ophthalmologist by virtue of its upper orbital locus, but due to some malignant changes and metastasis observed in rare cases, chondroid syringoma must be considered in diagnosing rare tumors.

References

- 1 Tasman W, Jaeger EA. Mixed tumor. In: Duane's clinical ophthalmology. Philadelphia: Lippincott-Raven Publishers Inc. 2001.
- 2 Yavuzer R, Basterzi Y, Sari A, Bir F, et al. Chondroid syringoma: a diagnosis more frequent than expected. *Dermatol Surg* 2003; **29**: 179-81.
- 3 De Fata Chillon FR, Nistal Martin M, Nunez Mora C, et al. Giant chondroid syringoma of the scrotum: First reported case. *Arch Esp Urol* 200; **54**: 1121-3.
- 4 Sheikh SS, Pennanen M, Montgomery E. Benign chondroid syringoma: report of a case clinically mimicking a malignant neoplasm. *J Surg Oncol* 2000; **73**: 228-30.
- 5 Schiano di Visconte M, Picciano P. Chondroid syringoma. *Chir Ital* 2002; **54**: 241-4.
- 6 Tyagi N, Abdi U, Tyagi SP, Maheshwari V, et al. Pleomorphic adenoma of skin (chon-

- droid syringoma) involving the eyelid. *J Postgrad Med* 1996; **42**: 125-6.
- 7 Hardisson D, Linares MD, Nistal M. Giant chondroid syringoma of the axilla. *J Cutan Med Surg* 1998; **3**: 115-7.
 - 8 Kakuta M, Tsuboi R, Yamazaki M, et al. Giant mixed tumor of the face. *J Dermatol* 1996; **23**: 369-71.
 - 9 Martorina M, Capoferri C, Dessanti P. Chondroid syringoma of the eyelid. *Int Ophthalmol* 1993; **17**: 285-8.
 - 10 Adlam DM, Wood GA. The chondroid syringoma (mixed tumor of skin): Report of a case in the upper lip. *Oral Surg Oral Med Oral Pathol* 1986; **61**: 69-72.
 - 11 Bhargava D, Bhusnurmath S, Daar AS. Chondroid syringoma of the nose: report of a case. *J Laryngol Otol* 1997; **111**: 862-4.
 - 12 American Academy of Ophthalmology, American Association for Pediatric Ophthalmology and Strabismus. 1994; Sec 6, 147.
 - 13 Bekerecioglu M, Tercan M, Karakok M, Atik B. Benign chondroid syringoma: a confusing clinical diagnosis. *European J Plastic Surg* 2002; **25**: 316-8.