

# Charcot-Leyden Crystals in Hodgkin's Lymphoma

M.J. Ashraf, N. Azarpira, B. Khademi<sup>1</sup>

## Abstract

Herein, we reported on a middle-aged woman presented with painless cervical lymphadenopathy. Past medical history was not significant. Pathologic examination of incisional biopsy show partial effacement of lymph node architecture with many reactive inflammatory cells admixed with Reed-Sternberg cells, many Charcot-Leyden crystals, and noncaseating granuloma. Immunohistochemical staining was positive for the classic Reed-Sternberg cells for CD15 and CD30 and was negative for CD45 and CD20. All these findings confirmed the diagnosis of Hodgkin's lymphoma. Charcot-Leyden crystals, is considered a morphologic hallmark of eosinophil-related diseases. However, to the best of our knowledge, only one case of Hodgkin's lymphoma has been reported in the world literature who has had Charcot-Leyden crystals.

**Iran J Med Sci 2007; 32(2): 124-126.**

**Keywords** • Charcot-Leyden crystal protein • Hodgkin's disease • Reed-Sternberg cells • eosinophils

## Introduction

**C**harcot-Leyden crystals are usually seen when many eosinophils are present. Lysophospholipase protein expressed by eosinophils and basophils, is the sole protein component of these crystals.<sup>1,2</sup> Charcot-Leyden crystals are commonly seen in reactive or neoplastic conditions accompany eosinophilia. These conditions include allergic asthma, allergic fungal sinusitis,<sup>1</sup> eosinophilic colitis,<sup>3</sup> visceral larva migrans,<sup>4</sup> Langerhans cell histiocytosis,<sup>5</sup> acute myelogenous leukemia,<sup>6</sup> and chronic eosinophilic leukemia.<sup>7,8</sup> Herein, we reported a case of Hodgkin's lymphoma who presented with Charcot-Leyden crystals.

## Case Presentation

A 30-year-old woman presented with painless neck mass and low grade fever since one month before. In physical examination, the patient was febrile and had a nontender firm enlarged superficial cervical lymph node. No axillary or inguinal lymphadenopathy was found. She had no organomegaly too. Chest x-ray was normal with no mediastinal widening. The incisional biopsy of the lesion was performed.

## Gross Pathology

The specimen consisted of a lymph node measured 3×2×1 cm. In cut-section it was soft with degrees of focal nodularity.

## Histologic findings

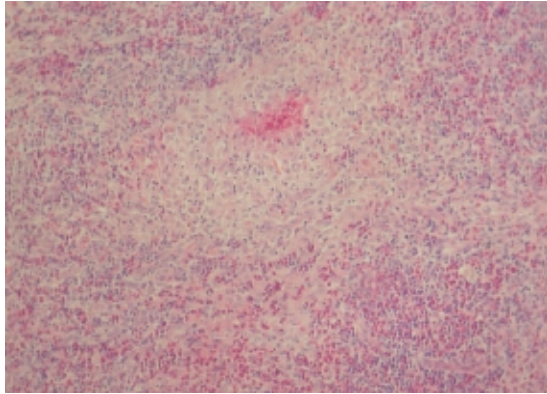
The architecture of lymph node was partially effaced by large number of eosinophils, plasma cells, lymphocytes and

Departments of Pathology,  
<sup>1</sup>Otolaryngology,  
Shiraz University of Medical Sciences,  
Shiraz, Iran.

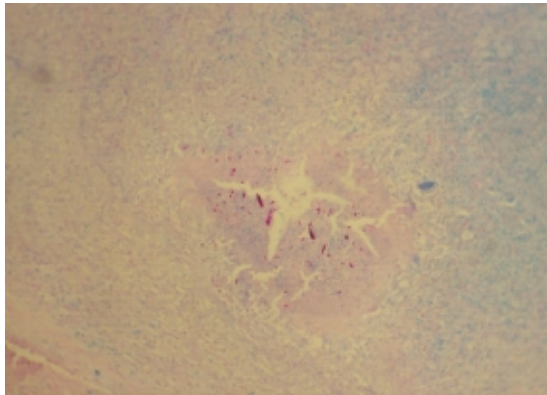
## Correspondence:

Negar Azarpira MD,  
Transplant Research Center,  
Nemazi Hospital,  
Shiraz University of Medical Sciences,  
Shiraz, Iran.  
**Tel/Fax:** +98 711 6276211  
**Email:** [negarazarpira@yahoo.com](mailto:negarazarpira@yahoo.com)

atypical mononuclear cells which were admixed with classic Reed-Sternberg cells, many Charcot-Leyden crystals, and focally non-caseating granuloma (fig 1). No acid-fast bacilli were seen (fig 2).



**Fig 1:** Aggregation of epithelioid histiocytes and lymphocytes as noncaseating granuloma (H&E, ×100).



**Fig 2:** Charcot-Leyden crystals are best seen in acid fast stain. (Modified Ziehl-Neelsen, ×100).

#### Immunohistochemical staining

The sections were immunostained by streptavidin-biotin method with antibodies against CD15, CD30, CD45, CD20 (pre-diluted, DAKO, antimouse). The classic Reed-Sternberg cells became positive for CD15 and CD30 and gave negative results for CD45 and CD20. The reactive component of the tumor contained numerous T lymphocytes.

#### Diagnosis and Treatment

Based on all these data, the diagnosis of Hodgkin's lymphoma was made and the patient was treated with chemotherapy which resulted in excellent response.

#### Discussion

To the best of our knowledge, only one case of Hodgkin's lymphoma has been reported in the world literature who has had Charcot-Leyden crystals.<sup>9</sup>

Hodgkin's lymphoma is a malignancy of B cells.<sup>10</sup> The distinctive tumor giant cells known

as Reed-Sternberg cells, is a histologic hallmark of Hodgkin's lymphoma. These cells are usually admixed with a variable infiltrate of reactive, non-malignant inflammatory cells. Hodgkin's lymphoma usually associates with somewhat distinctive clinical manifestations such as fever.<sup>10</sup>

Granuloma formation may be seen in Hodgkin's lymphoma due to immunologic reactions.<sup>11,12</sup> However, to rule out infection with *Mycobacterium* spp—as a cause of granulomatous reaction—modified Ziehl-Neelsen stain was also performed to detect any acid-fast bacilli present. Interestingly, the Charcot-Leyden crystals stained very well in this stain (fig 2).

One finding which was unique to our patient was the existence of Charcot-Leyden crystals in an inflammatory background with presence of many eosinophils. The major component of these crystals is a protein with lysophospholipase activity and carbohydrate-binding properties which is a characteristic constituent of eosinophils and basophils. Eosinophil progenitors, mature eosinophils and basophils all have this protein.<sup>13</sup> These bipyramidal-shaped crystals are considered as a morphologic hallmark of eosinophil-related disease, and are often found in inflamed nasal tissue and paranasal sinus contents of patients with allergic rhinitis.<sup>1</sup> These crystals, which representing the breakdown products of degranulated eosinophils, were reported in few benign and malignant conditions such as eosinophilic colitis,<sup>3</sup> visceral larva migrans,<sup>4</sup> eosinophilic sarcoma,<sup>7</sup> acute myelogenous leukemia,<sup>6</sup> and chronic eosinophilic leukemia.<sup>8</sup> Nevertheless, we could not explain the mechanism of their genesis in our patient. The presence of Charcot-Leyden crystal in patients with Hodgkin's lymphoma which is not an eosinophil-related disease, questions the current theories on genesis of these crystals and the environment these crystals are made in.

#### References

- 1 Pantanowitz L, Balogh K. Charcot-Leyden crystals: pathology and diagnostic utility. *Ear Nose Throat J* 2004; 83: 489-90
- 2 Leonidas DD, Elbert BL, Zhou Z, et al. Crystal structure of human Charcot-Leyden crystal protein, an eosinophil lysophospholipase, identifies it as a new member of the carbohydrate-binding family of galectins. *Structure* 1995 15; 3: 1379-93.
- 3 Lewis JT, Candelora JN, Hogan RB, Briggs FR, Abraham SC. Crystal-storing histiocytosis due to massive accumulation of charcot-leyden crystals: a unique association

- producing colonic polyposis in a 78-year-old woman with eosinophilic colitis. *Am J Surg Pathol* 2007; 31: 481-5.
- 4 Leone N, Baronio M, Todros L, et al. Hepatic involvement in larva migrans of *Toxocara canis*: report of a case with pathological and radiological findings. *Dig Liver Dis* 2006; 38: 511-4.
  - 5 Kumar PV, Mousavi A, Karimi M, Bedayat GR. Fine needle aspiration of Langerhans cell histiocytosis of the lymph nodes. A report of six cases. *Acta Cytol* 2002; 46: 753-6.
  - 6 Rubin A, Crawford S. Charcot-Leyden crystals in fine needle aspiration (FNA) cytology of acute myeloid leukemia. *Cytopathology* 1997; 8: 211-3.
  - 7 Strauchen JA, Gordon RE. Crystallin inclusion in granulocytic sarcoma. *Arch Pathol Lab Med* 2002; 126: 85-6.
  - 8 Kuk JS, Maceachern JA, Soamboonsrup P, et al. Chronic eosinophilic leukemia presenting with autoimmune hemolytic anemia and erythrophagocytosis by eosinophils. *Am J Hematol* 2006; 81: 458-61.
  - 9 Carson HJ, Pelletiere EV. Clinically-occult mixed cellularity Hodgkin's disease with Charcot-Leyden crystals. *Leuk Lymphoma* 1996; 23: 153-7.
  - 10 Fraga M, Forteza J. Diagnosis of Hodgkin's disease: an update on histopathological and immunophenotypical features. *Histol Histopathol* 2007; 22: 923-35.
  - 11 Al-Maghrabi JA, Sawan AS, Kanaan HD. Hodgkin's lymphoma with exuberant granulomatous reaction. *Saudi Med J* 2006; 27: 1905-7.
  - 12 Macaya A, Servitje O, Moreno A, Peyrí J. Cutaneous granulomas as the first manifestation of Hodgkin's disease. *Eur J Dermatol* 2003; 13: 299-301.
  - 13 Calafat J, Janssen H, Knol EF, et al. Ultrastructural localization of Charcot-Leyden crystal protein in human eosinophils and basophils. *Eur J Haematol* 1997; 58: 56-66.