

Three Living *Fasciola Hepatica* in the Biliary Tract of a Woman

Ramin Niknam¹, MD;
Mohammad Hassan Kazemi¹, MD;
Laleh Mahmoudi², Pharm.D, Ph.D

Abstract

Fasciola hepatica (*F. hepatica*) as a foodborne trematode can occasionally cause hepatobiliary diseases. We report a 67-year-old woman who was referred to our center because of the diagnosis of cholangitis. She was a resident of mountainous area with the history of unsafe water and contaminated vegetables. Endoscopic retrograde cholangiopancreatography (ERCP) was performed as a diagnostic and therapeutic modality for her. Three living *F. hepatica* was removed from biliary tract with a basket via ERCP. Clinical and laboratory condition of the patient improved after therapy of antibiotics and triclabendazole.

Please cite this article as: Niknam R, Kazemi MH, Mahmoudi L. Three Living *Fasciola Hepatica* in the Biliary Tract of a Woman. Iran J Med Sci. 2015;40(5):465-468.

Keywords • *Fasciola hepatica* • Fascioliasis • ERCP • Cholangitis • Biliary tract

Introduction

Fasciola hepatica (*F. hepatica*) is a foodborne trematode, which is occasionally observed in general practice.¹ *F. hepatica* was described as the first foodborne trematode that can occur worldwide in the areas where sheep and cattle are raised. Humans are its accidental hosts. After ingestion of contaminated water or aquatic plants containing metacercariae, juveniles penetrate the intestinal wall and migrate through the peritoneal cavity to the liver and then enter the bile ducts, and rarely to the gallbladder, where they mature and release eggs. Mature flukes size is 2-4 cm.¹⁻³

F. hepatica in acute phase can cause dyspepsia, fever, right upper quadrant pain, anorexia, urticaria, respiratory symptoms, jaundice, eosinophilia, and abnormal liver biochemical tests. In chronic phase, *F. hepatica* can cause biliary colic, intermittent jaundice, fatty food intolerance, cholangitis, and cholecystitis.^{1,4-6}

Diagnosis of the fascioliasis can be difficult. The diagnosis of *F. hepatica* is based on the combination of the clinical and radiologic findings, supported by serology.⁷

For *F. hepatica* infection treatment, a single dose of 10 mg/kg triclabendazole is recommended. Bithionol can be used in patients where triclabendazole is not available. Human's behavioral change can prevent the *F. hepatica* infection transmission.^{1,4,7}

Although the number of reports on humans infected with *F. hepatica* has increased significantly in recent decades; the removal of living *F. hepatica* from biliary tract is rare.^{8,9} Here we report a case of a 67-year-old woman who presented with acute cholangitis and three living *F. hepatica* removed with basket via Endoscopic Retrograde Cholangiopancreatography (ERCP).

¹Gastroenterohepatology Research Center, Shiraz University of Medical Sciences, Shiraz, Iran;

²Department of Clinical Pharmacy, School of Pharmacy, Shiraz University of Medical Sciences, Shiraz, Iran

Correspondence:

Laleh Mahmoudi, Pharm.D, Ph.D;
Department of Clinical Pharmacy,
School of Pharmacy, Kar-afarin Street,
P. O. Box 1583; 71345, Shiraz, Iran
Tel: +98 71 32424128 (ext. 292)
Fax: +98 71 32424126

E-mail: mahmoudi_l@sums.ac.ir

Received: 14 September 2013

Revised: 03 November 2013

Accepted: 24 November 2013

Case Report

A 67-year-old woman was presented to our center at Namazi Hospital (Shiraz University of Medical Sciences, Iran) with abdominal pain, icter, nausea, and anorexia beginning two weeks prior to evaluation. Symptoms became worst progressively. She lived in the Zagros mountain area (southern Iran) consuming unsafe water and contaminated vegetables. Her past medical history was unremarkable except for a controlled hypertension with captopril. On physical examination, she was ill and icteric with right upper quadrant tenderness.

According to the laboratory values upon admission, she had mild leukocytosis with prominent neutrophil without any evidence of eosinophilia. Liver biochemical tests were abnormal. Serum levels of amylase and lipase were normal. Her work up for virology markers (HAV, HBV and HCV) was negative. Table 1 shows the patient's initial laboratory results.

In abdominal ultrasonography, three small cysts and a dilated common bile duct were seen. Abdominal computed tomography scan showed three small cysts (<1 cm) and a dilated common bile duct, but liver parenchyma and intrahepatic bile ducts were normal (Figure 1).

ERCP was performed because of the diagnosis of cholangitis. In ERCP, dilatation of common bile duct with multiple filling defects was seen, but gallbladder and intrahepatic bile ducts were normal (Figure 2).

Our primary impression for filling defects was common bile duct stones or sludge.

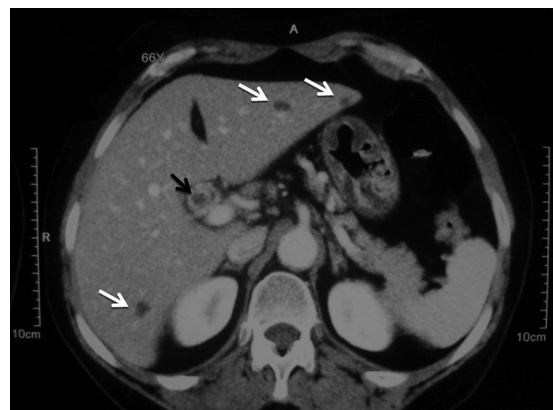

Figure 1: Abdominal computed tomography scan showed three small cysts (white arrows) and dilated common bile duct (black arrow).

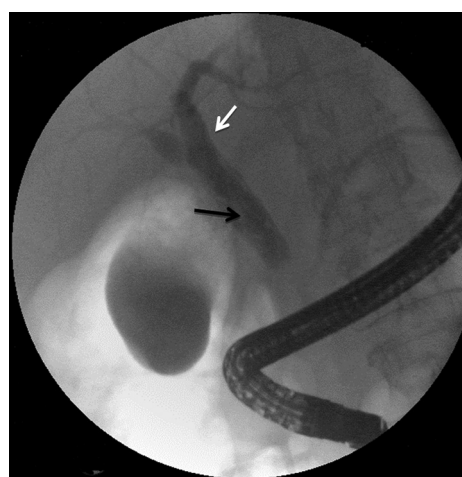


Figure 2: ERCP has showed dilatation of common bile duct (white arrow) with multiple linear filling defects (black arrow).

Table 1: Laboratory values on admission

| Laboratory data | Patient (normal range) |
|---|---------------------------|
| White blood cells (/mm ³) (%) | 10200 (4000-10000) |
| Neut | 74 (45-75) |
| Lymphocyte | 22 (20-45) |
| Monocyte | 2 (2-10) |
| Eosinophil | 1 (2-5) |
| Basophil | 1 (0-1) |
| Hemoglobin (g/dl) | 11.8 (12-16) |
| Platelets (mm ³) | 358,000 (140,000-400,000) |
| Direct bilirubin (mg/dl) | 2.4 (<0.2) |
| Total bilirubin (mg/dl) | 4.5 (0.1-1.2) |
| Aspartate aminotransferase (U/L) | 202 (<31) |
| Alanine aminotransferase (U/L) | 241 (<31) |
| Alkaline phosphatase (U/L) | 356 (64-306) |
| Amylase (IU/L) | 53 (<100) |
| Lipase (U/L) | 39 (<60) |
| Prothrombin time, patient (S) | 12.5 |
| Prothrombin time, control (S) | 12.5 |

Therefore, after sphincterotomy, we used a basket for removing the suspected stones, but surprisingly three living *F. hepatica* were removed by 3 times use of the basket. The *F. hepaticas* were alive and crawling in the basket.

The fluke's samples were sent for pathology evaluation and confirmed as *F. hepatica*. Stool examination for detection of *F. hepatica* eggs was negative. In addition to antibiotics for acute cholangitis (metronidazole 500 mg/IV/q6h and ceftazidim 200 mg/IV/q8h), triclabendazole (10 mg/kg single dose) was started for therapy. After the first week, oral ciprofloxacin was replaced for IV antibiotics and continued for another week.

Clinical and laboratory condition of the patient improved after 4 weeks; leukocytosis and liver biochemical tests were completely normalized (Table 2). The patient showed no clinical and laboratory problems in favor of the liver disease after 12 months follow up.

Table 2: Laboratory values after treatment

| | |
|---------------------------------------|--------------------|
| White blood cells (/mm ³) | 8400 (4000-10,000) |
| Total bilirubin (mg/dl) | 1.1 (0.1-1.2) |
| Direct bilirubin (mg/dl) | 0.2 (<0.2) |
| Aspartate aminotransferase (U/L) | 18 (<31) |
| Alanine aminotransferase (U/L) | 19 (<31) |
| Alkaline phosphatase (U/L) | 292 (64-306) |

Discussion

Although the number of reports on human infected with the flukes has increased significantly in the recent decades, only a few published reports exist about removal of living flukes (e.g. *F. hepatica*) from biliary tract.⁸⁻¹²

As far as we know, there is only one published report on the removal of living *F. hepatica* in Iran.⁸ In contrast to the patient presented by Aminian et al.,⁸ our case did not show eosinophilia and instead she had symptoms in favor of cholangitis. Although eosinophilia is the most laboratory abnormality during the hepatic phase of *F. hepatica* infection, this finding might be absent in some patients; especially during biliary phase.⁴ Similar to some others published articles,¹⁰⁻¹² our primary impression of filling defects in ERCP was common bile duct stones or sludge. However, after sphincterotomy for removing the suspected stones and sludge, surprisingly living flukes was removed that belonged to the genus *Fasciola*.

Some published articles have reported the cases of biliary fascioliasis in which the symptoms and management of patients were similar to our case.^{8,9}

There is only one report from Iran regarding *F. hepatica* since a food-borne trematode can occasionally cause hepatobiliary diseases in general practice. Humans, as accidental hosts, are contaminated after ingestion of unsafe water or raw aquatic plants.¹⁻³ *F. hepatica* can cause tract like microabscesses, usually in the subcapsular regions. Cystic like lesion may also be observed. On cholangiography, *F. hepatica* can cause biliary dilatation with single or multiple small filling defects.^{2,7}

Domestic herbivorous animals can be contaminated by liver flukes via the ingestion of grass and vegetables containing metacercariae.¹ In acute (hepatic) phase that begins one to three months after ingestion of metacercariae, fascioliasis can cause dyspepsia, fever, right upper quadrant pain, anorexia, hepatomegaly, splenomegaly, ascites, urticaria, respiratory symptoms, jaundice, subcapsular liver hematoma, hemobilia, eosinophilia, and abnormal liver biochemical tests. In chronic (biliary) phase, fascioliasis can cause biliary

colic, intermittent jaundice, epigastric pain, nausea, fatty food intolerance, cholangitis, and cholecystitis.^{1,4-6}

Diagnosis of fascioliasis can be difficult in non-endemic areas because the symptoms may be similar to other hepatic or biliary diseases. Although the presence of eggs in fecal samples is used for the diagnosis of *F. hepatica* infection, but this method is unreliable and complex. In the hepatic and biliary phase of fascioliasis, computerized tomographic scan and ultrasonographic findings are used to assist the diagnosis. Confirmation of the diagnosis by serology and parasitic test is necessary.⁴ Although in the chronic stage, detection of the eggs in the stool can be used for the diagnosis, in acute phase, stool examination cannot be used for the diagnosis because of the natural history of *F. hepatica* infection. Therefore, the diagnosis of chronic phase is based on the combination of clinical and radiologic findings supported by serology.⁷

A single dose of 10 mg/kg triclabendazole is recommended for *F. hepatica* infection treatment. The dose can be repeated after 12-24 h for major infections. In case of treatment failure, a double dose is recommended.

Triclabendazole is registered in a few countries, therefore bithionol can be used when triclabendazole is not available.^{1,4,7} Calcification of liver lesions may remain after therapy. Disappearance of the symptoms and eosinophilia can predict a favorable outcome.⁷ The final aim is prevention of infection via alteration of human behavior.¹

Conclusion

Biliary fascioliasis may present with different symptoms. The reported case was presented with acute cholangitis. Before ERCP, *F. hepatica* infection was not considered. ERCP was performed as a diagnostic and therapeutic modality for cholangitis. Living *F. hepatica* was removed by basket and confirmed by pathology evaluation. It is recommended that *F. hepatica* infection should be considered as a possible, but not a common cause of acute cholangitis, especially in the endemic areas.

Acknowledgment

This study was a joint effort by R. Niknam (physician in charge) and L. Mahmoudi (monitoring the therapy) in the form of gathering data and writing the article. ERCP was carried out by M.H. Kazemi.

Conflicts of Interest: None declared.

References

1. Keiser J, Utzinger J. Food-borne trematodiasis. *Clin Microbiol Rev.* 2009;22:466-83. doi: 10.1128/cmr.00012-09. PubMed PMID: 19597009; PubMed Central PMCID: PMC2708390.
2. Lim JH, Kim SY, Park CM. Parasitic diseases of the biliary tract. *AJR Am J Roentgenol.* 2007;188:1596-603. doi: 10.2214/ajr.06.1172. PubMed PMID: 17515382.
3. Mas-Coma MS, Esteban JG, Bargues MD. Epidemiology of human fascioliasis: a review and proposed new classification. *Bull World Health Organ.* 1999;77:340-6. PubMed PMID: 10327713; PubMed Central PMCID: PMC2557647.
4. Kaya M, Bestas R, Cetin S. Clinical presentation and management of Fasciola hepatica infection: single-center experience. *World J Gastroenterol.* 2011;17:4899-904. doi: 10.3748/wjg.v17.i44.4899. PubMed PMID: 22171131; PubMed Central PMCID: PMC235633.
5. Leon M, Alave J, Alvarado R, Gotuzzo E, Terashima A, Seas C. A 52-year-old woman with a subcapsular liver hematoma. *Clin Infect Dis.* 2011;52:1137, 95-6. doi: 10.1093/cid/cir086. PubMed PMID: 21467019.
6. Bahcecioglu IH, Ataseven H, Aygen E, Coskun S, Kuzu N, Ilhan F. Fasciola hepatica case with hemobilia. *Acta Medica (Hradec Kralove).* 2007;50:155-6. PubMed PMID: 18035756.
7. Marcos LA, Tagle M, Terashima A, Bussalleu A, Ramirez C, Carrasco C, et al. Natural history, clinico-radiologic correlates, and response to triclabendazole in acute massive fascioliasis. *Am J Trop Med Hyg.* 2008;78:222-7. PubMed PMID: 18256419.
8. Aminian K, Rezayat KA, Shafaghi A, Tanhaeevash R. Living Fasciola hepatica in biliary tree: a case report. *Ann Hepatol.* 2012;11:395-8. PubMed PMID: 22481460.
9. Ozer B, Serin E, Gumurdulu Y, Gur G, Yilmaz U, Boyacioglu S. Endoscopic extraction of living fasciola hepatica: case report and literature review. *Turk J Gastroenterol.* 2003;14:74-7. PubMed PMID: 14593544.
10. Goral V, Senturk S, Mete O, Cicek M, Ebik B, Kaya B. Biliary Fasciola gigantica case report from Turkey. *Southeast Asian J Trop Med Public Health.* 2011;42:509-12. PubMed PMID: 21706928.
11. Tuna Y. Endoscopic management of biliary fasciolosis. *Cumhuriyet Med J.* 2011;33:469-72.
12. Kanoksil W, Wattanatranoon D, Wilasrusmee C, Mingphruedh S, Bunyaratvej S. Endoscopic removal of one live biliary Fasciola gigantica. *J Med Assoc Thai.* 2006;89:2150-4. PubMed PMID: 17214071.