

Pulmonary Actinomycosis Mimicking Lung Cancer

V. Montazeri, M. Sokouti, A. Fakhru¹

Abstract

Herein, we reported on a case of solid type of pulmonary actinomycosis in a 10-year-old boy. He had productive cough for 40 days. Bronchoscopy was normal. Computed tomography revealed a solid large mass in the upper lobe of his left lung with mimicking malignant lesions. He was referred for surgery and underwent left upper lobectomy. Macroscopically, the specimen measured 13×9×5 cm and was creamy to whitish on cut section. Microscopic findings included a large number of inflammatory cells and colonies of actinomycetes. Pulmonary actinomycosis should be included in the differential diagnoses of pulmonary mass lesions, especially in the young adults.

Iran J Med Sci 2007; 32(4): 248-250.

Keywords • Actinomycosis • lung • solid tumors • carcinoma

Introduction

Pulmonary actinomycosis is a rare, chronic, endogenous infection caused by an anaerobic or microaerophilic Gram positive *Actinomyces* (*Actinomyces Israelii*) occurring primarily in debilitated patients with poor oral hygiene. Before the penicillin era, thoracic actinomycosis looked like tuberculosis or neoplasia with chest wall invasion and fistula formation.^{1,2} The disease has a worldwide distribution without age or race preference. Men are affected slightly more than women. There is no occupational predilection or seasonal variation.³ Sometimes, it reported in immunocompromised patients. The standard treatment of this disease is administration of high dose penicillin G,² but surgery may be indicated to diagnose or to differentiate it from lung carcinoma.⁴ Herein, we reported on a solid pulmonary actinomycosis in a 10-year-old boy mimicking carcinoma of the lung on chest roentgenogram and intra-operatively.

Case Report

A 10-year-old boy was admitted to Imam Khomeini Hospital affiliated to Tabriz University of Medical Sciences, Tabriz, Iran, in June 2004 with history of 40 days productive cough. He had a history of dental extraction one year before. He had received oral and intravenous antibiotics for 40 days without any improvements. On admission, the patient had malaise and weight loss. He was not febrile. He had mild respiratory distress and dyspnea. There were dullness, decreased respiratory sounds and wheeze on his left upper lung fields. Laboratory findings were normal. Bacteriologic examination of the sputum was normal. His chest roentgenogram revealed a large opacity in the left upper lobe (figure 1). Computed tomography revealed an opacity in the left upper lobe

Department of Thoracic Surgery,
¹Pathology, Imam Khomeini Hospital,
Tabriz University of Medical Science,
Tabriz, Iran.

Correspondence:

Vahid Montazeri MD,
Department of Thoracic Surgery,
Imam Khomeini Hospital,
Tabriz University of Medical Science,
Tabriz, Iran.
Tel: +98 411 3363232
Fax: +98 411 335990
Email: Sokouti_m@yahoo.com

suggestive for malignancy (figure 2). Bronchoscopy showed only erythema and inflammation of the left upper lobe bronchus. Bronchial biopsy specimen revealed nonspecific inflammatory changes. Transbronchial lung biopsy and cytology was negative for malignancy. Pathologic examination of the percutaneous fine needle aspiration of the mass also showed non-specific inflammatory process.

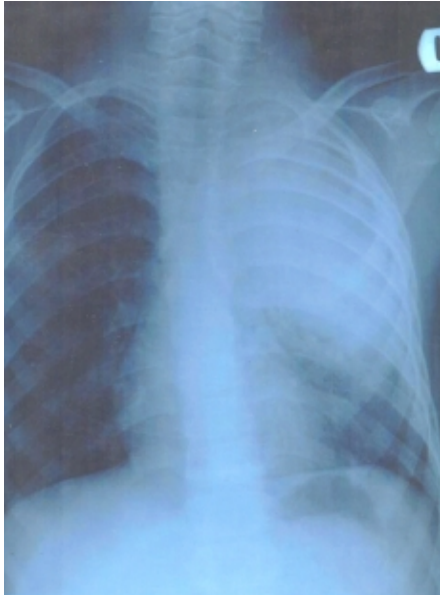

Figure 1: Chest radiography shows a large mass opacity in the left upper part of the lung.

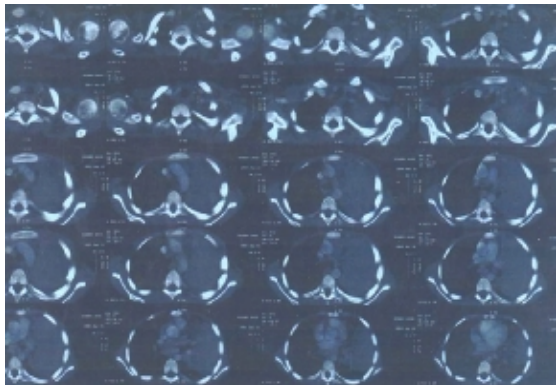


Figure 2: Computed tomography of the chest shows opacity in the left upper lobe suggestive for malignancy.

Because of suspicion for malignancy, the patient was referred to our ward for surgery. The diagnosis was not made after thoracic surgery because the mass had tumoral appearance with severe adhesions to the left upper part of the chest wall. The left upper lobe lobectomy with mediastinal lymph node dissection was done. Pathologic examinations revealed a solid pulmonary actinomycosis with lymphoid hyperplasia (figure 3). The patient tolerated well the operation and was subsequently treated with penicillin G for two months and did well during a one-year follow-up.

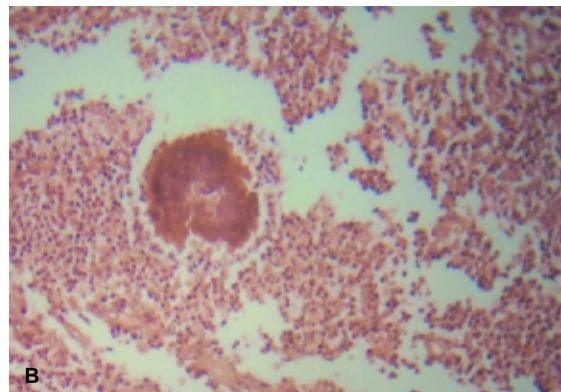
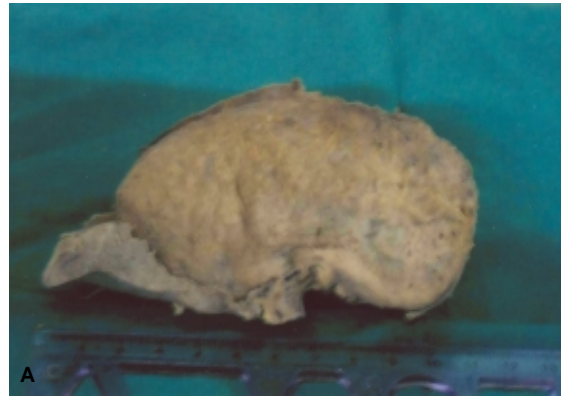

Figure 3: Macroscopy, A: Actinomycosis, the cut surface of the lung shows one well-defined solid mass with multiple yellowish foci. B: Actinomycosis, granules of actinomycetes in air space of lung tissue, $\times 100$.

Discussion

Pulmonary actinomycosis is a rare but important and challenging diagnosis. It is more frequently seen in immunocompromised patients aged 30–60 years.⁵ In human, actinomycosis involves the thorax in 15% of cases. Thoracic and pulmonary parenchymal involvement is usually secondary to aspiration of colonized material from oropharynx in patients with poor oral hygiene. Chest wall and bone invasion are common. Periosteal reaction of ribs is said to be highly suggestive of pulmonary actinomycosis.⁶ Clinical features include a slowly progressive lesion and the most common symptom is hemoptysis. Laboratory finding may disclose elevated erythrocyte sedimentation rate, a sign of chronic inflammation.

On chest computed tomography, the lesion may appear as nodular or consolidated shadows with atelectasis. Local pleural thickening adjacent to the nodules are also reported.⁷ Even when the clinical suspicion is high, the disease is commonly confused with other chronic suppurative lung diseases and with malignancy. An early accurate diagnosis will prevent unwarranted surgery. Respiratory physicians should be aware of this important differential diagnosis which will expedite the

diagnosis of this well treatable condition with an excellent prognosis, if picked up early.⁸ It deserves attention because of the potential difficulty in differential diagnosis of it from lung cancer.^{9,10} Mass-like shadow is the most common radiographic finding (37%) and endobronchial mass with luminal occlusion is the most frequent bronchoscopic finding (56%).¹¹ Most cases of pulmonary actinomycosis have been diagnosed from post-surgical tumor specimens taken on suspicion of the presence of lung cancer.⁴ It is difficult to diagnose pulmonary actinomycosis by transbronchial lung biopsy, but granulation tissue obtained by this method is considered an important clue suggestive for the disease.⁷ Sometimes, diagnosis and treatment of pulmonary actinomycosis is difficult without surgical intervention.¹²

Acknowledgement

We thank Dr. Moslem Bahadori for his help in reviewing of pathologic examinations.

References

- 1 Lacassagne L, Miguéres M, Fajadet P, et al. Actinomycosis presenting as a chronic excavated pneumonia in a young woman. *Rev Medical Respire* 2004; 21: 591-4.
- 2 Haloui I, El Biaze M, Yassine N, et al. Pulmonary Actinomycosis: Two cases. *Rev Pneumol Clin* 2004; 60: 357-61.
- 3 Fraser RS, Pare PD. Diagnosis of disease of the chest. 4th ed. Philadelphia, Saunders, 1999, 953.
- 4 Nagaoka T, Setoguchi Y, Muramatsa M, et al. A case of pulmonary squamous cell carcinoma coexisting with pulmonary Actinomycosis. *Nihon Kokyuki Gakkai Zasshi* 2002; 40: 525-9.
- 5 De La Espina MA, Lopez- Menendez C, Ruiz- Martinez R, et al. Pulmonary Actinomycosis with thoracic soft tissue mass: A rare onset form. *Eur J Radiol* 2001; 37: 195-9.
- 6 Poey C, Giron J, Verhaegen F, et al. X-ray computed tomographic and radiographic aspects of thoracic Actinomycosis. *J Radiol* 1996; 77: 177-83.
- 7 Hagiwara S, Ishii Y, Kitamura S. Clinical and radiological study of pulmonary actinomycosis. *Nihon Kokyuki Gakkai Zasshi* 1998; 36: 999-1005.
- 8 Mabeza GF, Macfarlane J. Pulmonary Actinomycosis. *Eur Respir J* 2003; 21:545-51.
- 9 Izumi Y, Moroe Y, Onaka A, et al. Pulmonary Actinomycosis presenting as a mass lesion on chest X-Ray film. *Nihon Kokyuki Gakkai Zasshi* 2000; 38: 186-9.
- 10 Kurisu S, Yokote K, Taira Y, et al. A case of pulmonary actinomycosis radiologically mimicking a lung cancer. *Kyobu Geka* 2000; 53: 511-3.
- 11 Dujneungkunakorn T, Riantawan P, Tung-sangunwattana S. Pulmonary Actinomycosis: a study of 16 cases from central chest hospital. *J Med Assoc Thai* 1999; 82: 531-5.
- 12 Endo S, Murayama F, Yamaguchi T, et al. Surgical consideration for pulmonary Actinomycosis. *Ann Thorac Surg* 2002; 74: 185-90.