

Appendicitis Caused by Metallic Foreign Body in the Appendix

Seyed Abbas Banani

Abstract

Although uncommon, different kinds of foreign bodies, most of which metallic, have been reported to enter the appendix. The present report describes a case with a metallic foreign body-induced appendicitis, and makes suggestion in regards to the diagnosis and management of the problem. A metallic foreign body was accidentally observed in the right lower quadrant region in an abdominal X-ray taken after blunt trauma in a 6-year-old boy. After 4 months of persistent presence of foreign body not related to trauma, the patient was apparently asymptomatic, and there was a mild to moderate Mc-Burney tenderness. Exploration revealed the presence of an air-rifle buckshot in the proximal part of the appendix causing appendicitis due to luminal obstruction. Histopathologic study of the appendix revealed inflammation and serositis.

Iran J Med Sci 2010; 35(4): 335-338.

Keywords • Appendicitis • foreign body • abdominal X-ray

Introduction

Appendicitis is the most common cause of acute abdomen affecting almost all ages. The underlying etiology of this surgical entity varies. In the majority of cases, it is either secondary to hyperplasia of the appendiceal lymphoid follicles, which usually occurs in children following a bacterial or viral infection, or fecal materials or fecalith, which occurs usually in adults and less commonly in children.^{1,2} However, as a rare cause of appendicitis, a variety of foreign bodies have been found in the appendix in the last 270 years.¹⁻⁵ In 1735, the first foreign body-induced appendicitis was reported.⁶ In 19th century, foreign bodies were mostly due to hand-sewing needles or buckshots in the meat from hunted wild games.³⁻⁵ Thereafter, different kinds of "high risk" or "low risk" foreign bodies in the appendix have been reported.¹⁻⁹ Although management in most cases is appendectomy, there is no universal agreement on this issue, particularly if the patient is asymptomatic. Herein, we present a case of appendicitis caused by the presence of a buckshot in the appendix, and present a practical guideline as to how to diagnose and manage the presence of foreign bodies in the appendix.

Case Presentation

A 6-year-old boy was referred to the clinic because of the persistent presence of a metallic foreign body located at the right side of the abdomen for the preceding 4 months (figure 1). The object, bullet of an air-rifle, had been accidentally noticed using a plain abdominal X-ray taken one hour after a car accident 4 months earlier. No sign of entrance for the bullet

Department of Pediatric Surgery,
Trauma Research Center,
Shiraz University of Medical Sciences,
Shiraz, Iran.

Correspondence:

Seyed Abbas Banani MD,
Department of Pediatric Surgery,
Trauma Research Center,
Shiraz University of Medical Sciences,
Shiraz, Iran.

Tel: +98 711 6125261

Fax: +98 711 6125161

Email: bananiabbas@yahoo.com

Received: 8 October 2009

Revised: 7 December 2009

Accepted: 21 January 2010

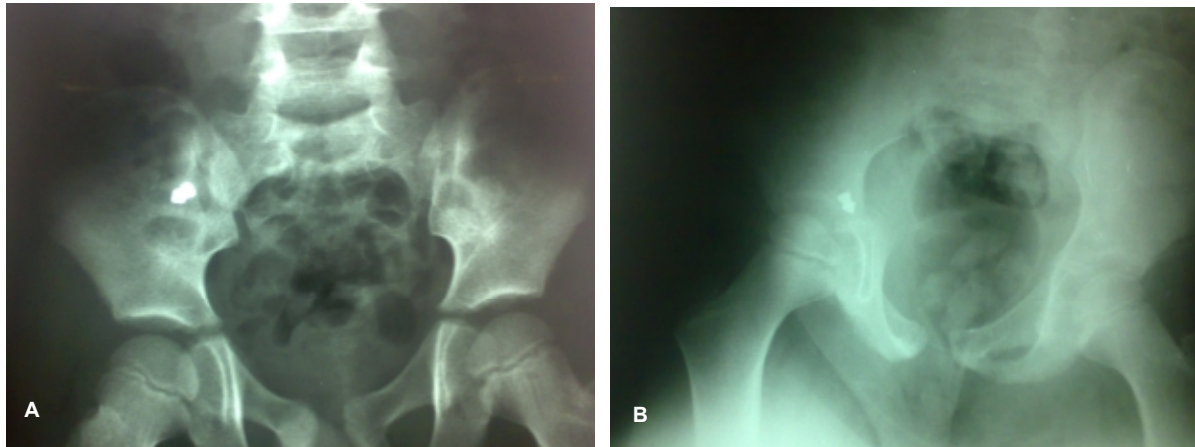


Figure 1: (A) Radiopaque foreign body with a round and blunt border (Buckshot) at the right lower quadrant area; (B) persistent presence of the foreign body in the same area 4 months later.

had been observed at any parts of the body including abdomen and pelvis. Moreover, there was no history of foreign body ingestion or hunted meat consumption.

The patient had been almost asymptomatic during the preceding 4 months except for occasional vague periumbilical discomfort once to twice a week, which was unrelated to meal, bowel movement or activity. Although the patient had not been constipated other physicians, assuming foreign body in small bowel, had given him laxative several times. However, the location of foreign body had been persistent as revealed in all plain abdominal X-rays taken during several weeks before referral.

Physical examination revealed a healthy boy whose general condition was all right. The only abnormal finding was the direct tenderness at the Mc-Burney point without rebound phenomenon. Blood cells counts and urinalysis were normal. Abdominal sonography showed a hyperechoic lesion with shadowing similar to fecalith at the right lower quadrant area.

With the impression of mildly inflamed or subacute appendicitis secondary to the obstruction of its lumen by the metallic foreign body, he underwent operation through a small Rockey-Davis incision. Exploration of the abdomen revealed moderately inflamed appendicitis with dilated (10-11mm in diameter) proximal lumen. The foreign body was located at proximal third of the appendix. Appendectomy was performed, after which the foreign body was removed, and was shown to his parents. Histopathologic examination of the appendix showed mild inflammation and serositis with fecal material.

Discussion

Although rare, a variety of objects, including

vegetable seeds, fruit seeds and pits, and worms have been reported to lodge in the appendiceal lumen.^{1,4} However, more than 75% of the reported foreign bodies in the appendix have been radiopaque. The most common foreign bodies have been needles, pins, screws and buckshots.^{3,5} The reason for this phenomenon may be that radiopaque objects are usually heavier than gastro-intestinal (GI) contents. Considering the dependent position of the cecum and to some extent its low motility, such foreign bodies tend to gravitate and stay there. In addition, the chance of entry to appendiceal lumen is determined not only by its orifice, which might be tight or widely open, but also by the anatomic position of the appendix. There is almost no possibility for a foreign body to enter the lumen of retrocecal appendices.³ This might be related to the upward position of the appendix, which is probably accompanied by partial kinking or narrowing of its orifice.

Once the pylorus is passed, majority of ingested foreign bodies, particularly blunt ones, would pass the GI tract in a matter of few days without an incident. However, sometimes sharp objects may not only pass the mucosa, but also penetrate the bowel wall. Foreign bodies may lodge in abnormal locations such as duplication cyst of the esophagus,¹⁰ diverticulum of duodenum,¹¹ or jejunum,¹² Meckel's diverticulum,^{13,14} or even sigmoid colon pseudo-diverticulum.¹⁵ Some of them, especially if sharp or end-pointed, may get complicated. Similarly, those trapped in the appendix, depending on their size, shape or nature, usually cause complicated or uncomplicated appendicitis. Klingler et al. reviewed 256 reported patients with foreign bodies in the appendix, which occurred over in 100 years (1898-1997).³ Sharp, pointed and stiff or metallic

foreign bodies usually cause more problems. According to these authors, in patients with sharp, pointed and stiff or metallic foreign bodies, 93% were symptomatic, 88% of the excised appendices showed inflammation, and 70% had perforations.³ On the other hand, blunt or round firm foreign bodies with smooth border caused symptoms in 66% of cases.³ Therefore, depending on the physical criteria of the objects, foreign bodies in the appendix can be divided into high-risk and low-risk ones. The high-risk foreign bodies include sharp, long or pointed objects, and low-risk ones include objects with blunt or round orders. Having reviewed 100 year experience, Klingler et al. found out that about 75% of the reported patients had high-risk foreign bodies, while less than 12% of the cases had low-risk foreign bodies.³

As the majority of foreign bodies in the appendix are radiopaque, the persistence of a metallic object observed either in serial plain abdominal X-rays or as hyperechoic lesion with shadowing in sonography in the right lower quadrant region, which was observed in the present case, should raise the suspicion, and guide the physician to the diagnosis of the presence of a foreign body in the appendix. In such a situation, owing to the presence of inflammation along with at least partial obstruction in many individuals, Mc-Burney tenderness in an apparently asymptomatic patient is highly suggestive of the diagnosis. Thus, no other work up would be necessary. Considering the presence of symptoms in the majority of patients with high-risk foreign bodies in the appendix and high rate of associated complications, prophylactic appendectomy should be the treatment of choice. Furthermore, it has been shown that even blunt or low-risk objects, which are usually surrounded by concretions of the fecal material, would lead to the obstruction of appendiceal lumen in long-term, and cause sub-acute or chronic appendicitis or occasionally mucocele.^{2,3} In addition, buckshot foreign bodies, which are not uncommon, may cause lead poisoning.¹⁶ Therefore, all individuals with foreign bodies in the appendix, regardless of the kind and nature of the foreign bodies and whether or not they are symptomatic, should be appendectomized. Although the presence of buckshot bullets in the appendix are usually detected accidentally and patients may remain asymptomatic, like the present case, the majority of cases have been managed by elective appendectomy.^{3,4}

Before the final decision for appendectomy, some authors have advised colonoscopy for possible foreign body removal, not only if it is

resided in the terminal ileum or cecum, but also even if it is embedded in the appendix.¹⁷ If colonoscopy fails, the next step ought to be laparoscopy under the guide of fluoroscopy, which allows the identification of foreign body in the appendix as well as other unusual locations such as diverticulum.⁴ It has also been recommended to do laparoscopic cecotomy or ileotomy in the cases of foreign body presence in such locations.⁴ Alternatively, owing to the potential chance of leakage by the latter two approaches, foreign bodies in the cecum, ileum, or even jejunum, can be removed via the appendiceal stump following open appendectomy. However, when the object is located in the small bowel, it must be milked and guided safely into the cecum and then removed. Complicated cases of appendicitis with foreign bodies, such as those associated with mucocele or perforation with or without abscess formation, should be managed similar to complicated ones without foreign bodies.

Conclusion

Although foreign body in the appendix is rare, majority are radiopaque objects with high-risk criteria, and can be detected by plain abdominal radiograph. Persistence of a metallic object in the lower parts of the abdomen at the right side, particularly along with the presence of direct tenderness at the Mc-Burney point, are adequate evidences to consider exploration. Regardless of the kind or nature of the foreign body in the appendix and whether or not it is symptomatic, owing to the development of symptoms or a variety of complications in majority of these individuals, prophylactic appendectomy, laparoscopic or open, should be the procedure of choice.

Conflict of Interest: None declared

References

- 1 Dunn JCY. Appendicitis. In Grosfeld JL, O'Neill JA (eds), *Pediatric Surgery* (6th ed.), Mosby, Inc. 2006, chap. 98.
- 2 Maa J, Kirkwood KS. The Appendix. In Townsend CM Jr., Beauchamp RD (eds), *Sabiston Textbook of Surgery* (18th ed). Saunders; 2008, chap. 49.
- 3 Klingler PJ, Seelig MH, DeVault KR, et al. Ingested foreign bodies within the appendix: A 100-year review of the literature. *Dig Dis* 1998; 16: 308-14.
- 4 Klingler PJ, Smith SL, Abendstein BJ, et al. Management of ingested foreign bodies

- within the appendix: a case report with review of the literature. *Am J Gastroenterol* 1997; 92: 2295-8.
- 5 Zampieri N, Zuin V, Ottolenghi A, Camoglio FS. Recurrent abdominal pain due to buckshots in the appendix. *Acta Paediatr*. 2008; 97: 983-4.
 - 6 Creese PG. The first appendectomy. *Surg Gynecol Obstet* 1953; 97: 643-52.
 - 7 Hartin CW Jr, Lau ST, Caty MG. Metallic foreign body in the appendix of 3-year old boy. *J Pediatr Surg* 2008; 43: 2106-8.
 - 8 Wightman JR. Foreign body induced appendicitis. *S D J Med* 2004; 57: 137.
 - 9 Larsen AR, Blanton RH. Appendicitis due to bird shot ingestion: a case study. *Am Surg* 2000; 66: 589-91.
 - 10 Stringel G, Mercer S, Briggs V. Esophageal duplication cyst containing a foreign body. *Can Med Assoc J* 1985; 132: 529-31.
 - 11 Zhetimkarimov DS, Zhetimkarimova AD, Rakhmetov AO. A foreign body in a duodenal diverticulum. *Klin Khir* 1991; (10): 70.
 - 12 Shaw JH. Perforated jejunal diverticulum due to foreign body. *N Z Med J* 1980; 91: 384-5.
 - 13 Pua U. Impacted fishbone in Meckel diverticulum. *Med J Aust* 2008; 189: 417.
 - 14 Sekmen U, Gungor O, Sagiroglu J: Perforation of Meckel's diverticulum by a fishbone. *ANZ J Surg* 2008; 78: 1045-6.
 - 15 Chung YS, Chung YW, Moon SY, et al. Toothpick impaction with sigmoid colon pseudodiverticulum formation successfully treated with colonoscopy. *World J Gastroenterol* 2008; 14: 948-50.
 - 16 Durlach V, Lisovoski F, Gross A, et al. Appendectomy in an unusual case of lead poisoning. *Lancet* 1986; 1: 687-8.
 - 17 Meltzer SJ, Goldberg MD, Meltzer RM, Claps F. Appendiceal obstruction by a toothpick removed at colonoscopy. *Am J Gastroenterol* 1986; 81: 1107-8.