

# Hypoglossal Schwannoma in Submandibular Space

B. Khademi, B. Gandomi,  
M. Javad Ashraf<sup>1</sup>, F. Yeganeh

## Abstract

Schwannoma of the hypoglossal nerve is an uncommon benign neoplasm. We present a 49-year-old female patient with hypoglossal schwannoma presenting as a painless mass in the submandibular area.

**Iran J Med Sci 2007; 32(1): 54-56.**

**Keywords** • Schwannoma • hypoglossal nerve • submandibular

## Introduction

**S**chwannomas are benign and slow-growing neoplasms of neural sheath origin. They usually arise from the sensory divisions of the major cranial nerves in the head and neck areas. It rarely involves motor or multiple nerves.<sup>1-3</sup> The management of schwannomas includes careful surgical dissection with extracapsular peeling or enucleation of the tumor from the affected nerve to preserve the function of the nerve. Postoperative neurological deficits are occasionally found. A review of seven cases indicated that surgical operation of the tumor was associated with permanent deficits (29%), transient deficits (43%), and no deficit (29%).<sup>4</sup> The present case report describes a case of hypoglossal schwannoma presenting as a mass in the submandibular area.

## Case Description

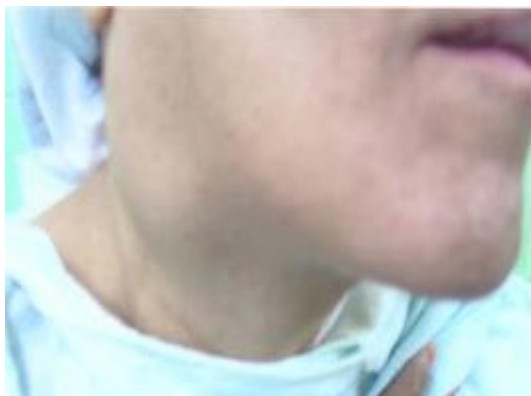The patient was a 47-year-old woman referring to the ENT clinic, Shiraz University of Medical Sciences, Shiraz, Iran. She complained of a mass on the right side of the neck, which had been noted for more than six months earlier. In physical examination, she complained of numbness and paresthesia on the right side of the tongue. A mobile, non-tender and painless mass (5×5×4 cm) was realized in the right submandibular area (figure 1). The right hypoglossal nerve was paralyzed, and the tongue was deviated to the right side. No other abnormal finding was found in the examination of the head and neck. Cytological examination of a sample of fine needle biopsy was reported as "insufficient for diagnosis". However, computed tomography (CT) revealed a well encapsulated mass in the right submandibular area (figure 2).

The mass was excised transcervically through a right transverse cervical incision. After elevating subplatysmal flap, digastric muscle and hypoglossal nerve were exposed. Adhered to the hypoglossal nerve in submandibular area was a large encapsulated mass, which extended to the parapharynx. The mass was carefully shaved off the surrounding structures and the hypoglossal nerve. Histological examination of the mass confirmed that it was schwannoma (figure 3).

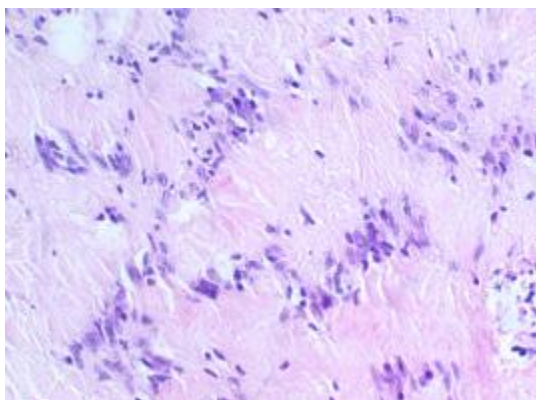
Departments of Otolaryngology and  
<sup>1</sup>Pathology, Medical School,  
Shiraz University of Medical Sciences,  
Shiraz, Iran.

## Correspondence:

Bijan Khademi MD,  
Department of Otolaryngology,  
Khalili Hospital,  
Khalili Street,  
Shiraz, Iran.  
**Tel/Fax:** +98 711 7269372  
**Email:** [Khademib@yahoo.com](mailto:Khademib@yahoo.com)



**Figure 1:** The patient with a painless mass in the right side of the neck



**Figure 3:** Histological photograph showing schwannoma with typical Antoni A and Antoni B type tissue (H&E X400).

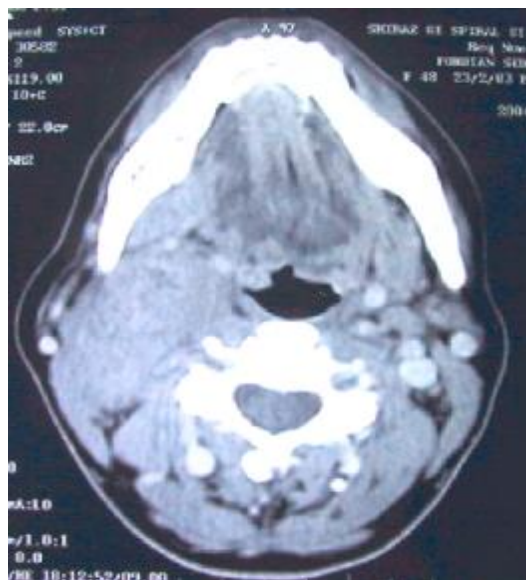
The tumor showed no sign of recurrence during two years follow up after surgery. However, the neurological deficit such as the paralysis of the right side of the tongue remained unchanged with no sign of recovery.

## Discussion

Schwannomas are benign tumors of Schwann cells.<sup>5,6</sup> They are solitary and well encapsulated tumors characteristically running along the course of or attached to peripheral, cranial or sympathetic nerves.<sup>6</sup> The reported sites of origin of schwannomas are the cranial nerves IX-XII, the sympathetic chain, the cervical plexus, and the brachial plexus.<sup>7-9</sup> The key element in the management of Schwannomas is precise preoperative diagnosis.<sup>10</sup>

Schwannomas are often present as a mass of variable sizes in the neck area. On palpation, they are movable in all directions except along the long axis of the nerve.

Schwannomas of the head and neck may be located in several sites, including the parapharyngeal space, maxillary sinus, submandibular space, and intracranial area.<sup>11</sup> Most tumors originate from the intracranial



**Figure 2:** Contrast enhanced CT scan shows a large well defined, heterogenous soft tissue mass at the right submandibular area.

portion of the cranial nerves with or without combined extracranial extension.<sup>6</sup> Solitary extracranial neurogenous neoplasms are uncommon, especially those developing from the hypoglossal nerve.<sup>12</sup> Schwannomas of the hypoglossal nerve affect women more commonly than men, and often occur in the fourth or fifth decades of life.<sup>1</sup> They are often presented as solitary and painless neck masses of variable sizes.<sup>13</sup>

The diagnosis relies on clinical suspicion. Aspiration biopsy has been recommended as an initial test,<sup>6</sup> but has not gained widespread acceptance.<sup>7</sup> Contrast enhanced tomography and magnetic resonance imaging (MRI) are helpful in preoperative diagnosis. The CT is sensitive to the cystic changes that frequently accompany the tumor. MRI is capable of reliably imaging, not only the tumor and its capsule, but also the nerve from which the tumor arises.<sup>8,9</sup> Three differential diagnoses for tumors in the submandibular space include infectious disease, benign pleomorphic adenoma, and nodal metastases.<sup>1</sup>

Treatment of Schwannomas is surgical excision. One approach is to open the capsule and shell out the tumor, and to leave the capsular nerve fibers undisturbed to possibly avoid functional deficits of the nerve.<sup>10</sup> Excision of the lesion with the preservation of the nerve, via an external approach, is the treatment of choice. Transcervical approach and intracapsular removal of the tumor require a minimally invasive surgery.<sup>14</sup> When a nerve segment must be sacrificed for complete tumor

removal, immediate reconstruction with nerve grafting should be performed to restore the neural function. In this case although the hypoglossal nerve was preserved, the nerve function did not improve during a 2-year follow-up period.

Schwannoma of the hypoglossal nerve usually originates from intracranial portion of the nerve. Extracranial schwannomas of hypoglossal nerve are extremely rare.<sup>3</sup> It should be considered in the differential diagnosis of submandibular masses.

## References

- 1 Karpati RL, Loevner LA, Cuning DM, et al. Synchronous Schwannomas of the hypoglossal nerve and cervical sympathetic chain. *AJR Roentgenol* 1998; 171: 1505-7.
- 2 Sutay S, Tekinsoy B, Ceryan K, Aksu Y. Submaxillary hypoglossal neurilemmoma. *J Laryngol Otol* 1993; 107: 953-4.
- 3 De Foer B, Hermans R, Sciot R, et al. Hypoglossal schwannoma. *Ann Otol Rhinol Laryngol* 1995; 104: 490-2.
- 4 Ku HC, Yeh CW. Cervical schwannoma: A case report and eight years review. *J Laryngol Otol* 2000; 114: 414-7.
- 5 Valentino J, Boggess MA, Ellis JL, et al. Expected neurologic outcomes for surgical treatment of cervical neurilemmomas. *Laryngoscope* 1998; 108: 1009-13.
- 6 Dornner TR, Voorhies RM, Kline DG. Neural sheath tumors of major nerves. *J Neurosurg* 1994; 81: 362-73.
- 7 Ehrlich HE, Martin H. Schwannomas (neurilemmomas) in the head and neck. *Surg Gynecol Obstet* 1943; 76: 577-83.
- 8 Cerofolini E, Landi A, DeSantis G, et al. MR of benign peripheral nerve sheath tumors. *J Comput Assist Tomogr* 1991; 15: 593-7.
- 9 Friedman DP. Segmental neurofibromatosis (NF-5): a rare form of neurofibromatosis. *AJNR Am J Neuroradiol* 1991; 12: 971-2.
- 10 Sheridan MF, Yim DWS. Cervical sympathetic schwannomas: A case report and review of the English literature. *Otolaryngol Head Neck Surg* 1997; 117: 206-10.
- 11 Chang KC, Leu YS. Hypoglossal schwannoma in the submandibular space. *J Laryngol Otol* 2002; 116: 63-4.
- 12 Storper IS, Glasscock ME, Jackson CG, et al. Management of nonacoustic cranial nerve neuromata. *Am J Otol* 1998; 19: 484-90.
- 13 al-Ghamdi S, Black MJ, Lafond G. Extracranial head and neck schwannomas. *J Otolaryngol* 1992; 21: 186-8.
- 14 Sato K, Shimizu S, Oka H, et al. Usefulness of transcervical approach for surgical treatment of hypoglossal schwannoma. *Surg Neurol* 2006; 65:397-401.