

# Actinomycetoma in a 60-Year-Old Woman for 20 Years

A. Zarei Mahmoudabadi, R. Yaghoobi<sup>1</sup>

## Abstract

Mycetoma is a chronic and pustular infection usually involves foot. Mycetoma in Iran is not common and most cases have been reported from the South and North of Iran. The objective of present study was to review the mycetoma and the distribution of its etiologic agents in Iran. Moreover, a 60-year-old woman with actinomycetoma lesions in her left foot was presented. Direct smear of the grains showed positive, non-acid fast and branching filaments of actinomycetes. Negative result was obtained from the cultures of grains.

**Iran J Med Sci 2007; 32(4): 245-247.**

**Keywords** • Mycetoma • actinomycete infection • granule

## Introduction

**M**ycetoma is a chronic, localized granulomatous and suppurative lesion of the subcutaneous tissue, skin and bones. Occasionally, visceral involvement can occur.<sup>1-3</sup> The disease symptoms include painless swelling, tumefaction of the affected area with development of multiple sinuses from which pus containing grains is discharged. The disease progress is slow; at its late stages, it produces deformation of the affected organ and becomes painful by secondary bacterial infection. Approximately 70% of patients with mycetoma have their feet involved; other sites are less involved.<sup>4-6</sup>

Disease is usually acquired by traumatic implantation of the etiologic agent into the subcutaneous tissues with sharp objects (e.g., thorn) contaminated with actinomycetes or true fungi. The patients with mycetoma have been reported from all parts of the globe, however, it principally occurs in tropical and subtropical regions such as India, Pakistan, Somalia and South America.<sup>5</sup> Actinomycetoma is often caused by aerobic actinomycetes such as *Nocardia brasiliensis*, *Actinomadura madura*, *A. pelletierri* and *Streptomyces somaliensis*.<sup>7-9</sup>

## Case Presentation

The patient was a 60-year-old housewife, who lived in a village of Ahwaz, southwestern Iran. Her left foot had been hurt with a plant stick in farm 20 years before. After approximately 1.5 years, the first symptoms of the disease were started. Lesion was initially limited to the injured site, but it gradually became swollen and enlarged (figures 1 and 2). The lesions were localized. Physical examination revealed swelling of the left foot with many nodules and sinus tracts. She had trouble with walking and could not wear shoes, because of the violent pain and tumor on her foot. The patient was diagnosed as having bacterial infection and tuberculosis during the last 20 years. Different treatments were applied with no benefits.

Department of Medical Mycology and Parasitology, <sup>1</sup>Dermatology, School of Medicine, Jundishapour University of Medical Sciences, Ahwaz, Iran.

### Correspondence:

Ali Zarei Mahmoudabadi PhD, Department of Medical Mycology and Parasitology, Jundishapour University of Medical Sciences, Ahwaz, Iran.

**Tel:** +98 611 3330074

**Fax:** +98 611 3332036

**Email:** [zareia40@hotmail.com](mailto:zareia40@hotmail.com)

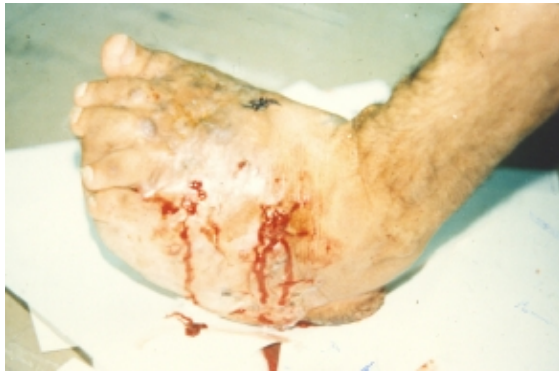

Figure 1: Actinomycetoma of foot.

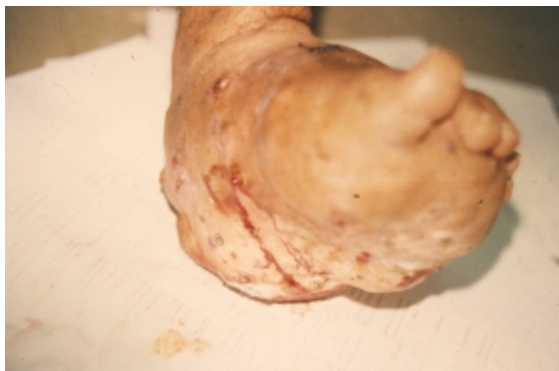

Figure 2: Multiple sinus openings in foot.

The skin of the affected area of her left foot was cleansed with 70% alcohol. The pus was then collected in a sterile plate after applying pressure around the sinus tracts. On direct examination of the collected pus, yellowish soft large and lobulated granules were observed. Direct smear from the crushed grains, stained with Gram and Kinyon acid fast staining, revealed Gram-positive and non-acid-fast branching filaments with a diameter less than one  $\mu\text{m}$ . Histopathologic examination of the granules revealed the presence of a dense peripheral border and loose and empty center (figure 3). Granules were washed in sterile saline. They then were crushed and cultured in duplicate on Sabouraud's dextrose agar (SDA), blood agar and brain heart infusion agar (BHI). Cultures were incubated at both 27°C and 37°C for several weeks. No growth was obtained after six weeks of incubation.

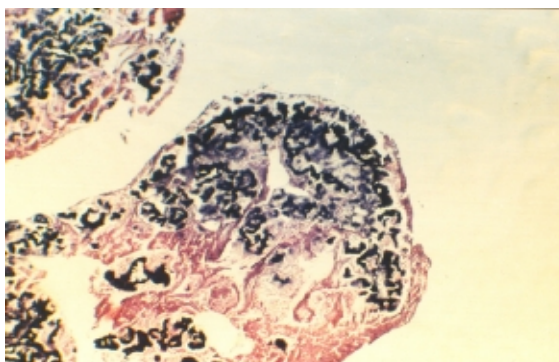


Figure 3: Section of a granule (x20).

## Discussion

Mycetoma is a disease of the tropical and subtropical regions. It is observed mostly in those with low socio-economic status working outdoor. Walking barefoot, lack of enough coverage of body surface and malnutrition are predisposing factors for the disease. Mycetoma occurs mostly in men with a male:female ratio ranging from 2:1 to 5:1 in those aged between 20 and 40 years.<sup>5</sup> The disease is more reported from Africa and India than other parts of the world. However, mycetoma has been reported from other countries as case reports. All etiologic agents of actinomycetoma are aerobic micro-organisms (with exception of *Actinomyces israelii*) which live freely on soil, plants, sticks and vegetable debris in environment.<sup>7</sup> At the present, 10 different species of actinomycetes have been identified as the etiologic agents of actinomycetoma in the world. The commonest species of actinomycetoma are *N. asteroides*, *N. brasiliensis*, *N. caviae*, *A. madura*, *A. pelletierri* and *S. somaliensis*.<sup>2,5-8</sup>

Asgari, et al, has reported the first eight patients with mycetoma with identified etiologic agents from Iran. The disease has been found among the inhabitants of Guilan, Mazandaran, Khuzestan, Tehran, Isfahan, Azarbayjan, Zanzan, Khorasan, Arak, Kerman, Hamadan, Gorgan, Bushehr, Bandar Abbas and Qazvin provinces.<sup>2</sup> From the 69 reported cases of mycetoma from Iran, 31 were reported from the northern provinces (Guilan, Mazandaran and Gorgan) and 19 were from southern provinces (Khuzestan, Bushehr and Bandar Abbas). The most common isolates observed in patients with mycetoma from Iran are actinomycetoma. Zarei Mahmoudabadi,<sup>2</sup> and Zarrin and Zarei Mahmoudabadi,<sup>5</sup> have reported several patients with actinomycetoma caused by *Nocardia* spp. from Ahwaz, Khuzestan province. Moreover, Griffiths, et al,<sup>10</sup> reported seven patients with actinomycetoma caused by *N. asteroides* and *A. madura*. Khosravi, et al,<sup>7</sup> and Ravaghi,<sup>6</sup> were, respectively, reported two cases of actinomycetoma caused by *N. asteroides*. Thirteen patients with mycetoma (12 with actinomycetoma) were reported by Moghadami, et al,<sup>8</sup> the causative agents were *N. asteroides* and *A. madura*.

Mycetomas in Iran were mainly seen in foot and less commonly on hand, ankle and other parts; most of patients were male.<sup>3,6-8</sup> The identified etiologic agents of actinomycetoma in Iran are *N. caviae*,<sup>3,9,10</sup> *N. asteroides*,<sup>2,6-8</sup> *A. madura*,<sup>3,8</sup> and *N. brasiliensis*.<sup>2</sup> *N. asteroides* and *A. madura* have been identified as the commonest causes of actinomycetoma in Iran.<sup>2,8</sup> The genus of *Nocardia* is soil saprophyte.

Although in the study of our 60-year-old woman, the etiologic agent was not accurately identified, from the present information, her clinical presentation and the time course of her disease, we presumably suggest that the causative organism was *A. madura*. The etiologic agents of mycetoma frequently fail to grow in culture, and thus its laboratory identification is often difficult.

#### References

- 1 Anaissie EJ, McGinnis MR, Pfaller MA. Clinical Mycology, Philadelphia; Elsevier Sciences; 2003. p. 463-4.
- 2 Zarei Mahmoudabadi A. Actinomycetoma: A case report. *J Kerman Uni Med Sci* 1995; 2: 154-7. (in Persian)
- 3 Asgari M, Alilou M. Mycetoma in Iran. *Ann Soc Belge Med Trop* 1972; 52: 287-305.
- 4 Fahal AH, Hassan MA. Mycetoma. *BR J Surg* 1992; 79: 1138-41.
- 5 Zarrin M, Zarei Mahmoudabadi A. Report of two cases of actinomycetoma in Khuzestan. *Sci Med J Ahwaz* 1998; 24: 92-7. (in Persian)
- 6 Ravaghi M, Aflatouni M. Mycetoma caused by *Nocardia asteroides*. *J Pak Med Assoc* 1978; 28: 35-6.
- 7 Khosravi AR, Emami M. Study of two cases of cutaneous and subcutaneous nocardiosis. *Med J Islam Rep Iran* 1991; 5: 169-72.
- 8 Moghaddami M, Kordbachae P. Report thirteen cases of mycetoma. *Med J Islam Rep Iran* 1989; 3: 183-6.
- 9 Shoar MG, Shidfar MR, Zomorodian K, et al. A case of actinomycotic mycetoma in hand treated successfully with cotrimoxazole and streptomycin. *Pak J Med Sci* 2003; 19: 310-2.
- 10 Griffiths WA, Kohout E, Vessal K. Mycetoma in Iran. *Int J Dermatol* 1975; 14: 209-13.