

# Primary Hydatidosis of Uterus and Left Fallopian Tube

B. Namavar Jahromi, A.R. Talei<sup>1</sup>,  
S.Z. Tabei<sup>2</sup>

## Abstract

Hydatid cysts are known to occur in most organs especially in the endemic areas. However, its occurrence in uterus is extremely rare and it mostly occurs as a secondary involvement. Herein we reported on a 25-year-old woman with primary involvement of the uterus and left fallopian tube. The patient presented with a colicky abdominal pattern and fever and was admitted to the Emergency Ward.

**Iran J Med Sci 2007; 32(2): 118-120.**

**Keywords** • Hydatid cyst • uterus • fallopian tube diseases • female genitalia • *Echinococcus granulosus* • *Echinococcus multilocularis*

## Introduction

**H** ydatid disease or echinococcosis is a zoonosis and human is an accidental intermediate host.<sup>1</sup> Hydatid cysts are most frequently seen in the liver (60%) followed by the lung (30%).<sup>2</sup> Its incidence in female reproductive system constitutes about 0.5% of all hydatid cysts.<sup>3</sup> These cases are usually secondary to the accidental rupture of a cyst in other areas and primary involvement of the female reproductive system has rarely been described. Herein, we reported on a woman with primary involvement of the uterus and left fallopian tube who presented with unusual symptoms.

## Case Report

A 25-year-old single woman was brought to the Emergency Room with severe abdominal pain since 24 hours prior to admission. She had felt heaviness in the suprapubic area and occasional vague lower abdominal discomfort since two months before, but no investigation was done. One day prior to admission, she developed severe pain in her lower abdomen, which was constant with colicky exacerbations associated with nausea and several episodes of vomiting. The patient had regular menstruations with occasional passage of small grape-like material in her menstrual blood. The patient had no history of weight loss or urinary problem. However, she had a questionable history of pelvic cystectomy nine years before in another hospital.

Physical examination on arrival showed a blood pressure of 110/70 mm Hg, pulse rate of 100 beats/min, respiratory rate of 14/min and an oral temperature of 38.1°C. Her abdomen was fatty with a non-mobile mass in midline lower abdomen with deviation to the left and which was as large as a 16-week pregnant uterus. She had tenderness and rebound on the left lower quadrant of her abdomen. Rectal examination revealed

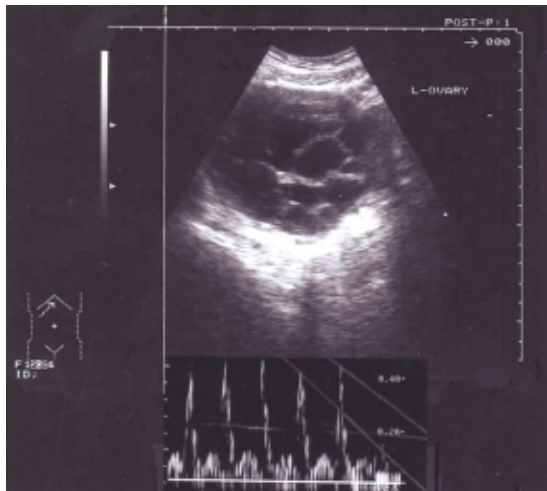
Departments of Obstetrics and  
Gynecology,  
<sup>1</sup>General Surgery and <sup>2</sup>Pathology,  
Shiraz University of Medical Sciences,  
Shiraz, Iran.

### Correspondence:

Bahia Namavar Jahromi MD,  
Department of Obstetrics and  
Gynecology,  
Shahid Faghihi Hospital,  
Shiraz, Iran.  
**Tel:** +98 711 6271329  
**Fax:** +98 711 6272492  
**Email:** [namavarb@sums.ac.ir](mailto:namavarb@sums.ac.ir)

a solid, firm, non-mobile mass in the midline deviated towards the left.

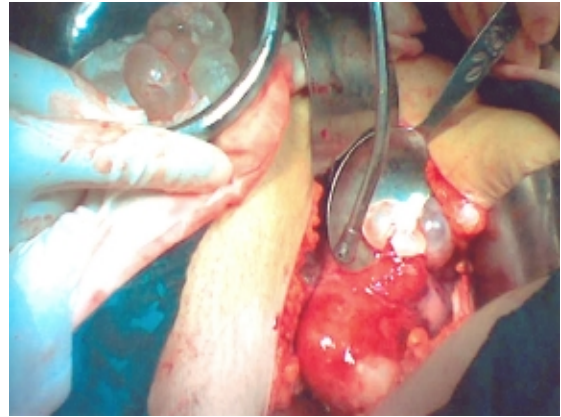
Laboratory investigations revealed a hemoglobin concentration of 11.6 g/dL, total leukocyte count of 10700/mL with 66% polymorphonuclear cells, 20% lymphocytes and 2% eosinophils, blood urea nitrogen of 12 mmol/L, and serum creatinine of 1.4  $\mu$ mol/L. Urinalysis, serum electrolytes, blood coagulation profiles and liver function tests were normal. Stool guaiac and human chorionic gonadotropin (HCG) were negative. Chest x-ray was normal. Ultrasonography revealed normal abdomen with fullness of pelvocalyceal system of the left kidney. Uterus and right ovary seemed normal with normal endometrial thickness. A large cystic mass measuring 100 $\times$ 75 $\times$ 80 mm was seen in the left adnexa containing multiple 30 $\times$ 30 mm cysts. Color Doppler sonography showed normal blood flow to the cystic lesion with evidence of a high resistive index (fig 1).



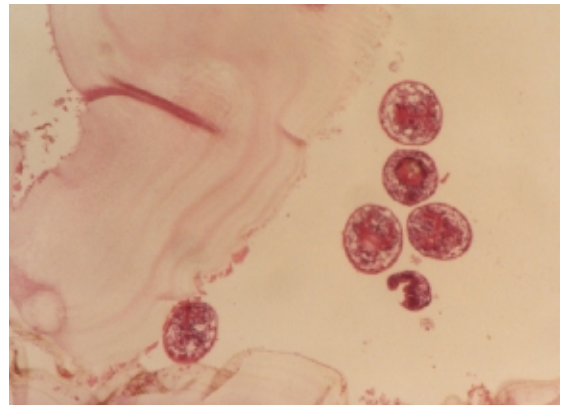
**Fig 1:** Ultrasonographic appearance and color Doppler pattern of the uterine hydatid cyst.

In view of the patient's increasing symptoms and acute surgical signs, exploratory laparotomy was performed. During the operation, severe dense adhesion of the bowel and omentum to uterus was seen. The uterus was large and had irregular shape and soft cystic consistency. The right fallopian tube and ovary were embedded in severe adhesions. The left tube was dilated about 45 mm in the ampullary area. The tube was densely adhered to the pelvic wall. While releasing the adhesions, the antimesenteric border of the left tube was accidentally opened through which a hydatid cyst protruded out. Since the diagnosis was made, the abdomen was irrigated with 0.5% silver nitrate and peritoneal cavity was packed thoroughly; great caution was taken to avoid rupture of intact cysts. The uterine wall was opened. A thin serous layer and myometrium had covered the intramural cavity. There were

more than 20 hydatid cysts ranging from five to 35 mm in diameter (fig 2). Its outer wall was resected and a Hemo-vac-drain was placed in the space. The left tube also contained about seven cysts ranging from five to 20 mm in diameter. After a careful exploration, the abdominal cavity was thoroughly washed and closed. Several hours after the operation, the patient passed four more daughter cysts through her vagina. Microscopic examination of the cysts confirmed the diagnosis of hydatid cyst (fig 3).



**Fig 2:** Uterus containing daughter cysts



**Fig 3:** Microscopic view of laminated layers and scolices (H&E,  $\times$ 20)

Oral albendazole, 400 mg twice a day, was started for the patient. Computed tomography of the chest, abdomen, pelvis, and repeated sonography after operation did not show any cystic lesions. The pelvocaliectasis of the left kidney disappeared after the operation.

Old medical chart of the patient, related to nine years before, showed that she had been operated for a pelvic mass with impression of ovarian tumor. The mass had been as big as a 20-week pregnant uterus causing bilateral hydronephrosis. Tubes were normal at that time. However, during operation, the mass was found to be a hydatid cyst of uterus with multiple daughter cysts, which were evacuated. Oral albendazole, 400 mg twice a day, had then been prescribed for three months. So, we realized that our patient had recurrence of a

primary uterine hydatid cyst with progression of the disease to the left fallopian tube.

## Discussion

Although hydatid disease is endemic in Iran, primary involvement of pelvic organs is extremely rare. Hydatid cyst in the pelvic cavity can be considered primary when no other cysts are present in the common sites of occurrence. In such a case, a hydatid embryo gains access to the pelvis by either hematogenous or lymphatic routes.<sup>4</sup> Our patient had hydatid cysts in the uterus and left fallopian tube but there were no other hydatid cysts in the liver, spleen, kidney, lungs, or peritoneal cavity. It can thus be considered as a primary involvement. By reviewing the medical literature, only few such cases have been reported.<sup>5-8</sup> All these reported cases presented as pelvic tumors. However, our patient presented with acute abdomen who needed emergency operation.

The symptoms of hydatid disease in genital organs are not specific. They can be similar to those of ovarian cyst or can manifest themselves by extrinsic pressure upon adjacent organs. Passage of grape-like cysts with menstrual flow, which was reported by our patient, is a very rare symptom that probably originated from the left tube, then passed through the uterus. The presence of symptoms is always related to the size of the cysts; those less than eight cm in diameter are rarely symptomatic.<sup>9</sup> These cysts may rarely present with acute symptoms related to rupture and leakage, hemorrhage, or infection. The cysts may cause fever, pruritus, urticaria, eosinophilia, or anaphylaxis.<sup>10</sup> Eosinophilia is encountered in almost half of the infested persons.<sup>2</sup> However, our patient did not show eosinophilia; she developed fever and acute symptoms instead, probably because of episodic leakage of the tubal cysts.

Unilocular hydatid cyst is caused by *Echinococcus granulosus* while the alveolar type is caused by *Echinococcus multilocularis*.<sup>5</sup> Alveolar type with its special morphologic and histologic characteristics, as happened in our case, occurs more frequently in Northern Hemisphere and produces more generalized granulomatous reaction; it can present like a malignancy.<sup>11</sup> Surgical resection is the treatment of choice for such cases. Complete removal of the parasite continues to offer the best chance of cure. Hysterectomy is the treatment of choice after menopause. However, more conservative surgery is advised for young patients in reproductive age. Ongoing

therapy with albendazole for at least two years after surgery is recommended. For cases in whom complete resection is not possible, albendazole should be continued indefinitely with careful monitoring.<sup>10</sup> Response to treatment is best assessed by serial imaging studies with attention to the cyst size and consistency. Our patient did not show any signs of recurrence after three months of follow-up.

In conclusion, pelvic hydatid disease should be considered in the differential diagnosis of pelvic masses in endemic areas. Evaluation of medical history and current symptoms together with a high index of suspicion is needed for correct preoperative diagnosis.

## References

- 1 Townsend CM, Beauchamp RD, Evers BM, Mattox KL. Sabiston Textbook of Surgery, 17th ed. Saunders, Philadelphia; 2004. p. 1542-4.
- 2 Georgakopoulos PA, Gogas CG, Sariyannis HG. Hydatid disease of the female genitalia. *J Obstet Gynaecol* 1980; 55: 555-9.
- 3 Sahu B, Regmi K. Hydatid cyst of ovary. A case report. *Indian J Pathol Microbiol* 1999; 42: 501-2.
- 4 Seenu V, Misra MC, Tiwari SC, et al. Primary pelvic hydatid cyst presenting with obstructive uropathy and renal failure. *Postgrad Med J* 1994; 70: 930-2.
- 5 Okumuş Y, Tayyar M, Patiroğlu T, Aygen E. Uterine hydatid cyst. *Int J Gynaecol Obstet* 1994; 45: 51-3.
- 6 Emamy H. Primary hydatid of uterus report of case and review of literature. *Pahlavi Med J* 1975; 6: 153-9.
- 7 Komongui DG, Diouf A, Dao B, et al. Hydatid cyst of the uterus (apropos of a case seen at the gynecologic and obstetrical clinic of the C.H.U. of Dakar). *Dakar Med* 1990; 35: 162-7.
- 8 Rahman MS, Rahman J, Lysikiewicz A. Obstetric and Gynecological presentations of hydatid disease. *Br J Obstet Gynaecol* 1982; 89: 665-70.
- 9 Tsakayannis DE, Mitchell K, Kozakewich HP, Shamberger RC. Splenic preservation in the management of splenic epidermoid cysts in children. *J Pediatr Surg* 1995; 30: 1468-70.
- 10 Kasper DL, Braunwald E, Fauci AS, et al. Harrison's principles of Internal medicine, 16th ed. McGraw Hill, New York; 2005. p. 1275-6.
- 11 Brunicaudi FC, Andersen DK, Billiar TR, et al. Schwartz's Principles of surgery. 8th ed. New York: McGraw-Hill; 2005. p. 1167.