

The Role of Appendix in the Management of Biliary Atresia Associated with Bowel Atresia

Dear Editor,

Biliary atresia is characterized by the progressive obliteration of extra- and intrahepatic biliary duct system leading to the obstruction of bile flow in infancy. The cause(s) of biliary atresia remain unclear and many surgical options for bypassing the atretic segment have been described.¹⁻³ Biliary atresia may be associated with small bowel atresia. The surgical interventions for biliary drainage in this co-morbidity are problematic because of associated inadequate length of bowel for reconstruction while the combined effects of short bowel syndrome and delayed return of adequate motility and absorptive capacity cause the ascending cholangitis.^{4,5}

A 2-day-old boy was referred to us because of jaundice, bilious vomiting, and abdominal distension. He was diagnosed as having proximal jejunal atresia. During an operative exploration, the intact remaining of the terminal ileum (10 cm) was anastomosed with proximal pouch (15 cm) end to back fashion but the gall bladder was ignored. He had a good postoperative course and tolerated feeding on the 10th postoperative day. However, his stool was clay colored and the jaundice persisted. We evaluated him for any surgical causes of neonatal jaundice which showed the absence of gall bladder in abdominal sonography and there was no evidence of excretion of bile into the bowel in HIDA scan. He underwent the second laparotomy and the appendico-duodenostomy was performed for biliary atresia because of a short bowel [figure 1]. The patient developed greenish stool on the 4th postoperative day and discharged with medication.

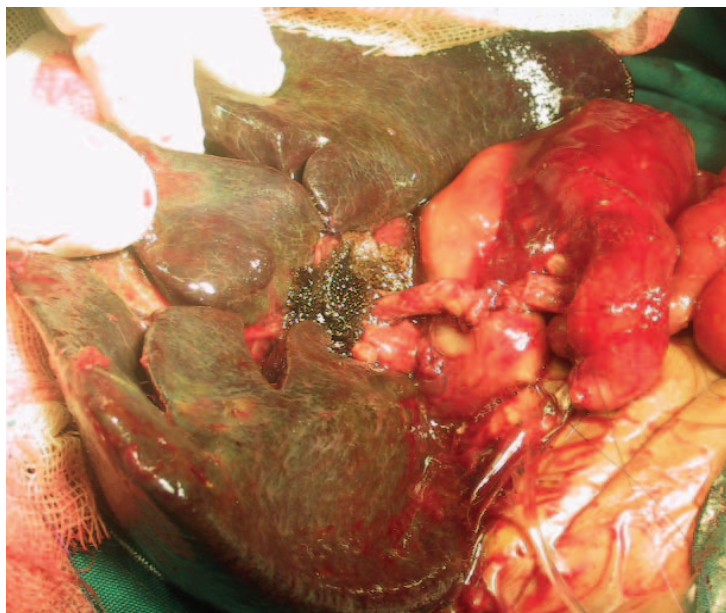


Figure 1: Transferred appendix used as a conduit between hilar plate and duodenum.

Jaundice in small bowel atresia is not unusual because 20% of cases with small bowel atresia are associated with jaundice.⁶ The diagnosis of small bowel atresia is definite in all cases at the first glance, but accompanying biliary atresia is not usually detected because of ignoring the gallbladder in all cases during the first operation or having a preoperative ultrasonography without details of the gallbladder. Therefore, we recommend that the gallbladder be examined during the first operation for small bowel atresia. Many techniques for utilizing the appendix as a biliary conduit have been recommended with different results. Appendico-duodenostomy can prevent the reflux cholangitis and save the entire small bowel.⁷ Therefore, appendix as an anti-reflux conduit, is useful for reconstruction of biliary tree and prevention of ascending cholangitis.

Seyed Mohammad Vahid Hosseini, Mohammad Zarenezhad, Soheil Benrazavi

Department of Pediatric Surgery,
Shiraz University of Medical Sciences,
Shiraz, Iran.

Department:

Seyed Mohammad Vahid Hosseini MD,
Department of Pediatric Surgery,
Shiraz University of Medical Sciences,
Shiraz, Iran.

Tel: +98 711 6263041

Fax: +98 711 6239105

Email: psrg.sums@yahoo.com

Received: 18 March 2009

Accepted: 23 July 2009

References

- 1 Davenport M, Savage M, Mowat AP, Howard ER. Biliary atresia splenic malformation syndrome: an etiologic and prognostic subgroup. *Surgery* 1993; 113: 662-8.
- 2 Morecki R, Glaser JH, Cho S, et al. Biliary atresia and reovirus type 3 infection. *N Engl J Med* 1984; 310: 1610.
- 3 Jenner RE. New perspectives on biliary atresia. *Ann R Coll Surg Eng* 1978; 60: 367-74.
- 4 Miyano T, Suruga K, Suda K. Abnormal choledochopancreaticoduodenal junction related to etiology of infantile obstructive jaundice diseases. *J Pediatr Surg* 1979; 14: 16-26.
- 5 Le Coultre C, Fête R, Cuendet A, Berclaz JP. An unusual association of small bowel atresia and biliary atresia: A case report. *J Pediatr Surg* 1983; 18: 136-7.
- 6 DeLorimier AA, Fonkalsrud EW, Hays DM. Congenital atresia and stenosis of the jejunum and ileum. *Surgery* 1967; 65: 819-27.
- 7 Crombleholme TM, Harrison MR, Langer JC, Longaker MT. Biliary appendico-duodenostomy: A nonrefluxing conduit for biliary reconstruction. *J Pediatr Surg* 1989; 24: 665-7.