

# Protective Effect of Safranal against Hexachlorobutadiene-Induced Nephrotoxicity in Rat

M.T. Boroushaki, H. Mofidpour<sup>1</sup>,  
H.R. Sadeghnia

## Abstract

**Background:** Hexachlorobutadiene (HCBd) is a potent nephrotoxin in rodents, which can cause degeneration, necrosis and regeneration in renal tubular epithelial cells. It has been shown that safranal, the active ingredient of saffron, has a protective effect against ischemic injuries. The aim of this study was to examine the protective effect of safranal against HCBd-induced nephrotoxicity in rats.

**Method:** Thirty Wistar albino rats were randomly divided in five groups. The rats received a single dose of corn oil 1ml/kg (group1), HCBd 50mg/kg (group 2), or safranal at doses of 0.5, 0.25 and 0.1 ml/kg one hour before HCBd (50mg/kg) injection (groups 3-5). All injections were carried out intraperitoneally. Urine samples were collected one day before, and one day after injections. On day 3 the animals were sacrificed and both kidneys were removed. The right kidney was fixed in formalin for histological examination and the left kidney was homogenized for measuring malondialdehyde (MDA). Blood samples were taken by cardiac puncture and used for the measurement of urea, creatinine, glucose and protein concentrations.

**Results:** Blood urea concentration in HCBd treated group was significantly higher compared with group 3 ( $p<0.01$ ) and groups 1 and 4 ( $p<0.001$ ). There was no significant difference in urea concentrations between group 5 and HCBd treated group. Urinary concentration of glucose was significantly higher in group 2, compared with groups 1, 3 and 4 ( $p<0.001$ ). No significant differences were observed in urinary glucose concentrations between HCBd- and safranal (0.1ml/kg)-treated groups. Concentration of protein was also significantly higher in group 5 than those of other tested groups ( $p<0.001$ ).

**Conclusion:** Safranal at doses of 0.25 and 0.5ml/kg has a protective effect against HCBd-induced nephrotoxicity in rats.

**Iran J Med Sci 2007; 32(3): 173-176.**

**Keywords** • Hexachlorobutadiene • safranal • malondialdehyde • nephrotoxicity

## Introduction

**H**exachlorobutadiene (HCBd) is a potent nephrotoxin in rodents,<sup>1</sup> which can cause degeneration, necrosis, and regeneration in renal tubular epithelial cells.<sup>2-4</sup>

Department of Pharmacology and  
Pharmacological Research Center of  
Medicinal Plants, Ghaem Hospital,  
<sup>1</sup>Department of Anatomy and Histology,  
School of Medicine,  
Mashhad University of Medical Sciences,  
Mashhad, Iran.

### Correspondence:

Mohammad Taher Boroushaki Ph.D,  
Department of Pharmacology,  
Ghaem hospital,  
Mashhad, Iran.  
Tel: +98 511 8440352  
Fax: +98 511 8413579  
Email: m-boroushaki@mums.ac.ir

Its toxicity is due to its conjugation by glutathione (GSH) to form glutathione s-conjugate, and finally to the related cysteine-conjugate. This metabolite is actively taken up by kidneys and is cleared in the renal tubular epithelial cells to a reactive thiol derivative by the enzyme  $\beta$ -lyase. The reactive thiol derivative covalently binds to macromolecules,<sup>5</sup> and causes proximal tubular necrosis in corticomedullary junction.

*Crocus sativus* L. (Iridaceae), commonly known as saffron, is used in folk medicine for various purposes such as an aphrodisiac, antispasmodic, expectorant and antiedematogenic remedy.<sup>6</sup> Modern pharmacological studies have demonstrated that saffron extracts have antitumor,<sup>7-9</sup> radical scavenger, hypolipemic,<sup>10</sup> and anticonvulsant effects,<sup>11</sup> and also improve learning and memory.<sup>10,12</sup> Chemical studies have shown the presence of constituents such as crocin, crocetin, safranal and picrocrocin in *C. sativus* extracts.<sup>13-15</sup> Among these constituents, crocetin is mainly responsible for the mentioned pharmacological activities of saffron.<sup>10</sup>

There are several studies indicating that saffron has antioxidant activity.<sup>16-19</sup> A study has demonstrated that the aqueous extract of saffron could inhibit cisplatin-cyclophosphamide-, mitomycin-C- and urethane-induced alterations in lipid peroxidation in murine.<sup>20</sup> Furthermore, our laboratory findings showed that safranal is able to protect kidney against ischemia / reperfusion injury in rat.<sup>21</sup> Therefore, this study was undertaken to investigate the possible protective effect of safranal on HCBd-induced nephrotoxicity.

## Materials and Methods

Thirty Wistar albino rats (150-200g) of either sex (Animal Breeding Unit, Department of pharmacology, Ghaem hospital, Mashhad, Iran) were housed in a controlled environment of 50% humidity, 20°C temperature and 12 hours light period. After acclimatization, rats were divided randomly into 5 groups; 6 rats in each group. A 24-hour urine sample was collected from each rat using a metabolic cage.

Then, rats received intraperitoneally a single dose of corn oil 1ml/kg (group 1); HCBd (Fluka chemie, Switzerland) 50mg/kg (group2); and groups 3,4,5 received safranal (Fluka chemie, Switzerland) 0.5, 0.25 and 0.1mg/kg respectively to be followed by HCBd (Fluka chemie, Switzerland) 50mg/kg one hour later.

Twenty four hours after injections, urine samples were collected. Urinary glucose and protein concentrations were determined by enzymatic (glucose oxidase and turbidometry methods, respectively (Thiobarbituric acid: Merck, Dramstadt, Germany). The Animals were then sacrificed under ether anesthesia. Blood samples were taken by cardiac puncture for measuring urea and creatinine concentrations as indicators of renal function, using urease and Jaffé methods, respectively. Both kidneys were removed. The left kidney was homogenized for measuring MDA by thiobarbituric acid assay. The right kidney was fixed in formalin. Then histological studies were performed in prepared sections stained in haematoxylin and eosin (H&E).

## Statistical Analysis

Data were expressed as mean  $\pm$  SEM. The differences among different treated groups were analyzed by one-way ANOVA followed by Tukey test.  $P < 0.05$  was considered statistically significant.

## Results

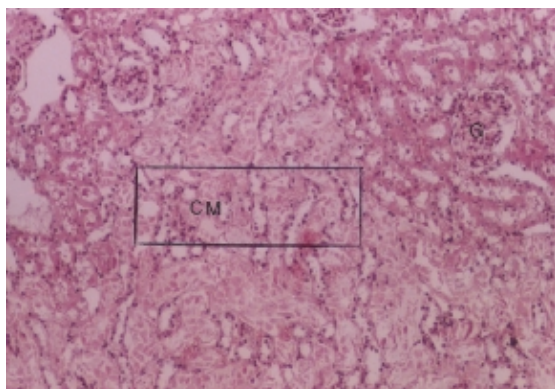
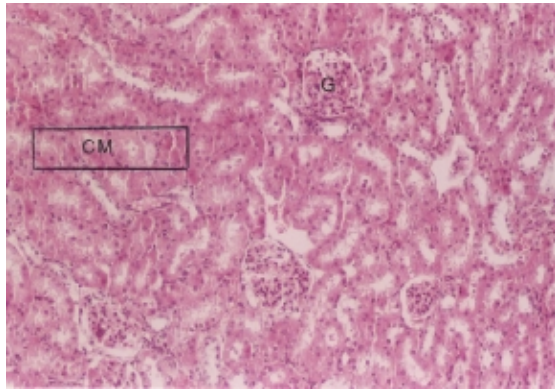
Serum concentrations of urea, creatinine, glucose, protein and MDA are shown in table 1.

Blood urea concentration in HCBd treated group was significantly higher compared with group 3 ( $p < 0.01$ ) and groups 1 and 4 ( $p < 0.001$ ) (table 1). There was no significant difference in urea concentrations between group 5 and HCBd treated group. There were no significant differences in creatinine and MDA concentrations between HCBd treated and other experimental groups (table 1). Urinary concentration of glucose was significantly higher in group 2, compared with groups 1, 3 and 4 ( $p < 0.001$ ) (table 1).

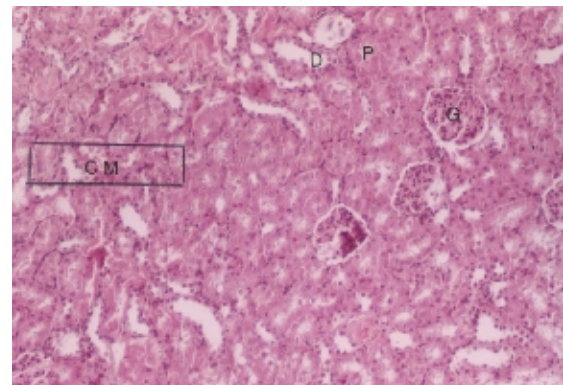
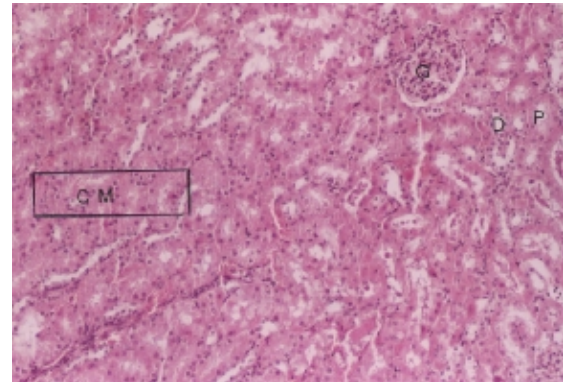
**Table 1:** Biochemical parameters in different groups

Animal groups	Urea (mg/dl)	Creatinine (mg/dl)	Glucose (mg/dl)	Protein (mg/dl)	MDA (nmol/g)
Group 1 (n=6)	59 $\pm$ 3.8***	0.63 $\pm$ 0.03ns	7 $\pm$ 0.7***	1.68 $\pm$ 0.95***	12 $\pm$ 1.9 ns
Group 2 (n=6)	115.75 $\pm$ 0.4	1 $\pm$ 0.19	38.25 $\pm$ 0.63	9.85 $\pm$ 0.76	16.4 $\pm$ 3.32
Group 3 (n=6)	76.5 $\pm$ 6.5**	1.07 $\pm$ 0.14 ns	21.24 $\pm$ 1.18***	1.3 $\pm$ 0.28***	9.45 $\pm$ 0.38 ns
Group 4 (n=6)	68.25 $\pm$ 2.78***	0.68 $\pm$ 0.28 ns	24.25 $\pm$ 1.11***	1.75 $\pm$ 0.43***	13.66 $\pm$ 1.6 ns
Group 5 (n=6)	122.75 $\pm$ 8.7 ns	1.15 $\pm$ 0.11 ns	39.25 $\pm$ 1.25ns	3.35 $\pm$ 0.87***	13.74 $\pm$ 0.7 ns

\*\*  $p < 0.01$  compare to group 2, \*\*\*  $p < 0.001$  compare to group 2  
ns: Non-significant, data shown as mean  $\pm$  SEM



**Figure 1:** (up), representation of a normal rat kidney. All anatomical structures look normal. (Down), representation of rat kidney in HCBd-treated group. CM junction (boxed area) has been extensively damaged  
CM: cortico-medullary junction G: glomerulus



**Figure 2:** (Up) representation of rat kidney in safranal-treated (0.5ml/kg) group (Down) representation of rat kidney in safranal-treated (0.25ml/kg) group All anatomical structures including CM junction look normal  
CM: cortico-medullary junction D: distal tubules P: proximal tubules

No significant differences were observed in urinary glucose concentrations between HCBd- and safranal (0.1ml/kg)-treated groups. Concentration of protein was also significantly higher in group 5 than those of other tested groups ( $p < 0.001$ ) (table 1).

Light microscopic examination of kidneys' sections showed a normal appearance for glomerulus, Bowman's capsule, proximal, distal and collecting tubules in corn oil treated group (control group). However an extensive damage was observed in straight portion of proximal tubules in groups 2 and 5 (figure.1). Other parts of kidney such as cortex and medulla were normal in groups 2 and 5. On the other hand all anatomical structures of kidney including renal tubules, had normal appearance in groups 3 and 4 (figure 2).

## Discussion

The findings indicated that safranal at doses of 0.25 and 0.5ml/kg is able to protect kidneys against HCBd-induced nephrotoxicity in rats. Concentrations of blood urea and creatinine and urinary concentrations of glucose and protein were used as indicators of damage to kidneys.

Creatinine concentration was the only parameter that showed no significant difference in all treated groups, compared with control group. However, it should be mentioned that the level of creatinine was higher in group 3 than that of group 2. This may be due to problems in measurement method. The level of urea, glucose and protein showed a rational consequence.

It has been shown that the aqueous extract of saffron inhibited oxidative stress induced by cisplatin, cyclophosphamide, mitomycin-C.<sup>20</sup> Saffron also elevates the intracellular reduced glutathione and related enzymes, i.e. glutathione reductase and glutathione-S-transferase.<sup>22</sup> In our study the lack of significant difference in MDA concentrations, an indicator of lipid peroxidation, suggests that HCBd-induced renal necrosis may not be due to oxidative stress. In other words the protective effect of safranal may not be related to its antioxidant activity.

HCBd enters the renal proximal tubular cells via organic anion transporter (OAT) system. Therefore, inhibition of the OAT system may contribute to the protective effect of safranal. In addition, safranal may alter the metabolism of HCBd by affecting the glutathione-

S-transferase and/or cysteine conjugate  $\beta$ -lyase activity to prevent toxic thiol formation. However, the exact mechanisms by which safranal protects HCBd-induced renal toxicity remains unknown. Further studies are needed to address this question.

The results of light microscopic examination of kidneys are in agreement with the biochemical findings. As shown in figures 1 and 2, there is substantial necrosis in renal proximal tubules in groups 2 and 5, while no abnormalities are apparent in groups 3 and 4.

In conclusion, safranal at the doses 0.25 and 0.5 mg/kg protects kidneys against toxic effects of HCBd in rats.

### Acknowledgement

This work was financially supported by the Vice-Chancellor for Research of Mashhad University of Medical Sciences.

### References

- 1 Lock EA, Ishmael J. The acute toxic effects of hexachloro-1: 3-butadiene on the rat kidney. *Arch Toxicol* 1979; 43: 47-57.
- 2 Berndt WO, Mehendale HM. Effects of hexachlorobutadiene (HCBd) on renal function and renal organic ion transport in the rat. *Toxicology* 1979; 14: 55-65.
- 3 Kirby GM, Bach PH. Enhanced HCBd nephrotoxicity in rats with a preexisting Adriamycin-induced nephritic syndrome. *Toxicol Pathol* 1995; 23: 303-12.
- 4 Schrenk D, Dekant W. Covalent binding of hexachlorobutadiene metabolites to renal and hepatic mitochondrial DNA. *Carcinogenesis* 1989; 10: 1139-41.
- 5 Larsen GL. Distribution of cysteine conjugate  $\beta$ -lyase in gastrointestinal bacteria and the environment. *Xenobiotica* 1985; 15: 199-209.
- 6 Zargari A. Medicinal Plants. 4th ed. Tehran, Iran: Tehran University Press, 1990. p. 574-78.
- 7 Nair SC, Pannikar B, Panikkar KR. Antitumor activity of saffron (*Crocus sativus*). *Cancer Lett* 1991; 57: 109-14.
- 8 Nair SC, Kurumboor SK, Hasegawa JH. Saffron chemoprevention in biology and medicine: a review. *Cancer Biother* 1995; 10: 257-64.
- 9 Salomi MJ, Nair SC, Panikkar KR. Inhibitory effects of *Nigella sativa* and saffron (*Crocus sativus*) on chemical carcinogenesis in mice. *Nutr Cancer* 1991; 16: 67-72.
- 10 Abe K, Saito H. Effects of saffron extract and its constituent crocin on learning behaviour and long-term potentiation. *Phytother Res* 2000; 14: 149-52.
- 11 Hosseinzadeh H, Khosravan V. Anticolvunsant effects of aqueous and ethanolic extracts of *Crocus sativus* L. stigmas in mice. *Arch Iran Med* 2002; 5: 44-7.
- 12 Zhang Y, Shoyama Y, Sugiura M, Saito H. Effects of *Crocus sativus* L. on the ethanol-induced impairment of passive avoidance performances in mice. *Biol Pharm Bull* 1994; 17: 217-21.
- 13 Tarantilis PA, Tsoupras G, Polissiou M. Determination of saffron (*Crocus sativus* L.) components in crude plant extract using high-performance liquid chromatography-UV-visible photodiode-array detection-mass spectrometry. *J Chromatogr A* 1995; 699: 107-18.
- 14 Escribano J, Alonso GL, Coca-Prados M, Fernandez JA. Crocin, safranal and picrocrocin from saffron (*Crocus sativus* L.) inhibit the growth of human cancer cells in vitro. *Cancer Lett* 1996; 100: 23-30.
- 15 Lozano P, Delgado D, Gómez D, et al. A non-destructive method to determine the safranal content of saffron (*Crocus sativus* L.) by supercritical carbon dioxide extraction combined with high-performance liquid chromatography and gas chromatography. *J Biochem Biophys methods* 2000; 43: 367-78.
- 16 Ochiai T, Ohno S, Soeda S, et al. Crocin prevents the death of rat pheochromocytoma (PC-12) cells by its antioxidant effects stronger than those of  $\alpha$ -tocopherol. *Neurosci Lett* 2004; 362: 61-4.
- 17 Martínez-Tomé M, Jiménez AM, Ruggieri S, et al. Antioxidant properties of Mediterranean spices compared with common food additives. *J Food Prot* 2001; 64: 1412-9.
- 18 Pham TQ, Cormier F, Farnworth E, et al. Antioxidant properties of crocin from *Gardenia jasminoides* Ellis and study of the reactions of crocin with linoleic acid and crocin with oxygen. *J Agric Food Chem* 2000; 48: 1455-61.
- 19 Verma SK, Bordia A. Antioxidant property of Saffron in man. *Indian J Med Sci* 1998; 52: 205-7.
- 20 Premkumar K, Abraham SK, Santhiya ST, Ramesh A. Protective effects of saffron (*Crocus sativus* Linn.) on genotoxins-induced oxidative stress in Swiss albino mice. *Phytother Res* 2003; 17: 614-7.
- 21 Sadeghnia HR, Boroushaki MT, Mofidpour H. Effect of safranal on lipid peroxidation level during renal ischemia-reperfusion injury in rat. *Iranian J Basic Medical Sciences* 2005; 8: 179-85. (Persian)
- 22 Nair SC, Salomi MJ, Varghese CD, et al. Effect of saffron on thymocyte proliferation, intracellular glutathione levels and its anti-tumor activity. *Biofactors* 1992; 4: 51-4.