

Successful Delivery after Uterine Rupture with Pervious Open Strassman Metroplasty for a Bicornuate Uterus in a Twin Pregnancy

Dear Editor

Congenital uterine anomalies arise out of incomplete bilateral paramesonephric (i.e., Müllerian) duct elongation, fusion, or canalization. The prevalence rate of such malformations has been reported at 5.5% in the general population, increasing up to 24.5% in women experiencing miscarriage and infertility.¹

A bicornuate uterus describes a type of lateral fusion defect, classified as a type III uterine anomaly according to the American Society for Reproductive Medicine. It constitutes 26% of all uterine malformations and may similarly lead to infertility, and even adverse pregnancy outcomes such as recurrent pregnancy loss or preterm delivery.²

Uterine rupture, defined as a complete disruption of all uterine layers including the serosa, can thus bring about changes in maternal or fetal status. The incidence of rupture is also higher in women with previous high vertical, especially fundal, incisions. In this respect, higher maternal age, advanced gestational age, birth weight over 4000 g, and multiple pregnancies are associated with increased risks of uterine rupture due to the excessive distention of the uterus.³

In this regard, Strassman metroplasty, also called "uteroplasty", is a standard surgical procedure for the correction of a bicornuate uterus, whose most frequent complications are intrauterine adhesions and uterine rupture in future pregnancies.⁴

In this report, a 29-year-old woman with 9 years' primary infertility and an *in vitro* fertilization twin pregnancy, together with a recent onset of acute abdominal pain at 33rd week of gestational age, was referred to Taleghani Hospital, in Tabriz, 2019. The patient was conscious and oriented, with a pulse rate of 150 beats per minute and blood pressure of 90/50 mm Hg. Furthermore, only one fetal heart rate (FHR) was detectable with no palpable uterine fundus. The abdomen was additionally distended, and the hemoglobin level was 6.4 g/dL.

This case had a previous history of open Strassman metroplasty for a bicornuate uterus two years earlier, but with no regular perinatal care. Therefore, she was immediately transferred to the operating room to undergo emergency laparotomy after primary resuscitation. Massive hemoperitoneum was visible, and there were approximately 2.5 liters of fresh blood inside the peritoneal cavity. The uterus had been entirely ruptured from its anterior part to its lower posterior segment (figure 1).

Both fetuses had been left in the abdominal cavity. Accordingly, they were removed from the abdominal cavity upon the opening of the peritoneum. Advanced cardiopulmonary support commenced immediately after delivery. The whole blood was ultimately removed from the intraperitoneal cavity, and the uterus was repaired in two layers using delayed absorbable interrupted sutures.

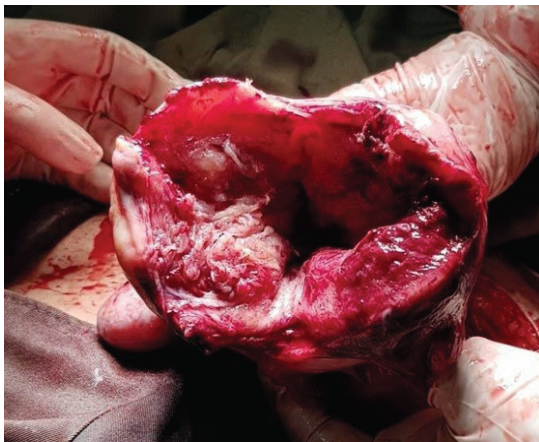


Figure 1: Excessive uterine distention due to advanced gestational age and twin pregnancy caused the complete rupture of the uterine fundus at the site of previous surgical scars.

To note, hysterectomy was not encouraged because of previous primary infertility and preterm delivery. Stable vital signs were detected the day after the operation, and the hemoglobin level was at 9.8 g/dL. Both newborns had acceptable general health conditions without any intubation. A few days later, the patient and both infants, with normal developmental patterns at their first birthday, were discharged.

Written informed consent was obtained from the patient prior to the publication of this article.

It is noteworthy that excessive uterine distention in advanced gestational age and multiple pregnancies can increase the risk of the rupture of previous uterine scars. With reference to available data, a full lower uterine segment with a thickness of less than 2.0 mm can be predictive of an amplified risk of rupture or dehiscence. However, no data are defining a normal myometrial thickness at sites other than the lower uterine segment.⁵

Reflecting on a case-by-case basis, antenatal hospitalization and careful maternal monitoring with regular measurements of uterine myometrial thickness at the site of the previous hysterotomy may reduce the risk of unexpected complications. Indeed, once the previous surgical scar is severely thin and prone to rupture, particularly when fetal lung maturation is confirmed through laboratory tests or clinical evaluations, elective delivery prior to 36 weeks of gestation should be considered. Furthermore, the sudden onset of abdominal pain, accompanied by FHR abnormalities and maternal hemodynamic instability, is highly suggestive of antepartum uterine rupture, requiring urgent delivery at any time of gestational age, regardless of the underlying etiology as took place in this case.⁶


In conclusion, although the surgical repair of uterine anomalies can improve pregnancy outcomes, more regular prenatal care, and early delivery are required to avoid adverse obstetric complications, especially in the cases of previous high vertical uterine incisions.

Acknowledgment

Our special thanks are due to Dr. Gholamreza Tizro, faculty member of Urmia University of Medical Sciences, who performed the first surgery on this patient.

Conflict of Interest: None declared.

Please cite this article as: Tabatabaei F, Mohammadi Youshanloie M. Successful Delivery after Uterine Rupture with Pervious Open Strassman Metroplasty for a Bicornuate Uterus in a Twin Pregnancy. *Iran J Med Sci*. doi: 10.30476/ijms.2021.88106.1872.

Fatemeh Tabatabaei¹, MD;  Maryam Mohammadi Youshanloie², MD

¹Department of Obstetrics and Gynecology, Division of Gynecologic Laparoscopic Surgeries, School of Medicine, Tabriz University of Medical Sciences, Tabriz, Iran;

²Department of Obstetrics and Gynecology, School of Medicine, Tabriz University of Medical Sciences, Tabriz, Iran

Correspondence:

Fatemeh Tabatabaei, MD;

First Floor of Shahryar Building, East Mahtab Ave., Takhti St., Valiasr, Postal code: 51579-88418, Tabriz, Iran

Tel: +98 41 33262754

Fax: +98 41 33375021

Email: drtabatabaeigyn@gmail.com

Received: 21 September 2020

Revised: 15 November 2020

Accepted: 18 November 2020

References

- 1 Chan YY, Jayaprakasan K, Zamora J, Thornton JG, Raine-Fenning N, Coomarasamy A. The prevalence of congenital uterine anomalies in unselected and high-risk populations: a systematic review. *Hum Reprod Update*. 2011;17:761-71. doi: 10.1093/humupd/dmr028. PubMed PMID: 21705770; PubMed Central PMCID: PMC3191936.
- 2 Karthik SDS, Kriplani A, Mahey R, Kachhawa G. Successful Reproductive Outcome After Laparoscopic Strassmann's Metroplasty. *J Hum Reprod Sci*. 2017;10:231-4. doi: 10.4103/jhrs.JHRS_11_17. PubMed PMID: 29142454; PubMed Central PMCID: PMC5672731.
- 3 Landon MB, Lynch CD. Optimal timing and mode of delivery after cesarean with previous classical incision or myomectomy: a review of the data. *Semin Perinatol*. 2011;35:257-61. doi: 10.1053/j.semperi.2011.05.008. PubMed PMID: 21962624.
- 4 Rechberger T, Monist M, Bartuzi A. Clinical effectiveness of Strassman operation in the treatment of bicornuate uterus. *Ginekol Pol*. 2009;80:88-92. PubMed PMID: 19338203.
- 5 ACOG Practice Bulletin No. 205 Summary: Vaginal Birth After Cesarean Delivery. *Obstet Gynecol*. 2019;133:393-5. doi: 10.1097/AOG.0000000000003079. PubMed PMID: 30681536.
- 6 Kirk EP, Chuong CJ, Coulam CB, Williams TJ. Pregnancy after metroplasty for uterine anomalies. *Fertil Steril*. 1993;59:1164-8. doi: 10.1016/s0015-0282(16)55970-6. PubMed PMID: 8495759.