



Clinical Efficacy of Intravenous Papaverine plus Ketorolac in the Emergency Treatment of Renal Colic: A Randomized, Double-blind Clinical Trial

Javad Mozafari¹, MD;  Ali Khavanin¹, MD; Ali Delirrooyfard¹, MD; Mohammadreza Piroozi¹, MD;  Naeimehossadat Asmari², PhD

¹Department of Emergency Medicine, Ahvaz Jundishapur University, Ahvaz, Iran;

²Anesthesiology and Critical Care Research Center, Shiraz University of Medical Sciences, Shiraz, Iran

Correspondence:

Mohammadreza Piroozi, MD;
No. 76, 45 Alley, Ghasrodasht St.,
Postal Code: 71836-44486,
Shiraz, Iran

Email: piroozi@sums.ac.ir
mrpiroozi@gmail.com

Received: 01 October 2023

Revised: 16 October 2023

Accepted: 11 November 2023

What's Known

- To control renal colic pain, different medications have been used. These include nonsteroidal anti-inflammatory drugs (NSAIDs), spasmolytics, and opiates, which have been used alone or in combination with different impacts on reducing pain. It is seen that combining papaverine and diclofenac has a great impact on pain suppression and consequently decreases the need to use opiates.

What's New

- In this study, the impact of ketorolac by itself and in combination with papaverine for decreasing the pain has been compared. It was concluded that the combined medications lead to the reduction of opiate use. Furthermore, the location of the stone is of great importance. It is seen that pain reduction in proximal and middle ureter stones is much greater than the renal and distal ureter.

Abstract

Background: Acute renal colic has been challenging and has brought many concerns for physicians and patients for centuries. This study aimed to evaluate the analgesic effect and safety of a combination of papaverine and ketorolac against ketorolac and placebo in treating acute renal colic.

Methods: This randomized clinical trial was performed in patients with renal colic from May 2018 to May 2020 in Ahvaz, Iran. Patients with colic pain due to sand or kidney stones underwent clinical examination. The pain intensified based on the visual analog scale (VAS) and the patients' need for rescue analgesia are considered as primary outcomes at various times after treatment. Patients were equally divided into two groups: A (ketorolac plus papaverine) and B (ketorolac plus placebo) by block balanced randomization method. Student *t* test, the Chi square, and ANOVA tests were used for statistical analyses, which were performed by SPSS 19.0. $P < 0.05$ was considered significant.

Results: A significant difference was observed in 280 patients (140 patients in each group) in pain intensity between both groups at 45 and 60 min. VAS scores in groups A and B were 5.08 ± 1.23 and 5.56 ± 1.11 in 45 min and 3.35 ± 1.47 and 3.92 ± 1.31 in 60 min ($P = 0.001$, $P = 0.002$), respectively. In subgroup analysis, the VAS score significantly decreased after taking the drug for middle and proximal ureteral stones at 45 and 60 min ($P < 0.001$). Rescue analgesics were required in 7 (5%) and 21 (15%) patients in groups A and B, respectively ($P = 0.005$). Side effects were similar in the two groups.

Conclusion: In this study, ketorolac, along with papaverine, was effective in acute renal colic control, and combination therapy with ketorolac and papaverine was associated with reduced use of other rescue analgesics.

Please cite this article as: Mozafari J, Khavanin A, Delirrooyfard A, Piroozi MR, Asmari N. Clinical Efficacy of Intravenous Papaverine plus Ketorolac in the Emergency Treatment of Renal Colic: A Randomized, Double-blind Clinical Trial. Iran J Med Sci. doi: 10.30476/ijms.2023.100323.3251.

Keywords • Pain • Renal colic • Analgesia • Papaverine • Ketorolac • Visual analog scale

Introduction

Kidney stones have been known as a common situation that causes severe acute pain for centuries.^{1, 2} Due to stone passage through the ureter, renal colic appears as acute pains in the sides. The classic clinical manifestations of acute renal colic include

pain from the side to the groin, accompanied by microscopic hematuria (85% of patients), nausea, vomiting, and costovertebral angle tenderness.³ Approximately 8 to 15% of Europeans and the North American population have experienced kidney stones of which 12% suffer from kidney stones. Approximately, two million outpatients in the United States have kidney stones. In 2000, the estimated cost was about \$2.1 billion for renal colic and kidney stones.⁴ The recurrence rate was about 50% after 10 years for those with a history of kidney stones. Kidney stones occur 2-3 times more in men than women; they are more common in adults and have the lowest prevalence in children. It was observed that in hot and dry climates, kidney stones are more common in white people. Two main causes of stones are believed to be decreased fluid intake and concentrated urine.⁵

Renal colic describes the pain caused by ureteral obstruction, although ureteral colic is a more accurate term. The ureter, pelvic system, and kidney capsule contract and expand as the result of this pain, which is originated from a spasm of the ureter around the stone. "Renal colic" is the most common cause of stones, which refers to a set of symptoms attributed to the kidneys and ureter. There are other inherent or occasional external causes such as lymphadenopathy. However, external causes usually present with milder and more chronic discomfort. Moreover, blood clots (from upper extremity bleeding) and sloughed renal papillae (occur usually in sickle cell disease, diabetes, or long-term use of pain relievers) are other common intrinsic causes of stones.⁶⁻⁸

Several methods have been proposed to control pain in patients with renal colic due to ureteral obstruction. Analgesia with nonsteroidal anti-inflammatory drugs (NSAIDs) is a common procedure in patients with renal colic such as ketorolac.⁹

Ketorolac is one of the primary choices for pain relief in patients with renal colic.¹⁰ However, some side effects such as nephropathy, headache, dizziness, gastrointestinal tract irritation, and bleeding were reported. However, papaverine hydrochloride is a non-selective phosphodiesterase inhibitor that has a direct relaxing effect on smooth muscle. It can be used in doses of 30 to 120 mg intravenously (IV). It is metabolized in the liver, and its half-life is 0.25 to 1.3 hours.^{11, 12} Antispasmodics may be alternative sedative agents for renal colic, because their mechanism neutralizes the process of pain stimulation due to isotonic ureteral contraction and has relatively few side effects.¹³ Using fixed-dose combination products (FDCs) in patients

with insufficient monotherapy is beneficial, since they show improved response. A significant therapeutic effect and faster action can be obtained by using the synergy or additive effect of drugs (using smaller doses of individual drugs). In addition, one active ingredient may impede the other's adverse reactions. Drug burden is reduced in patients by using FDCs. Therefore, medical adherence improvement is considered as another essential benefit of using FDCs.^{11, 12} This study was designed to evaluate the analgesic effect and safety of combination therapy with papaverine and ketorolac against ketorolac and placebo in treating acute renal colic.

Material and Methods

Trial Design

This study is a randomized, double-blind clinical trial study performed on patients with renal colic in the emergency department of Imam Khomeini and Golestan hospitals in Ahvaz from May 2018 to May 2020. It was approved by the Ethical Review Committee of Ahvaz Jundishapur University of Medical Science (AJUMS) (Ethics code: IR.AJUMS.REC.1397.822). The trial was registered at <https://www.irct.ir/> (IRCT20190217042738N1). All procedures were according to the ethical standards Declaration of Helsinki in 1964. Informed consent was obtained from patients before being included in this study.

Participants

Clinical signs included pain spreading to the genitalia, nausea, vomiting, urinary irritation, and tenderness in the costovertebral region. Patients who presented with colic pain due to sand or kidney stones underwent clinical examination and evaluation, including history, laboratory tests, physical examination, computed tomography (CT)-scan, abdominal radiographs of the kidneys, ureters, and bladder,¹⁴ and ultrasound.

Inclusion Criteria

Patients aged 17 to 55 who manifested acute colic pains that spreads from the sides of the groin and suprapubic were included in the study. The pain had an increasing and decreasing pattern, and minimum pain scoring of four or higher were included.

Exclusion Criteria

The patients who had any history or signs of an allergy to papaverine or ketorolac, aspirin or ibuprofen, history of complete heart block, paravertebral block type 2 and coronary artery disease, history of renal failure, history of asthma,

liver dysfunction, malignancy, peptic ulcer disease, coagulopathy, reluctance to cooperate in the continuation of the study, pregnant and lactating females, history of drug addiction, consumption of the previous analgesia during the last 6 hours, failure to confirm the diagnosis of rock or sand using the diagnostic modality of CT-scan, those who needed renal colic surgery, patients who could not have a CT-scan, and patients who decline to participate in the study were excluded.

Patients were divided into two groups: A (Papaverine [Papaverine Sterop 40 mg/mL Amp., Laboratoires Sterop, Belgium] plus ketorolac [Ketorolac. 30 mg/mL Inj., Iran Hormone, Iran] and B [ketorolac plus placebo]. In group A, 120 mg IV papaverine with 30 mg IV ketorolac infusion in 100 mL of normal saline for 3 min for a single time, and in group B, ketorolac with a dose of 30 mg with placebo as an IV infusion in 100 mL of normal saline for 3 min for a single time were prescribed. The principal investigator prepared and coded the drug, and then the drug was given to the emergency physician for injection.

Outcomes

After enrolling patients, demographic information (age, sex, level of education, and weight), history of underlying diseases (diabetes, hypertension, heart disease, hyperlipidemia, smoking history, opium addiction, previous history of kidney stones, family history of kidney stones, kidney disease, malignancy, and need for analgesia), previous analgesic side-effects (nausea, vomiting, dizziness, hypotension, emergency reactions, and so on) were registered by an emergency physician in a data gathering form. Electrocardiography (ECG) was taken from all patients over 40 years of age. The final diagnosis of the stone was based only on CT-scan. A visual analog scale (VAS) pain scale is defined from 0 to 10 cm on the left (no pain) and on the right (extreme pain).

During the study, patients were asked to rate their pain on the VAS before administration and 20, 45, and 60 min after administration. Fentanyl (Darupakhsh, Iran) was prescribed to patients who did not experience significant pain relief (50% pain relief) after 20 min of drug administration. The dose of fentanyl was 1-2 µg/Kg. At the end of the 60 min, fentanyl was injected at 1 µg/Kg dose in all patients with any amount of pain equal to or greater than 4.

Sample Size

Sample size was calculated 140 cases for each group according to literature review¹² to

show the difference between the two groups in proportion of "pain relief at 2 hour" after treatment with ($P_1=0.95$ [ketorolac plus drotaverine] and $P_2=0.85$ [ketorolac]) with 95% confidence and 80% test power of the relationship:

$$n=(Z_{\alpha/2}+Z_{\beta})^2*(p_1(1-p_1)+p_2(1-p_2))/(p_1-p_2)^2$$

Randomization

Using block balanced randomization method, 280 patients were randomly assigned to each group. Random sequences were generated by creating a blocked randomization list from www.sealedenvelope.com in blocks of eight. Treatment allocation was masked from participants, study personnel, and outcome assessors and was concealed in sequentially numbered with sealed opaque envelopes. Patients were randomly assigned into two groups in a 1:1 ratio.

Blinding

Each patient had their code for block randomization. Only a third researcher was aware of the patient group, who was not included in the intervention and analyzed the data. Specific drugs and their dosage were injected by a physician based on each patient's code. All processes of prescribing drugs, evaluating patients, and recording data were performed by a physician who had no information about this coding. The patient did not know the type of injectable drug. The research pharmacist prepared 280 uniform and unshaped vials, of which 140 vials were papaverine and ketorolac, and the rest of 140 vial medications were ketorolac+placebo.

Statistical Analysis

Statistical analyses were performed using SPSS software version 19.0 (IBM Corp., Armonk, N.Y., USA). Student *t* test was used for analysis to compare mean values, and the Chi square test was employed to compare the categorical variables. The repeated measure ANOVA test was used to analyze variables during the study time. $P<0.05$ was considered significant.

Results

Baseline Data

Initially, 392 patients enrolled in the study, 93 of them had not inclusion criteria and 19 patients declined to participate. Finally, 280 patients were included in this study, of which 140 were equally divided in both groups (figure 1).

Both groups were homogenous in demographic data, including age, gender, baseline VAS, history of urinary tract infection, and location of the stone (table 1).

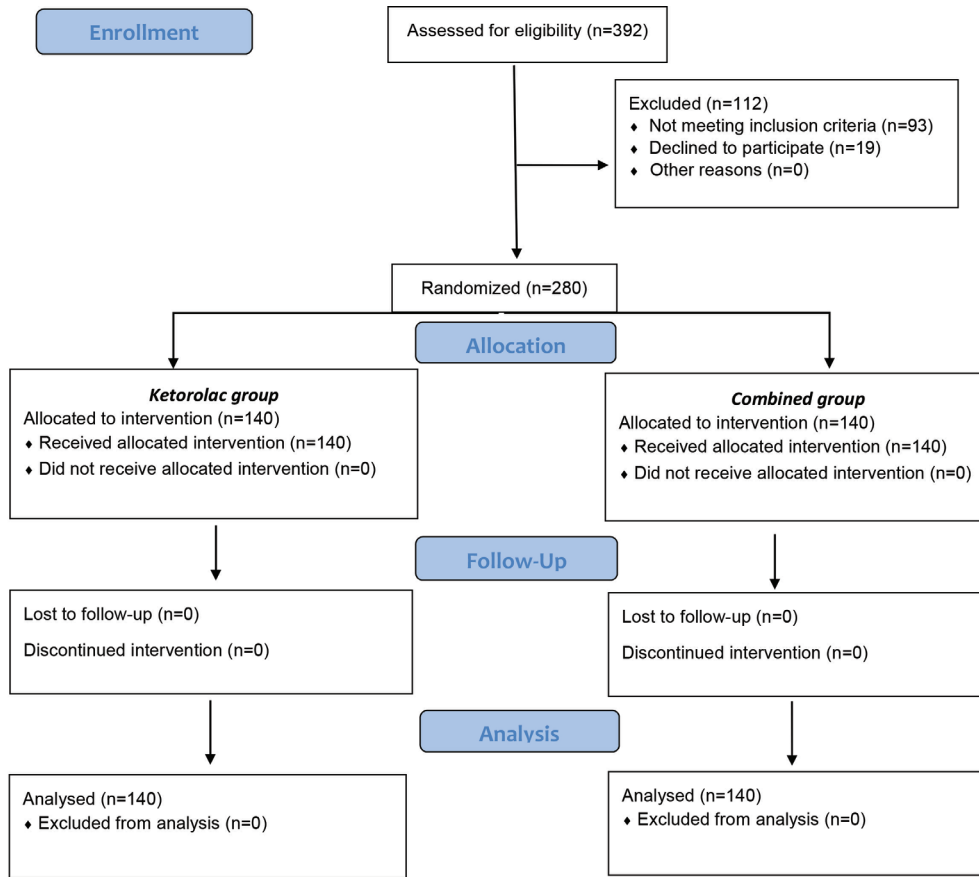


Figure 1: The CONSORT diagram demonstrates the allocation process of the participants throughout the trial.

Table 1: Demographic data of participants of papaverine plus ketorolac group and ketorolac plus placebo group

Variables		Ketorolac+papaverine (N=40)	Ketorolac+placebo (N=140)	P value
*Age year (mean±SD)		38.7±11.36	40.1±10.91	0.139
#Sex, N (%)	Female	55 (39.3)	49 (35)	0.652
	Male	85 (60.7)	91 (65)	
*Baseline VAS (mean±SD)		8.72±1.12	8.67±1.09	0.707
#History of urinary tract infection, N (%)		24 (17.14)	21 (15)	0.309
#Location of the stone, N (%)	Middle and proximal	42 (30)	46 (32.96)	0.802
	Distal	85 (60.74)	80 (57.11)	
	Renal	13 (9.23)	14 (10)	

*Student sample *t* test, #Chi square test. Significant level $P < 0.05$. VAS: visual analog scale

Moreover, 91 (65%) of the patients were male, and 49 (35%) were female. The mean age of patients was 39.4 ± 11.1 years old.

Findings

The VAS score was significantly decreased after taking the drug in two groups of ketorolac+papaverine and ketorolac+placebo and subgroups renal, middle and proximal, and distal ureteral stones ($P_{\text{time effect}} < 0.001$). The mean degree of pain based on VAS score was significantly lower in the papaverine group than the placebo group at the 45th and 60th min

in the main groups ($P = 0.001$, $P = 0.002$) and middle and proximal ureteral stones ($P < 0.001$, $P < 0.001$). However, no significant difference was observed for renal and distal ureteral stones group during study. The results were reported independently each time because interaction effect was significant in all cases (figure 2 and table 2).

The most common side-effects observed in both groups were vomiting, rash, and vertigo. However, the prevalence of side effects was not significantly different between the two groups (table 3).

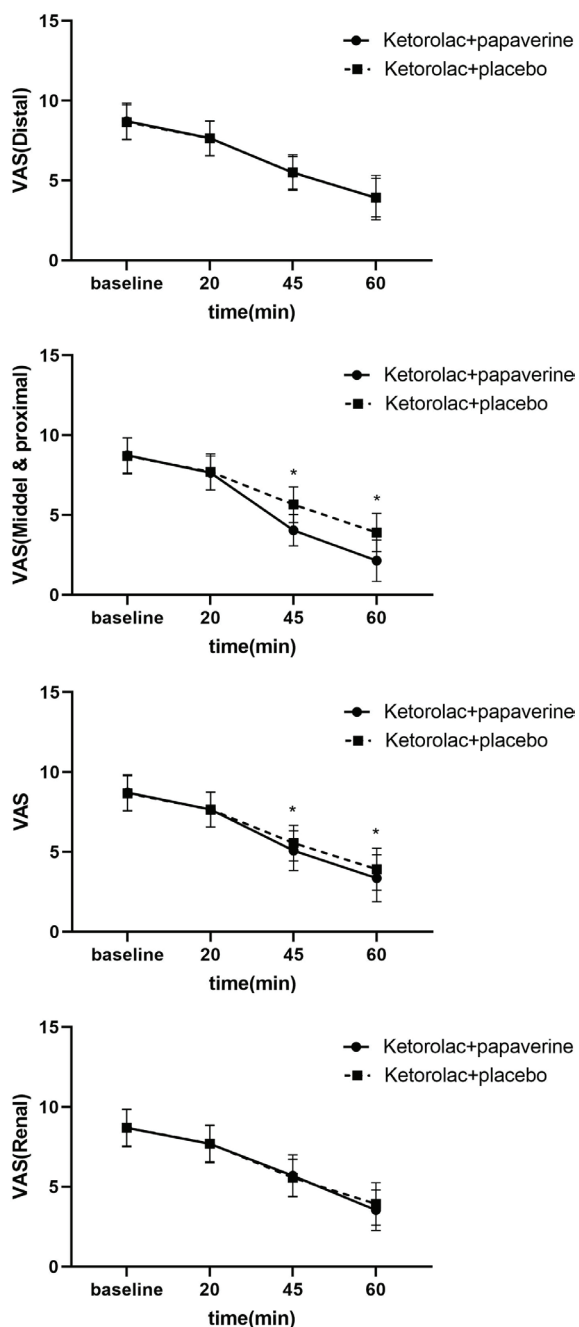


Figure 2: The Visual Analog Scale (VAS) score trend is illustrated during the study between groups of ketorolac+papaverine and ketorolac+placebo and subgroups of renal, middle, proximal and distal ureteral stones. *Shows significant difference between groups

Discussion

In this study, the mean degree of pain was significantly lower in the papaverine group than in the ketorolac group at the 45 and 60 min ($P=0.001$). However, no significant differences were observed at the beginning of the study and at the 20 min. Moreover, The VAS score was significantly decreased after taking the drug for middle and proximal ureteral stones at 45 and 60 min.

Patients who came to the emergency department for the first time due to renal colic are often agitated due to the severity of the pain and anxiety caused by it. Patients' satisfaction with the quality of treatment in the emergency department largely depends on managing their pain. In a 2012 study on the effect of adding hyoscine to ketorolac and morphine in patients with renal colic, Song and colleagues stated that the combination of morphine and hyoscine with ketorolac was more effective in reducing patients' pain.¹⁵ This reduction was statistically significant, but the reduction in the pain intensity was not clinically significant. Ketorolac is the only NSAID labeled for intramuscular and IV administration in acute pain.¹⁶ In the present study, the relationship between treatment and pain intensity in all patients was investigated and compared between the two groups. Pain parameter was reported in two groups after 20, 45, and 60 min of drug administration. As the results showed, after taking papaverine and ketorolac, the pain parameter decreased over time. These results also showed the effectiveness of ketorolac in reducing pain over time.

Dolatabadi and colleagues evaluated ketorolac with desmopressin to control pain in patients with renal colic. The pain was assessed using the VAS scale 10, 30, and 60 min after drug administration. The mean pain scores were significantly lower than the desmopressin group, 10, 30, and 60 min after drug administration in the ketorolac group, and it decreased faster.¹⁷ Moreover, Asgari and colleagues showed there were significant differences in the VAS at 0 and 20 min, and 0 and 40 min in papaverine hydrochloride plus diclofenac versus diclofenac alone for the relief of acute renal colic ($P<0.001$).¹¹

Another factor that was evaluated in our study was determining the relationship between treatment and pain intensity in patients with stones and the location of the kidney stone. The present study showed a decrease in pain parameters in both groups. These results indicated that after taking a combination of papaverine and ketorolac, the pain caused by kidney stones decreased. Ye and colleagues evaluated the efficacy of tamsulosin and nifedipine for distal ureteral stones with renal colic. They showed that tamsulosin and nifedipine were safe and effective for distal ureteral stones with renal colic.¹⁸

The present study investigated the relationship between treatment and pain intensity in patients with distal ureteral stones. Pain parameter was measured in two treatment groups after 20, 45, and 60 min. Eighty-five patients were classified in the first group, and 80 patients in the second group. In both papaverine and ketorolac groups,

Table 2: Need to rescue analgesia and Visual Analog Scale (VAS) score trend during the study between group ketorolac+ papaverine and ketorolac+placebo and subgroups renal, middle, proximal, and distal ureteral stones

Variables	Ketorolac+ papaverine (N=140)	Ketorolac+placebo (N=140)	P value
`VAS, (mean±SD)			
Baseline	8.72±1.12	8.67±1.10	0.707
20 min	7.65±7.08	7.66±1.10	0.912
45 min	5.08±1.23	5.56±1.11	0.001
60 min	3.35±1.47	3.92±1.31	0.002
`VAS (Renal), (mean±SD)			
Baseline	8.69±1.18	8.71±1.14	0.961
20 min	7.69±1.18	7.71±1.14	0.961
45 min	5.69±1.32	5.57±1.16	0.802
60 min	3.54±1.27	3.93±1.33	0.443
`VAS (Middle and proximal) (mean±SD)			
Baseline	8.74±1.11	8.70±1.11	0.858
20 min	7.64±1.05	7.70±1.11	0.820
45 min	4.05±0.99	5.65±1.12	<0.001
60 min	2.14±1.30	3.91±1.19	<0.001
`VAS (Distal) (mean±SD)			
Baseline	8.72±1.14	8.65±1.09	0.698
20 min	7.65±1.09	7.64±1.08	0.955
45 min	5.49±1.02	5.51±1.11	0.912
60 min	3.92±1.21	3.93±1.38	0.971
#Need to rescue analgesia, N(%)	7 (5)	21 (15)	0.005

*Student sample t test, #Chi square test. Significant level: P<0.05

Table 3: Side effects during the study between group ketorolac+papaverine and ketorolac+placebo

Side effects	Ketorolac+papaverine (N=140) n (%)	Ketorolac+placebo (N=140) n (%)	*P value
Rash	3 (2)	3 (2)	-
Nausea	1 (0.7)	4 (3)	0.177
Headache	1 (0.7)	1 (0.7)	-
Vertigo	4 (3)	3 (2)	0.702
Vomiting	3 (2)	3 (2)	-
Hypotension	2 (1.4)	1 (0.7)	0.562

*Fisher exact test. Significant level P<0.05

the pain parameter in patients with distal ureteral stones decreased over time, which shows the effectiveness of these drugs in reducing pain in this group of patients. This result showed that the papaverine group's analgesia was more effective, and most patients experienced pain relief after 1 hour. Similarly, Hosseininejad and colleagues evaluated the efficacy and safety of combination therapy with ketorolac and morphine in a patient with acute renal colic and concluded that pain intensity in the first group was significantly higher. They were less significant than morphine or ketorolac alone and required less rescue analgesics.¹⁹

A study by Snir and colleagues examined the efficacy of papaverine hydrochloride in combination with diclofenac sodium for the treatment of renal colic and concluded that significantly more patients in the papaverine group needed more analgesic consumption. Four patients (14.8%) reported minor side effects (confusion in three cases, drowsiness

in one case).¹² In this study, in the combined group of papaverine and ketorolac, the most common side effects were vertigo, vomiting, rash, and nausea, respectively.

Due to the high number of patients and the lack of enough beds in hospitals, there were restrictions on patient care and length of hospitalization in the emergency room, which reduced the possibility of evaluating patients and completing data gathering forms related to this study and other similar studies.

Conclusion

This study showed that the combination of ketorolac with papaverine effectively relieves acute renal colic, especially pain from middle and proximal ureteral stones. Furthermore, combination therapy with ketorolac and papaverine will reduce the use of other analgesics such as narcotics.

Acknowledgment

This article is extracted from Dr. Mohammad Reza Pirouzi's thesis to receive specialty degree for Emergency Medicine from Ahvaz Jundishapour University, Ahvaz, Iran.

Authors' Contribution

J.M.: Study design, data analysis, and drafting; A. K: Study design, critical reviewing; A.D: Study design, critical reviewing; M.P: Study design, Data acquisition, data analysis, and drafting the manuscript; N.A: Analysis and interpretation of data for the work, data analysis and drafting the manuscript. All authors have read and approved the final manuscript and agree to be accountable for all aspects of the work in ensuring that questions related to the accuracy or integrity of any part of the work are appropriately investigated and resolved.

Conflict of Interest

Naeimehossadat Asmarian, as the Editorial Board Member, was not involved in any stage of handling this manuscript. A team of independent experts was formed by the Editorial Board to review the article without her knowledge.

References

- Portis AJ, Sundaram CP. Diagnosis and initial management of kidney stones. *American family physician*. 2001;63:1329-39.
- Diri A, Diri B. Management of staghorn renal stones. *Ren Fail*. 2018;40:357-62. doi: 10.1080/0886022X.2018.1459306. PubMed PMID: 29658394; PubMed Central PMCID: PMC6014528.
- Holdgate A, Oh CM. Is there a role for anti-muscarinics in renal colic? A randomized controlled trial. *J Urol*. 2005;174:572-5. doi: 10.1097/01.ju.0000165337.37317.4c. PubMed PMID: 16006900.
- Phillips E, Hinck B, Pedro R, Makhlof A, Kriedberg C, Hendlin K, et al. Celecoxib in the management of acute renal colic: a randomized controlled clinical trial. *Urology*. 2009;74:994-9. doi: 10.1016/j.urol.2009.04.063. PubMed PMID: 19589565.
- Dellabella M, Milanese G, Muzzonigro G. Randomized trial of the efficacy of tamsulosin, nifedipine and phloroglucinol in medical expulsive therapy for distal ureteral calculi. *J Urol*. 2005;174:167-72. doi: 10.1097/01.ju.0000161600.54732.86. PubMed PMID: 15947613.
- Onen A. Grading of Hydronephrosis: An Ongoing Challenge. *Front Pediatr*. 2020;8:458. doi: 10.3389/fped.2020.00458. PubMed PMID: 32984198; PubMed Central PMCID: PMC7481370.
- Yamashita S, Kohjimoto Y, Iguchi T, Nishizawa S, Kikkawa K, Hara I. Ureteral wall volume at ureteral stone site is a critical predictor for shock wave lithotripsy outcomes: comparison with ureteral wall thickness and area. *Urolithiasis*. 2020;48:361-8. doi: 10.1007/s00240-019-01154-w. PubMed PMID: 31444520.
- He M, Lin X, Lei M, Xu X, He Z. Risk Factors of Urinary Tract Infection After Ureteral Stenting in Patients with Renal Colic During Pregnancy. *J Endourol*. 2021;35:91-6. doi: 10.1089/end.2020.0618. PubMed PMID: 32680438.
- Eidinejad L, Bahreini M, Ahmadi A, Yazdchi M, Thiruganasambandamoorthy V, Mirfazaelian H. Comparison of intravenous ketorolac at three doses for treating renal colic in the emergency department: A noninferiority randomized controlled trial. *Acad Emerg Med*. 2021;28:768-75. doi: 10.1111/acem.14202. PubMed PMID: 33370510.
- Afshar K, Jafari S, Marks AJ, Eftekhari A, MacNeily AE. Nonsteroidal anti-inflammatory drugs (NSAIDs) and non-opioids for acute renal colic. *Cochrane Database Syst Rev*. 2015;2015:CD006027. doi: 10.1002/14651858.CD006027.pub2. PubMed PMID: 26120804; PubMed Central PMCID: PMC6010981792.
- Asgari SA, Asli MM, Madani AH, Maghsoudi PA, Ghanaei MM, Shakiba M, et al. Treatment of loin pain suspected to be renal colic with papaverine hydrochloride: a prospective double-blind randomised study. *BJU Int*. 2012;110:449-52. doi: 10.1111/j.1464-410X.2011.10793.x. PubMed PMID: 22348304.
- Snir N, Moskovitz B, Nativ O, Margel D, Sandovski U, Sulkes J, et al. Papaverine hydrochloride for the treatment of renal colic: an old drug revisited. A prospective, randomized study. *J Urol*. 2008;179:1411-4. doi: 10.1016/j.juro.2007.11.053. PubMed PMID: 18289563.
- Davenport K, Timoney AG, Keeley FX. Conventional and alternative methods for providing analgesia in renal colic. *BJU Int*. 2005;95:297-300. doi: 10.1111/j.1464-410X.2005.05286.x. PubMed PMID: 15679781.
- Umezawa S, Higurashi T, Uchiyama S, Sakai E, Ohkubo H, Endo H, et al. Visual

- distraction alone for the improvement of colonoscopy-related pain and satisfaction. *World J Gastroenterol*. 2015;21:4707-14. doi: 10.3748/wjg.v21.i15.4707. PubMed PMID: 25914482; PubMed Central PMCID: PMC4402320.
- 15 Song SW, Kim K, Rhee JE, Lee JH, Seo GJ, Park HM. Butylscopolammonium bromide does not provide additional analgesia when combined with morphine and ketorolac for acute renal colic. *Emerg Med Australas*. 2012;24:144-50. doi: 10.1111/j.1742-6723.2011.01502.x. PubMed PMID: 22487663.
 - 16 Bucci FA, Jr., Michalek B, Fluet AT. Comparison of the frequency of use of a pupil expansion device with and without an intracameral phenylephrine and ketorolac injection 1%/0.3% at the time of routine cataract surgery. *Clin Ophthalmol*. 2017;11:1039-43. doi: 10.2147/OPHTH.S132552. PubMed PMID: 28615924; PubMed Central PMCID: PMC45460648.
 - 17 Arhami Dolatabadi A, Memary E, Kariman H, Nasiri Gigloo K, Baratloo A. Intranasal Desmopressin Compared with Intravenous Ketorolac for Pain Management of Patients with Renal Colic Referring to the Emergency Department: A Randomized Clinical Trial. *Anesth Pain Med*. 2017;7:e43595. doi: 10.5812/aapm.43595. PubMed PMID: 28824859; PubMed Central PMCID: PMC45556593.
 - 18 Ye Z, Yang H, Li H, Zhang X, Deng Y, Zeng G, et al. A multicentre, prospective, randomized trial: comparative efficacy of tamsulosin and nifedipine in medical expulsive therapy for distal ureteric stones with renal colic. *BJU Int*. 2011;108:276-9. doi: 10.1111/j.1464-410X.2010.09801.x. PubMed PMID: 21083640.
 - 19 Hosseininejad SM, Amini Ahidashti H, Bozorgi F, Goli Khatir I, Montazar SH, Jahanian F, et al. Efficacy and Safety of Combination Therapy with Ketorolac and Morphine in Patient with Acute Renal Colic; A Triple-Blind Randomized Controlled Clinical Trial. *Bull Emerg Trauma*. 2017;5:165-70. PubMed PMID: 28795060; PubMed Central PMCID: PMC45547203.