

The Labial Adhesion in Postmenopausal Women: A Systematic Review

Nastaran Mahmoudnejad¹, MD;^{ORCID}
Mohammad Hamidi Madani¹, MD;
Roohbeh Roohinezhad², MD^{ORCID}

¹Urology and Nephrology Research Center, Department of Urology, Shahid Labbafinejad Hospital, Shahid Beheshti University of Medical Sciences, Tehran, Iran;

²Department of Urology, Hasheminejad Kidney Center, Iran University of Medical Sciences, Tehran, Iran

Correspondence:

Roohbeh Roohinezhad, MD;
Shahid Hashminejad Hospital Shahid Valinejad Alley, Above Vanak Square, Vali Asr (AJ) St., Postal code: 1969714713, Tehran, Iran

Tel: +98 21 77278811

Email: roohinezhad@gmail.com

Received: 06 January 2024

Revised: 04 April 2024

Accepted: 08 May 2024

What's Known

- Labial adhesion is a disorder identified by partial or total fusion of the labia minor. In severe forms of postmenopausal labial fusion, the labia minor adheres to each other at the midline and leaves no opening at the level of the introitus. This condition may cause pseudo-incontinence in women.

What's New

- For postmenopausal women with labial fusion, surgical release of labial adhesion can be considered a safe and effective therapeutic option with a negligible medium-term recurrence rate.

Abstract

Background: Labial adhesion (LA) is a total or partial labial fusion mostly seen in pre-pubertal children and is rare in premenopausal and postmenopausal periods. This review aimed to evaluate risk factors for labial fusion and the recurrence rate following surgical intervention in postmenopausal women.

Methods: According to PRISMA guidelines, international databases including Embase, World Cat, Web of Science, Scopus, Dimension, Open Grey, Cochrane, Google Scholar, and also PubMed gateway for PMC and MEDLINE were searched. The included studies were in English and published from 1985 until December 2023 with the keywords including vulvar diseases, agglutination, menopause, postmenopause, and recurrence. All studies that evaluated the clinical course and recurrence of LAs following surgical treatment in postmenopausal women were included. The inclusion criteria were the risk factors of LA recurrence rate, and the exclusion criteria were studies with missing required data, letters to editors, and conference studies.

Results: Thirty-four case reports were enrolled. In total, 54 patients were evaluated. The most common risk factors for LA included hypoestrogenism, virginity, sexual inactivity, cervical cancer, hysterectomy, urinary tract infections, and lichen sclerosis. Only one study reported a recurrence of labial fusion following surgical intervention in a one-year follow-up.

Conclusion: The most common risk factors for LA were hypoestrogenism, virginity, sexual inactivity, cervical cancer, hysterectomy, urinary tract infections, and lichen sclerosis. The low recurrence rate following surgical release of labial fusion has made it an effective and safe method in postmenopausal women with negligible medium-term recurrence rates.

Please cite this article as: Mahmoudnejad N, Hamidi Madani M, Roohinezhad R. The Labial Adhesion in Postmenopausal Women: A Systematic Review. Iran J Med Sci. doi: 10.30476/ijms.2024.101283.3395.

Keywords • Vulvar diseases • Agglutination • Menopause • Postmenopause • Recurrence

Introduction

Labial adhesion (LA) is a disorder characterized by complete or incomplete fusion of the labia minor. It is also known as vulvar synechia or labial agglutination.¹ This condition primarily affects pre-pubertal girls and is extremely rare in postmenopausal women.^{1,2} The primary etiology of labial fusion is still unknown. However, there is a shred of evidence that low estrogen levels and sexual inactivity might play a role.^{3,4} LA might occur due to congenital anomalies or acquired conditions, and it is most usually caused by a combination of estrogen deficiency and

chronic inflammation.^{4, 5} Other complicating risk factors include eczema, seborrhea dermatitis, sclerosis, local trauma, urinary tract infections (UTI), and senile vaginitis.⁶ In severe forms of postmenopausal labial fusion, the labia minor adheres to each other at the midline and leaves no opening at the level of the introitus. This condition may cause pseudo-incontinence in women.⁷ LA is simply managed by topical steroids in the pre-pubertal stage. However, in postmenopausal women, this approach might not be effective.¹ In these patients, fused labia can be separated manually or by surgical intervention.⁸ Previous studies demonstrated that separation of fused labia minor through surgery would be effective in postmenopausal women. However, the labial fusion recurrence rate following surgery remained undetermined.^{3, 5, 9-11} To our knowledge, this study is the first systematic review of postmenopausal LA. The present study aimed to review the available literature and identify the risk factors for labial fusion and recurrence rate following surgical intervention in postmenopausal women.

Materials and Methods

Study Design

This systematic review assessed the risk factors and recurrence rate for labial fusion following surgical management in postmenopausal women. The preferred reporting item for systematic reviews and meta-analyses, a PRISMA checklist, was utilized.¹² The primary inquiries of the research were:

- Which risk factors were the most prevalent?
- How much was the recurrence rate of LA following the surgical technique?
- How much this method could be safe and effective for postmenopausal women?

Search Strategy

The electronic search for relevant studies was conducted using online databases, such as Embase, World Cat, Web of Science, Scopus, Dimension, Open Grey, Cochrane, Google Scholar, and PubMed (PMC and MEDLINE). There were no restrictions regarding the place and date of publication, and the literature search strategy was upgraded up to July 2023. The studies that were not published in the English language were excluded. Labial fusion, labial adhesion, labial synechia, labial agglutination, vulvar synechia, vulvar adhesion, vulvar fusion, vulvar synechia, menopause, postmenopausal, labial separation, and recurrence were used as

Medical Subject Headings (MeSH) keywords.

The following is the search strategy used in PubMed: (Labial adhesion[Title/Abstract]) OR (Labial fusion[Title/Abstract]) OR (Labial synechia[Title/Abstract]) OR (Labial agglutination[Title/Abstract]) OR (Vulvar synechia[Title/Abstract]) OR (Vulvar adhesion[Title/Abstract]) OR (Vulvar fusion[Title/Abstract]) OR (Vulvar synechia[Title/Abstract]) AND (Menopause[Title/Abstract]) OR (Postmenopausal[Title/Abstract]) AND (Labial separation[Title/Abstract]) OR (Labial surgery[Title/Abstract]) AND (Recurrence[Title/Abstract]).

Inclusion Criteria

All types of studies that evaluated risk factors for LA recurrence rate following surgical technique in postmenopausal women were included in this review study.

Exclusion Criteria

The exclusion criteria included systematic reviews, meta-analyses, duplicate studies, studies with missing required data, no full-text access, letters to editors, and conference papers. In addition, studies that assessed the child and non-postmenopausal women with labial agglutination, medical treatment in the management of LA, and studies that did not report labial fusion recurrence rate following surgery were excluded.

Outcome Measures

The primary outcome was the incidence of LA recurrence in postmenopausal women.

Quality Assessment

All included studies in this systematic review were case reports. Thus, no quality assessment was conducted.

Risk of Bias Assessment

None of the reviewed studies were randomized controlled trials. There were few studies in the field of the study subject. Furthermore, the studies' risk bias was assessed using the 13 items in the Research Triangle Institute (RTI), Evidence-based Practice Center, and Cochrane Collaboration's risk bias assessment tool.

Data Extraction

Two reviewers independently extracted the required data using a checklist, which included the authors' names, publication year, sample size, age, related factors, frequency of LA recurrence, symptoms, and examination findings before surgery.

Results

Our initial search yielded 1026 papers in all databases. Due to duplicate studies, 431 records were removed. After screening the titles and abstracts, 221 were eligible for inclusion. Following an eligibility assessment, 34 studies in the English language from 1985 until 2023 were included in the final analysis (figure 1).

The results showed that 34 studies assessed the recurrence rate of labial fusion after surgical intervention in postmenopausal women. All studies were case reports, and most studies reported only one case. The largest sample size belonged to a study conducted by Mikos and colleagues, with seven cases.⁷ The oldest and youngest patients were 92 and 51 years old, respectively. The oldest study was conducted in 1985, and the most recent study was published in 2023. The follow-up period for labial fusion recurrence ranged from 2 weeks to 36 months (table 1).

The clinical findings of studied patients demonstrated that the most prevalent symptoms for LA diagnosis included vulvar pain, dysuria, urinary

incontinence, urinary retention, UTI, abdominal pain, and difficulty voiding. The surgical technique methods used for labial separation included blunt, sharp, and manual release. The most commonly reported etiology for LA were hypoestrogenism, virginity, infrequent sexual inactivity, cervical cancer, hysterectomy, recurrent UTI, and lichen sclerosis. Only one study reported LA recurrence following surgical treatment (table 1).

Discussion

LA primarily affects pre-pubertal girls, although there are some documented cases in postmenopausal women. The prevalence of this condition among the elderly is still unknown. In infancy, LA often results from local inflammation and diaper irritation. However, it can also be associated with conditions such as adrenogenital syndrome and adrenocortical hyperplasia. Additionally, it has been observed in postmenopausal women. LA is caused by various factors, including hypoestrogenism, poor hygiene, eczema, and local trauma.^{13, 38}

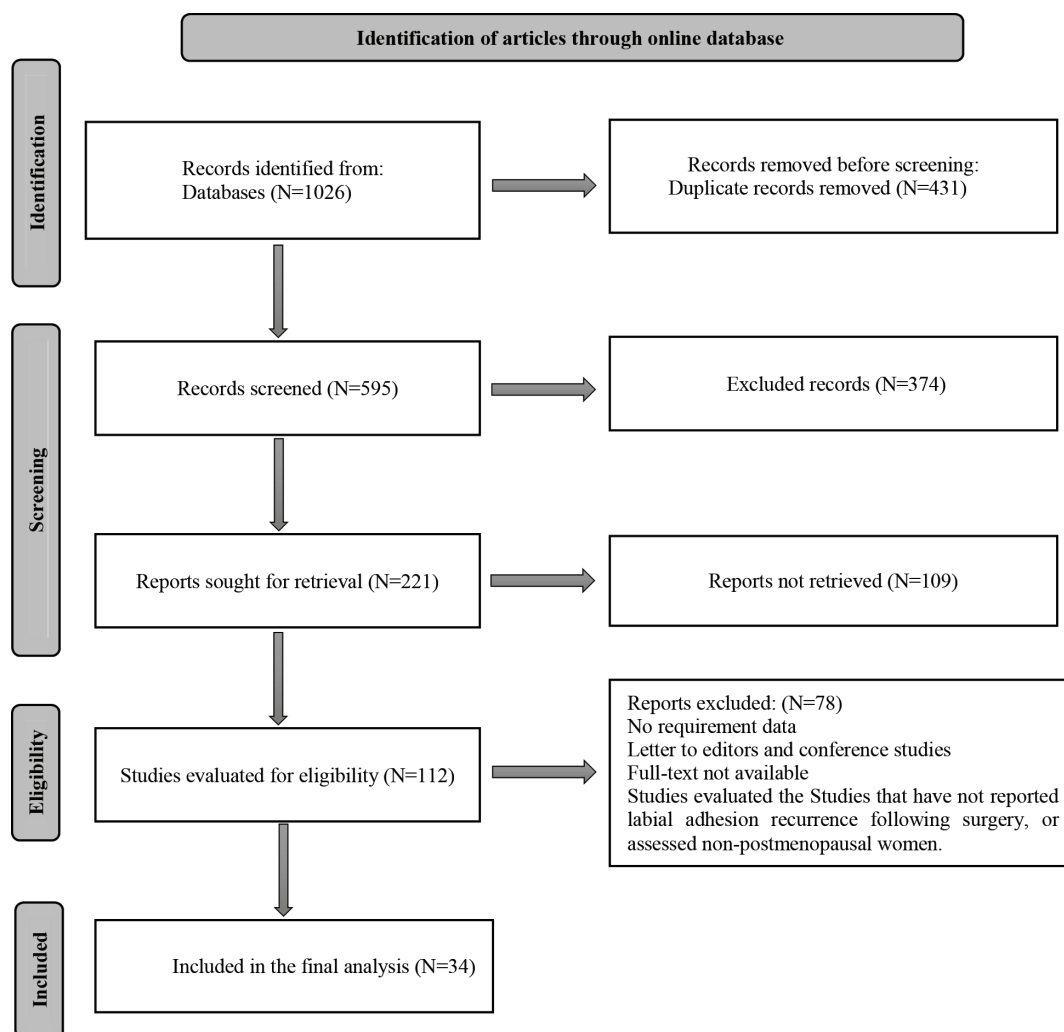


Figure 1: The four-phase PRISMA flow diagram used for reviewing the studies.

Table 1: The summary of data from included articles related to labial adhesion in postmenopausal women

Author	Publication year	Number of cases	Age (y)	Symptoms	Diagnosis by physical examination	Etiology	Treatment	The follow-up's outcome
Savona-Ventura ¹³	1985	2	78 and 82	One had vulvar pain and difficulty with urinating, the other had urinary incontinence.	Labial adhesion	One unmarried and one sexually inactive for years- both had severe osteoarthritis of the hip joint.	Surgical separation	No recurrence
Imamura and colleagues ¹⁴	1998	1	68	Dysuria and urinary incontinence	Extensive labial fusion	NA	Surgical separation	No recurrence at routine therapy follow-up
Saito and colleagues ¹⁵	1998	2	78 and 77	Case 1: Difficulty in urination and vulvitis Case 2: Urinary retention	Extensive labial fusion	Sexually inactive	Surgical separation	No recurrence at 18 and 36-month follow-up
Ong and colleagues ¹⁶	1999	1	88	Difficult voiding and post-micturition dribbling	Labial fusion	Sexually inactive	Surgical separation	At the 2-month follow-up, she had some fusion that was manually separated.
Yano and colleagues ¹⁷	2002	1	66	Dysuria and perineal irritation	Severe labial fusion	NA	Surgical intervention using Y-V advancement flaps	No recurrence at 1-year-follow-up
Hatada ¹⁸	2003	1	71	Vulvar pain and abnormal urinary flow	Extensive labial fusion	Sexually inactive for years	Surgical separation	No recurrence at 8-month follow-up
Julia and colleagues ¹⁹	2003	1	72	Post-micturition dribbling and incontinence	Labial fusion	Sexually inactive for years	Surgical separation by sharp dissection	No symptoms at 2-week follow-up
Migita and colleagues ²⁰	2005	2	83 and 63	Difficulty urination	Near-total labial adhesions	NA	Surgical separation	No recurrence at 12 and 11 months follow-up, respectively
Pulvino and colleagues ²¹	2008	5	Mean age:78	Urinary incontinence	Near-total occlusion in 4 patients and partial occlusion in 1 patient	NA	Surgical intervention	Improvement in symptoms at 2 and 6 weeks-follow-up
Dirim and colleagues ²²	2011	1	73	Recurrent UTI and urinary incontinence	Fused labium majora	Sexually inactive for years	Surgical separation	No symptoms at 2-weeks follow-up
Fakheri and colleagues ²³	2011	1	74	Urinary retention	Total fusion of labia	Sexually inactive for years	Surgical separation	No symptoms at 3-month follow-up
Chang and colleagues ²⁴	2012	1	63	Emptying symptoms	Delayed labial agglutination	NA	Blunt dissection surgery	No recurrence at 3-month follow-up

Author	Publication year	Number of cases	Age (y)	Symptoms	Diagnosis by physical examination	Etiology	Treatment	The follow-up's outcome
Lazarou and colleagues ²⁵	2013	1	51	Incomplete voiding	Complete adhesion of the labia minors	NA	Surgical separation	No symptoms at 3-month follow-up
James and colleagues ²⁶	2014	1	79	A small leakage from the introitus during urination and poor urinary control	Severe labial agglutination	Sexually inactive	Surgical treatment	No symptoms at follow-up
Kaplan and colleagues ²⁷	2014	2	78 and 65	Case 1: Urinary incontinence and voiding difficulty. Case 2: Voiding difficulty, poor urinary flow, and incomplete bladder emptying	Complete labial fusion	One had a history of Hodgkin's lymphoma, hysterectomy, cervical cancer, and melanoma, and the other had a hysterectomy and lichen sclerosis	Surgical treatment	No recurrence at 1-year follow-up
Başaranoğlu and colleagues ²⁸	2016	1	92	Acute renal failure	Complete labial fusion	Biopsy demonstrated lichen sclerosis	Labial separation	No recurrence at 3-month follow-up
Lu and colleagues ²⁹	2018	1	83	Urinary incontinence	Labial agglutination	NA	Surgical treatment	No recurrence at 3-month follow-up
Kumagai and colleagues ³⁰	2018	1	76	An elevated accumulation was seen in the vagina on a positron emission tomography scan	Extensive labial fusion	Undergoing chemoradiation due to esophageal cancer	Surgical treatment	No recurrence at 3-month follow-up
Wyman and colleagues ²	2018	2	90 and 71	One had urinary incontinence, and the other had urinary leakage and voiding dysfunction	Complete labial fusion	One had lichen sclerosis	Surgical treatment	No recurrence at 12 and 18-month follow-up
Takimoto and colleagues ³¹	2019	1	86	Dysuria and perineal pain	Extensive fusion, erythema, and warmth of both labial majora	Hysterectomy. Lack of intercourse for a long time.	The fusion was manually separated, and vulva-perineal flaps were used for the reconstruction.	No recurrence at 18-month follow-up
Mikos and colleagues ⁷	2019	7	mean age= 72.9±12.1	Pseudo-incontinence	Complete labial fusion	All patients were sexually inactive.	Manual or surgical labial separation	No recurrence at a mean 2.4-year follow-up

Author	Publication year	Number of cases	Age (y)	Symptoms	Diagnosis by physical examination	Etiology	Treatment	The follow-up's outcome
Kukreja and colleagues ³²	2019	1	60	Difficulty urinating and poor urinary stream	Labial fusion	Hysterectomy-lichen sclerosis	Surgical separation	The case is on regular follow-up.
Singh and colleagues ⁶	2019	6	mean age=76	Urinary and vulvar complaints	Complete labial fusion	One had lichen Sclerosis	4 needed adhesion release	No symptoms at 1-month follow-up
Takamaru and colleagues ⁵	2019	1	91	Recurrent UTI	Labial fusion	History of two labial-adhesion separations	Surgical labial separation	No recurrence at 6-month follow-up
Laih and colleagues ³³	2020	1	76	Voiding difficulty, dribbling, and urinary leakage	Labial fusion	Sexually inactive	Surgical separation	No recurrence at 6-month follow-up
Saberi and colleagues ⁴	2020	1	62	Voiding dysfunction, and recurrent UTI	Diffuse labial adhesion	Virgin	Labial Separation	No recurrence at 3-month follow-up
Tanvir and colleagues ³⁴	2020	1	68	Pseudo-urinary incontinence	Complete labial Fusion	Sexually inactive	Surgery	No recurrence at 3-year follow-up
Murugesan and colleagues ³⁵	2020	1	65	Dribbling and abdominal pain	Adhesion of the labia minora	NA	Surgery	No recurrence at 3-month follow-up
Williams and colleagues ⁹	2021	1	58	Overactive bladder	Severe labial agglutination	NA	Manual separation	Recurrence at 1-year follow-up
Gungor Ugurlucan and colleagues ³⁶	2021	1	75	Urinary retention	Complete labial fusion	Sexually inactive	The labia were separated using blunt dissection.	No recurrence at 6-month follow-up
Maeda and colleagues ¹	2021	1	82	UTI	Extensive adhesion of labia majora	NA	Surgery (Z-plasty on the ventral side and Y-V-plasty on the anal side)	No recurrence at 8-month follow-up
Kotoku and colleagues ¹¹	2022	1	83	Urinary incontinence	Complete labial adhesions	Long time sexually inactive	Surgical separation	No recurrence at 22-month follow-up
Kwon and colleagues ¹⁰	2022	1	83	Bacteriuria, dysuria, and urinary disorders	Nearly-complete labial fusion	Recurrence UTI	Surgical blunt separation	No recurrence at 1-month follow-up
Bi Y and colleagues ³⁷	2023	1	52	Labored urination	Complete labial fusion	No	Separation surgery	No recurrence at 3-month follow-up

Some studies reported that vulvar dystrophies might be a potential risk factor.¹³ In terms of other LA etiology, previous studies demonstrated that virginity and sexual inactivity,^{4, 13, 16, 18, 23} cervical cancer and hysterectomy,^{27,31,32} recurrent UTI,^{4, 10} and lichen sclerosis,^{2, 27, 28, 32} were the most common risk factors.

LA could be without symptoms or exhibit non-specific vaginal manifestations such as pruritus and vulvodynia. On rare occasions, it might display symptoms related to urination.⁴ During the early stages, fusion could be observable in the posterior region of the labia. Nevertheless, in severe and prolonged cases, complete

coverage of the vaginal and urethral openings by fusion can occur. Failure of urine to be expelled freely through the vagina might result in urinary retention and recurring UTIs.^{13, 39, 40} The most prevalent LA symptoms were vulvar pain,^{13, 18, 20} dysuria,^{2, 14, 17} urinary incontinence,^{21, 27, 29} urinary retention,²³ recurrent UTI,^{5, 22} abdominal pain,³⁵ bacteriuria,¹⁰ incomplete voiding,^{2, 25, 27} and labored urination.³⁷

In children, separation of the labia occurs spontaneously and can be accelerated by the topical application of estrogen. However, in adult women, surgical treatment is almost always necessary in symptomatic and severe cases.⁴ In the present systematic review, 54 consecutive patients with 1 to 48 months of follow-up were assessed. Only one study with one case, reported LA recurrence following surgical treatment.²¹ Hence, the recurrence rate was calculated to be 1.85%; which indicated the LA recurrence rate following surgical treatment was very rare.⁹ However, it should be considered that in the majority of the studies, the follow-up period was less than 12 months. The aforementioned patient, a 58-year-old woman with severe labial agglutination, underwent manual separation and had a recurrence of labial fusion one year later. It seems that manual separation alone, with no sutures at the edges of released labia minora, might be considered a cause of recurrence. However, more studies with long-term follow-up time are required to evaluate the exact prevalence of recurrence rate after surgical management of LA.

Two major limitations of the present research were the lack of comprehensive access to certain studies and the uneven dissemination of information across various locations. In addition, due to the nature of the study, all reviewed studies were case reports, which posed a major limitation for this systematic review.

Conclusion

The findings revealed that the most common risk factors for LA were hypoestrogenism, virginity, sexual inactivity, cervical cancer, hysterectomy, urinary tract infections, and lichen sclerosis, and the recurrence rate was very low. The low recurrence rate following surgical release of labial fusion made it an effective and safe method in postmenopausal women, with a negligible medium-term recurrence rate. However, future studies should include additional field evaluation in larger sample sizes, such as clinical trials.

Acknowledgement

The authors would like to thank everyone who

assisted us in preparing this systematic review.

Authors' Contribution

N.M: Study concept, study design, and review of the manuscript; M. HM: Study concept, study design, and drafting of the manuscript; R. R: Acquisition and interpretation of the data and review of the manuscript. All authors approved the submission of the manuscript and agree to be accountable for all aspects of the work in ensuring that questions related to the accuracy or integrity of any part of the work are appropriately investigated and resolved.

Conflict of Interest: None declared.

References

- 1 Maeda T, Deguchi M, Amano T, Tsuji S, Kasahara K, Murakami T. A novel surgical treatment for labial adhesion - The combination of Z- and Y-V-plasty: A case report. *Case Rep Womens Health*. 2021;32:e00363. doi: 10.1016/j.crwh.2021.e00363. PubMed PMID: 34754757; PubMed Central PMCID: PMC68556753.
- 2 Wyman AM, Lafranchise E, Lynch C. External Use of an Oxidized Regenerated Cellulose Agent in the Treatment of Labial Agglutination in Postmenopausal Women. *Obstet Gynecol*. 2018;132:1238-40. doi: 10.1097/AOG.0000000000002919. PubMed PMID: 30303908.
- 3 Gonzalez D, Anand S, Mendez MD. Labial Adhesions. *StatPearls*. Treasure Island (FL): StatPearls Publishing; 2023.
- 4 Saberi N, Gholipour F. Extensive Labial Adhesion Causing Voiding Urinary Symptoms in a Postmenopausal Woman: A Case Report. *Iran J Med Sci*. 2020;45:73-5. doi: 10.30476/ijms.2019.81954. PubMed PMID: 32038062; PubMed Central PMCID: PMC6983273.
- 5 Takemaru M, Aramaki-Hattori N, Tsue C, Kishi K. Labial Adhesions Causing Recurrent Urinary-Tract Infections in an Elderly Woman. *Case Rep Med*. 2019;2019:7584983. doi: 10.1155/2019/7584983. PubMed PMID: 31929804; PubMed Central PMCID: PMC6942760.
- 6 Singh P, Han HC. Labial adhesions in postmenopausal women: presentation and management. *Int Urogynecol J*. 2019;30:1429-32. doi: 10.1007/s00192-018-3821-1. PubMed PMID: 30488271.
- 7 Mikos T, Lioupis M, Grimbizis GF. Postmenopausal complete labial fusion and

- pseudo-incontinence: A case series. *Case Rep Womens Health.* 2019;21:e00101. doi: 10.1016/j.crwh.2019.e00101. PubMed PMID: 30906695; PubMed Central PMCID: PMC6411508.
- 8 Mohapatra I, Samantaray SR. Labial Fusion Recurrence in a Prepubertal Girl: A Case Report and Review of Literature. *Cureus.* 2022;14:e26059. doi: 10.7759/cureus.26059. PubMed PMID: 35865425; PubMed Central PMCID: PMC9289966.
 - 9 Williams C, Robinson J, Leggio S. Potential effects of postmenopausal labial agglutination on the urinary system. *Urol Case Rep.* 2021;36:101565. doi: 10.1016/j.eucr.2021.101565. PubMed PMID: 33489771; PubMed Central PMCID: PMC97807131.
 - 10 Kwon H. Nearly-complete labial adhesions diagnosed with repetitive cystitis in postmenopausal women: A case report. *World J Clin Cases.* 2022;10:12990-5. doi: 10.12998/wjcc.v10.i35.12990. PubMed PMID: 36569009; PubMed Central PMCID: PMC9782939.
 - 11 Kotoku R, Orita Y. Complete labial fusion with urinary incontinence in a postmenopausal woman: A case report. *Case Rep Womens Health.* 2022;36:e00465. doi: 10.1016/j.crwh.2022.e00465. PubMed PMID: 36406176; PubMed Central PMCID: PMC9667198.
 - 12 Moher D, Liberati A, Tetzlaff J, Altman DG, Group P. Preferred reporting items for systematic reviews and meta-analyses: the PRISMA statement. *BMJ.* 2009;339:b2535. doi: 10.1136/bmj.b2535. PubMed PMID: 19622551; PubMed Central PMCID: PMC2714657.
 - 13 Savona-Ventura C. Labial adhesions in postmenopausal women with hip joint disease. *Aust N Z J Obstet Gynaecol.* 1985;25:303-4. doi: 10.1111/j.1479-828x.1985.tb00752.x. PubMed PMID: 3869456.
 - 14 Imamura R, Fujimoto M, Meguro N, Maeda O, Saiki S, Kinouchi T, et al. [Labial adhesion presenting as urinary incontinence and dysuria in a postmenopausal woman: a case report]. *Hinyokika Kyo.* 1998;44:843-5. PubMed PMID: 9893235.
 - 15 Saito M, Ishida G, Watanabe N, Abe B. Micturitional disturbances due to labial adhesion. *Urol Int.* 1998;61:50-1. doi: 10.1159/000030286. PubMed PMID: 9792985.
 - 16 Ong NC, Dwyer PL. Labial fusion causing voiding difficulty and urinary incontinence. *Aust N Z J Obstet Gynaecol.* 1999;39:391-3. doi: 10.1111/j.1479-828x.1999.tb03429.x. PubMed PMID: 10554966.
 - 17 Yano K, Hosokawa K, Takagi S, Nakai K, Kubo T. Y-V advancement flaps for labial adhesions in postmenopausal women. *Plast Reconstr Surg.* 2002;109:2614-5. doi: 10.1097/00006534-200206000-00097. PubMed PMID: 12045624.
 - 18 Hatada Y. Two-step surgical approach to labial adhesions in a postmenopausal woman. *Acta Obstet Gynecol Scand.* 2003;82:1054-5. doi: 10.1034/j.1600-0412.2003.00028.x. PubMed PMID: 14616281.
 - 19 Julia J, Yacoub M, Levy G. Labial fusion causing urinary incontinence in a postmenopausal female: a case report. *Int Urogynecol J Pelvic Floor Dysfunct.* 2003;14:360-1. doi: 10.1007/s00192-003-1067-y. PubMed PMID: 14618318.
 - 20 Migita A, Miyamoto J. Labial Adhesion in Postmenopausal Women: A Report of Two Cases. *Nishinohon Journal of Urology.* 2005;67:728.
 - 21 Pulvino JQ, Flynn MK, Buchsbaum GM. Urinary incontinence secondary to severe labial agglutination. *Int Urogynecol J Pelvic Floor Dysfunct.* 2008;19:253-6. doi: 10.1007/s00192-007-0415-8. PubMed PMID: 17594045.
 - 22 Dirim A, Hasirci E. Labial fusion causing urinary incontinence and recurrent urinary tract infection in a postmenopausal female: a case report. *Int Urogynecol J.* 2011;22:119-20. doi: 10.1007/s00192-010-1205-2. PubMed PMID: 20571766.
 - 23 Fakheri T, Saeidiborojeni H, Jalilian N. Urinary Retention Due to Labial Fusion: Bloodless Correction. A Case Report. *The Professional Medical Journal.* 2011;18:328-30. doi: 10.29309/TPMJ/2011.18.02.2104.
 - 24 Chang CH, Fan YH, Tong-Long Lin A, Chen KK. Bladder outlet obstruction due to labial agglutination. *J Chin Med Assoc.* 2012;75:40-2. doi: 10.1016/j.jcma.2011.10.006. PubMed PMID: 22240536.
 - 25 Lazarou G, Maldonado MQ, Mitchell K. Complete labial fusion with vaginal constriction band presenting as incomplete voiding. *Female Pelvic Med Reconstr Surg.* 2013;19:181-3. doi: 10.1097/SPV.0b013e3182817c00. PubMed PMID: 23611939.
 - 26 James R, Sammarco A, Sheyn D, Mahajan S. Severe labial agglutination release in a postmenopausal woman. *Open Journal of Obstetrics and Gynecology.* 2014;4:822. doi: 10.4236/ojog.2014.414114.
 - 27 Kaplan F, Alvarez J, Dwyer P. Nonsurgical separation of complete labial fusion using a

- Hegar dilator in postmenopausal women. *Int Urogynecol J.* 2015;26:297-8. doi: 10.1007/s00192-014-2535-2. PubMed PMID: 25369765.
- 28 Basaranoglu S, Dogan F, Deregozu A. Acute renal failure due to complete labial fusion: A case report. *Int J Surg Case Rep.* 2016;29:162-4. doi: 10.1016/j.ijscr.2016.08.016. PubMed PMID: 27865142; PubMed Central PMCID: PMC5120264.
- 29 Lu BJ, Chin HY, Chu CY, Wang JTJ. Postmenopausal labial agglutination mimics urinary incontinence and hidden vaginal lesion. *J Obstet Gynaecol Res.* 2018;44:801-5. doi: 10.1111/jog.13556. PubMed PMID: 29297962.
- 30 Kumagai Y, Toyoshima M, Kudo K, Ohsawa M, Niikura H, Yaegashi N. Endoscopic examination of labial fusion in a postmenopausal woman: a case report. *J Med Case Rep.* 2018;12:26. doi: 10.1186/s13256-018-1568-4. PubMed PMID: 29391072; PubMed Central PMCID: PMC5796510.
- 31 Takimoto M, Sato T, Ichioka S. Reconstruction for labial adhesion in postmenopausal woman using vulvoperineal flap. *Case Reports Plast Surg Hand Surg.* 2019;6:136-9. doi: 10.1080/23320885.2019.1602474. PubMed PMID: 32002461; PubMed Central PMCID: PMC6968580.
- 32 Kukreja B, Chandra S, Gyn PAJO. Labial Adhesions in a Post-menopausal Woman. *Pan.* 2019;2:1-3.
- 33 Laih CY, Huang CP, Chou EC. Labial adhesion in a postmenopausal female: A case report. *Medicine (Baltimore).* 2020;99:e20803. doi: 10.1097/MD.00000000000020803. PubMed PMID: 32590764; PubMed Central PMCID: PMC7329012.
- 34 Tanvir T, Meeta M, Singh A. Complete Labial Fusion Causing Pseudo-Urinary Incontinence: A Long-Term Sequelae of Genitourinary Syndrome. *J Midlife Health.* 2020;11:257-9. doi: 10.4103/jmh.JMH_34_20. PubMed PMID: 33767568; PubMed Central PMCID: PMC7978044.
- 35 Murugesan A, Palaniappan Y, Kalaimani T. An Unusual Cause of Urinary Pseudo-incontinence: Two Rare Cases of Labial Fusion in Adolescent and Postmenopausal Women. *Journal of South Asian Federation of Obstetrics and Gynaecology.* 2021;12:196-8. doi: 10.5005/jp-journals-10006-1789.
- 36 Gungor Ugurlucan F, Yasa C, Tas IS, Aslay I, Yalcin O. Complete labial fusion causing urinary retention in a postmenopausal woman. *Am J Clin Exp Urol.* 2021;9:413-5. PubMed PMID: 34796258; PubMed Central PMCID: PMC8595084.
- 37 Bi Y, Chen Y, Li W, Jiang H, Qin J, Cheng J. Experience with successful treatment of severe recurrent vulvar adhesions: A case report. *Front Surg.* 2023;10:1052133. doi: 10.3389/fsurg.2023.1052133. PubMed PMID: 36843991; PubMed Central PMCID: PMC9944125.
- 38 Chuong CJ, Hodgkinson CP. Labial adhesions presenting as urinary incontinence in postmenopausal women. *Obstet Gynecol.* 1984;64:81S-4S. doi: 10.1097/00006250-198409001-00020. PubMed PMID: 6540850.
- 39 Kalantar E. Minimizing potential resistance among bacteria causing urinary tract infection. *J Nephropathol.* 2012;1:11-2. doi: 10.5812/jnp.3. PubMed PMID: 24475380; PubMed Central PMCID: PMC3886163.
- 40 Ghorbani M, Arabzad SM, Bahrami M. Implementing Shannon entropy, SWOT and mathematical programming for supplier selection and order allocation. *International Journal of Supply Chain Management.* 2012;1:43-7.