

Gastric Perforation Caused by Peritoneal Dialysis Catheter Insertion

Dear Editor

A 59-year-old male patient with stage five chronic kidney disease presented to the nephrologist to discuss long-term renal replacement therapy. Following an extensive evaluation and review of the patient's goals and access alternatives, peritoneal dialysis (PD) was selected. A double-cuffed catheter with a swan-neck subcutaneous configuration was used. Following local practice and standard postoperative preparation, percutaneous procedures were used, and no imaging guidance was applied. The left lower abdomen was selected as the exit site. The paramedian left below the umbilicus was the point of entry into the peritoneal cavity. To ensure optimal patient comfort, lidocaine 1% (Harvest Pharmaceutical Co., China) was administered to induce local anesthesia, from the entry site to the peritoneal cavity, before the procedure. Then, a 1 cm linear incision was made at the designated puncture site. Afterward, a blunt dissection of subcutaneous tissue was performed to expose the anterior sheath of the rectus abdominis muscle. A Veress needle was used to puncture the sheath centrally. Physiological saline was then infused into the abdominal cavity. The Veress needle was used to insert a guidewire into the parietal peritoneum, which was subsequently removed. The insertion site was gradually expanded to accommodate the installation of a dilator sheath, which was then advanced into the pelvic cavity. The PD catheter, equipped with a rigid stylet, was advanced through the sheath and positioned within the deep pelvis, with the distal cuff anchored within the rectus abdominis muscle. The guidewire was subsequently removed. Subsequently, the PD catheter was flushed with an appropriate volume of warmed dialysis fluid. The flushing fluid contained gastrointestinal contents. An intraoperative X-ray examination was ordered. Contrast through the PD catheter indicated gastric perforation (figure 1 A). Open surgery was performed when the X-ray confirmed the gastric perforation (figure 1 B). An open gastric repair procedure was immediately initiated.

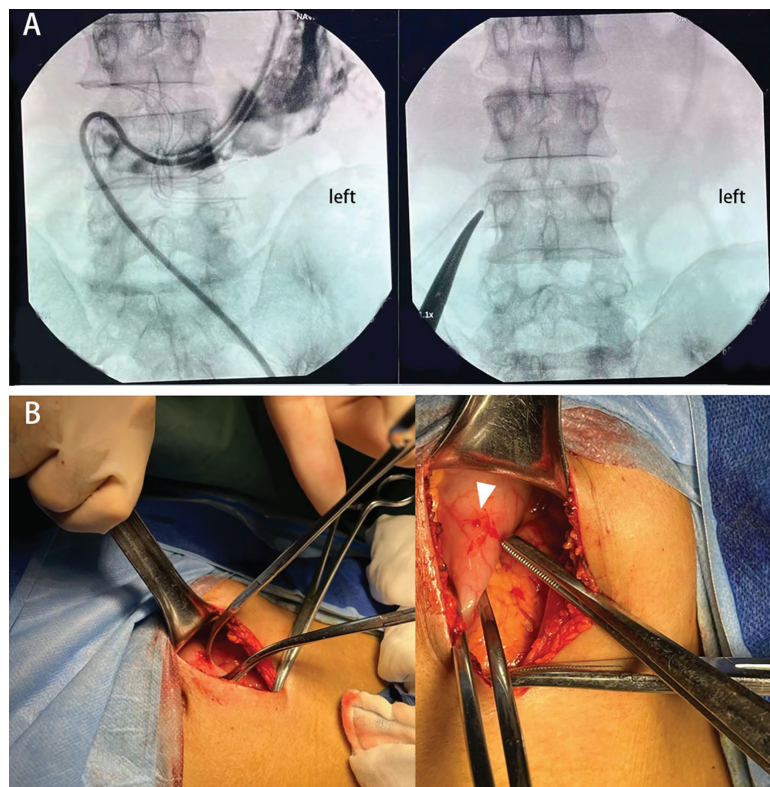


Figure 1: A) Intraoperative X-ray image: radiographic imaging was obtained intraoperatively. Contrast through PD catheter indicated gastric perforation. B) Open surgery confirmed the gastric perforation (white arrowhead).

In light of the technical complications associated with the peritoneal dialysis catheterization procedure, the patient's modality of renal replacement therapy was altered to hemodialysis. To the best of our knowledge, intestinal perforation or bladder perforation are primary consequences of PD catheter implantation.^{1,2} Besides, gastric perforation has not been reported, particularly when the entry site is the paramedian below the umbilical.

Written informed consent was obtained from the patient for publication of this case details and any accompanying images. All procedures performed in this study adhered to the institutional and/or national research committee's ethical requirements, as well as the 1964 Helsinki Declaration and later amendments or comparable ethical standards.

Acknowledgment

This study was financially supported by the Naval Medical Center of PLA (grant number: 21M3202, 21M3201, 21TPQN3201).

Authors' Contribution

W.H, N.L, and W.G: Caring for the patient, acquisition of data; B.Y: Conception and drafting the manuscript. All authors contributed to reviewing the manuscript. All authors have read and approved the final manuscript and agree to be accountable for all aspects of the work in ensuring that questions related to the accuracy or integrity of any part of the work are appropriately investigated and resolved.

Conflict of Interest: None declared.

Keywords • Peritoneal dialysis • Gastric perforation • Complications

Weifeng Hu, MD;  Naiying Lan, MD; Wei Gou, MD; Bo Yang, MD, PhD 

Division of Nephrology and Endocrinology, Naval Medical Center of PLA, Naval Medical University, Shanghai, China

Correspondence:

Bo Yang, MD, PhD;
West Huaihai Rd # 338, Shanghai, 200000, China
Tel: +86 21 81815134
Email: sternothyroid@live.com
Received: 09 October 2024
Revised: 23 December 2024
Accepted: 07 January 2025

Please cite this article as: Hu W, Lan N, Gou W, Yang B. Gastric Perforation Caused by Peritoneal Dialysis Catheter Insertion. *Iran J Med Sci*. doi: 10.30476/ijms.2025.104726.3829.

References

- 1 Peppelenbosch A, van Kuijk WH, Bouvy ND, van der Sande FM, Tordoir JH. Peritoneal dialysis catheter placement technique and complications. *NDT Plus*. 2008;1:iv23-iv8. doi: 10.1093/ndtplus/sfn120. PubMed PMID: 25983982; PubMed Central PMCID: PMC4421142.
- 2 Zou Y, Ma Y, Chao W, Zhou H, Zong Y, Yang M. Assessment of complications and short-term outcomes of percutaneous peritoneal dialysis catheter insertion by conventional or modified Seldinger technique. *Ren Fail*. 2021;43:919-25. doi: 10.1080/0886022X.2021.1925296. PubMed PMID: 34092201; PubMed Central PMCID: PMC8189143.