

The Flare Up of Catastrophic Antiphospholipid Syndrome: a Report of an Immunosuppressive Withdrawal-Induced Case

Sayyed Gholamreza Mortazavimoghaddam

Abstract

Antiphospholipid syndrome (APS) is a systemic disease that causes venous and arterial thrombosis in virtually any organ. Sometimes it is complicated into pulmonary infarction and cavitation, pulmonary hypertension, and catastrophic course with high morbidity and mortality. The present case is a 35-year-old woman with one episode of postpartum deep veins thrombosis (DVT) 12 years earlier and the second one after the second labor two years later. In spite of usual therapy for each episode of DVT, the condition had progressed into severe pulmonary hypertension. The diagnosis of primary APL syndrome was confirmed four years ago. She had been on warfarin, low dose of steroid, and azathioprine since the diagnosis of APL syndrome. After one year treatment with steroid and azathioprine the patient showed progressive well being; however, because of hyperglycemia the steroid tapered and discontinued. She had several attacks of paroxysmal atrial tachycardia in the last year. On the last time, she presented with severe dyspnea, hemoptesis, and lower limbs edema. Chest radiography and Lung CT scan demonstrated the presence of lung cavitations. Because of high suspicious for fungal pulmonary infection, azathioprine was also discontinued. However, constellation renal failure, hemodynamic instability, and confusion caused the patient to succumb to death. The definite diagnosis of lung cavitations was not obtained.

Iran J Med Sci 2011; 36(3): 226-230.

Keywords • Antiphospholipid syndrome • immunosuppressive • infection

Introduction

Antiphospholipid syndrome (APS) may predispose the patient to deep vein thrombosis (DVT), pulmonary thromboembolism (PTE), pulmonary hypertension and pulmonary infarction, and occasionally progress to pulmonary cavitations.¹⁻⁶ Therapy in these patients should be directed towards control of DVT and PTE.⁷ Corticosteroid and immunosuppressive therapy directed at reducing antibody are not advised routinely. In a special situation, recognized as catastrophic APL syndrome with recurrent PTE along with anticoagulant therapy, the recommendation is to start therapy with immunosuppressive agents.⁸⁻¹⁰ However, treatment with corticosteroid and other immunosuppressive agents predispose the patients to diabetes mellitus and opportunistic infections such as fungal infection. Opportunistic fungal infection such as mucormycosis and invasive aspergillosis

Pulmonary Ward, Vali-e-Asr Hospital,
Birjand University of medical Sciences,
Birjand, Iran.

Correspondence:

Sayyed Gholamreza
Mortazavimoghaddam MD,
Pulmonary Ward, Vali-e-Asr Hospital,
Ayatollah Ghaffari street,
Birjand, Iran.
Tel/Fax: +98 561 4435633
Email: gmortazavi@yahoo.com
Received: 14 September 2010
Revised: 23 November 2010
Accepted: 20 February 2011

are almost always reported in patients with major risk factors such as diabetic ketoacidosis, long term neutropenia, post transplantation, and high dose long term corticosteroid treatment.¹¹ These infections are aggressive, rapidly progressive, angioinvasive, and life-threatening diseases. Pulmonary mucormycosis has a rapid progressive course and result in lung cavitations with high a mortality rate.¹²

Catastrophic situation can often be aggravated by concomitant infection. Some less common condition resulting in catastrophic condition are surgical procedures, anticoagulation withdrawal, medications, obstetric complications, neoplasia and systemic lupus erythematosus (SLE) flares.¹⁰

The present case is one of the unique presentations of APL syndrome complicated with catastrophic flare up in a young woman, who died after a possible of fungal infection and immunosuppressive withdrawal.

Case Description

A 35-year-old woman presented to respiratory clinic because of acute onset of fever, dyspnea exacerbation, hemoptysis, and aggravated bilateral lower limbs edema. She had two significant episodes of DVT 12 and 10 years earlier after each childbearing. Her first infant suffered from congenital heart disease, and died at the age of 5 months. Afterwards, her condition progressed to pulmonary hypertension and right sided heart failure gradually in the last years. In spite of conventional treatment for DVT and pulmonary thromboembolism, her condition had developed to severe pulmonary hypertension, severe dyspnea and severe low-

er limb edema. She had high serum concentration of antiphospholipid antibodies (IgG: 22 GPL, IgM: 17 MPL) and anticardiolipine antibody (IgG: 25GPL, IgM: 21MPL), but normal rheumatologic tests including antinuclear antibody (ANA), rheumatoid factor (RF), and antineutrophil cytoplasmic antibodies (ANCA). The results of the tests confirmed the primary APL syndrome. Perfusion lung scanning demonstrated perfusion defects, which was interpreted as high probability of pulmonary thromboembolism (figure 1). Transthoracic echocardiography showed pulmonary pressure of 105 mmHg.

She started receiving warfarin aiming at an international normalized ratio (INR) of 3 to 4. The measurement of serum levels of antiphospholipid antibodies was repeated on the occasion of deciding about immunosuppressive therapy. Assuming the presence of multiple deep vein thrombosis, pulmonary thromboembolism, progressive pulmonary hypertension and positive antiphospholipid antibodies, prednisolone (60 mg/day) and azathioprine (50 mg twice a day) started hoping to prevent more catastrophic events. She was on treatment with warfarine, azathioprine and prednisolon for 12 months, after which corticosteroid was tapered and discontinued because of hyperglycemia. The patient then continued to receive azathioprine, warfarine and oral glucose lowering agents, and felt well until recently. Last year, she suffered from several attacks of paroxysmal atrial tachycardia; therefore, she was admitted to the hospital. Because of poor compliance, glycemic control was poor. There was no history of any serious infection during the last four years, and serial assays for com-

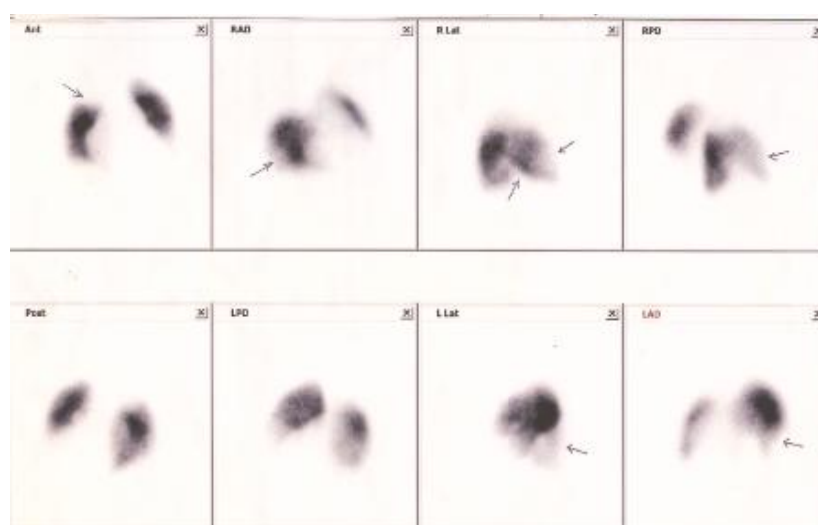


Figure 1: Perfusion lung Scan: Multiple segmental perfusion defects compatible with the presence of pulmonary thromboembolism.

plete blood count was normal. At the last presentation, the laboratory findings were as follows: urea; 55 mg/dl, creatinine; 1.1 mg/dl, glucose; 350 mg/dl, prothrombine time; 25 seconds, INR; 4.4, WBC; 10000/ μ l/with 75% segment and 20% lymphocyte. Microscopic examination of urine showed: WBC; 4-5/high power field, RBC; 4-5/high power field and negative for bacteria. Dip-stick urine tests showed positive for protein and glucose. Blood O₂ saturation was 93%. Chest radiography demonstrated bilateral infiltrations and cavitations (figure 2).

Chest computer tomography (CT) scan showed cavity in the medial segment of left lower lobe and a cavity in the apical segment of right lower lobe (figure 3). Blood culture for bacterial infections, and sputum smear for acid fast bacillus (AFB) were negative. Fungal stain showed elements of sporotrichosis. The patient was in poor condition, and semi invasive or invasive procedures were not performed. Liposomal amphotricine was not available; therefore, amphotricin B started empirically for possible invasive fungal infection of lung, and azathioprine was discontinued. Blood glucose remained in an acceptable range by regular insulin therapy. At the end of the first week, the patient continued to be much better, and blood sugar, urea and creatinine were remained in acceptable range. After two weeks of treatment, the patient was discharged and amphotricine was replaced by oral itraconazol. Because of recurrent paroxysmal atrial tachycardia, the patient was readmitted on day 7 after discharge. At this admission, the patient succumbed to severe dyspnea, increased urea (192 mg/dl) and creatinine (4.4 mg/dl), state of confusion, and was transferred to ICU on the day 5 of the admission. She was intubated and connected to mechanical ventilator. The portable chest radiography was not remarkable for complications such as pneumothorax or new infection. Brain CT scan was normal. The patient failed to improve, and died on the second day of ICU care with multi organ failure and homodynamic instability. The definite cause of lung infiltration and lung cavitations was not known. The final diagnosis was thought to be

catastrophic antiphospholipid after immunosuppressant cessation.

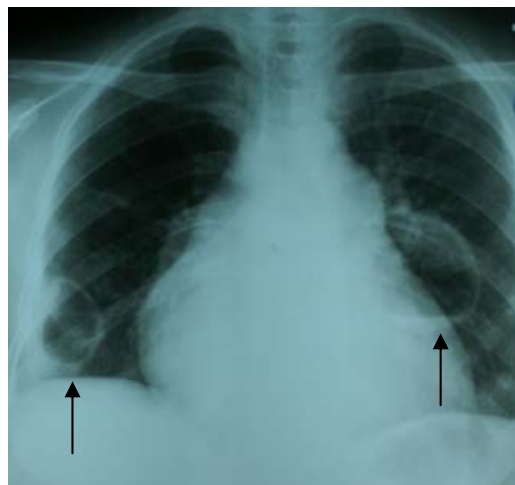


Figure 2: Chest radiography demonstrating two lung cavitations (arrows) and an enlarged heart.

Discussion

The patients did have the criteria for APL syndrome such as recurrent venous thrombosis, PTE, pulmonary hypertension, and pregnancy morbidity as well as the presence of high serum levels of antiphospholipid antibody and anticardiolipine.

As it occurred in the present case, pulmonary thromboembolism accompanied by DVT is the most frequent manifestation of APL syndrome.¹³ Anticoagulant therapies with heparin followed by life-long warfarine is the optimal prophylactic treatment.⁷ Since APL syndrome was not suspected in the present patient, anticoagulant was discontinued at the end of 6th month; therefore, subsequent multiple thromboembolic events resulted in pulmonary hypertension.

As this case illustrates, APL syndrome can be associated with chronic thromboembolic pulmonary hypertension.⁴ The association of pulmonary hypertension with APL syndrome was first reported in 1983.¹⁴ The prevalence of pulmonary hypertension in patient with APL syndrome is estimated to be 2 to 4%.¹⁵ On the

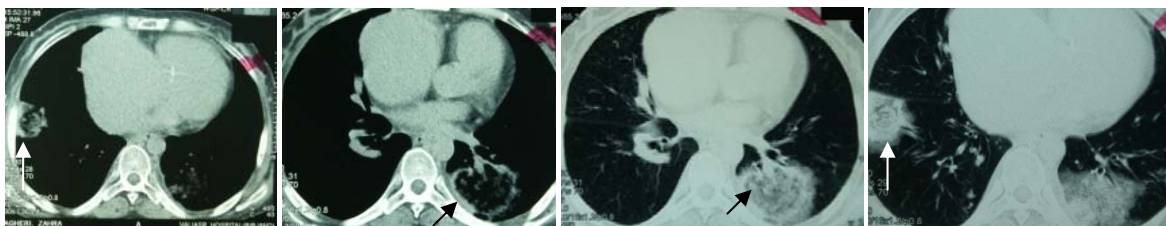


Figure 3: Chest computed tomography showing a cavity in the medial segment of left lower lobe and a cavity in the apical segment of right lower lobe (arrows).

other hand, the prevalence of APL in patients with chronic thromboembolic pulmonary hypertension is around 10 to 20%.¹⁶ Primary non-thromboembolic pulmonary hypertension was also reported in patients with primary APL syndrome. However, the prevalence of APL has been reported more frequently in thromboembolic type than in primary non-thromboembolic type of pulmonary hypertension.¹⁷ There is also evidence that APL may contribute to the pathogenesis of pulmonary hypertension in patients with connective tissue diseases.¹⁸

Some cases of APL syndrome fall into a catastrophic situation, which is characterized by overwhelming small vessel occlusive disease simultaneously affecting many organs in a short period of time. The catastrophic situation represents less than 1% of all patients with APL syndrome, and is usually life-threatening with a 50% mortality rate.⁹ Cerebral and cardiac involvements are the main causes of death in catastrophic variant of the syndrome, followed by bacterial and fungal infections. Because of highly-suspected fungal infection in the present case, azathioprine was discontinued. This might have predisposed the patient to flare up of catastrophic syndrome, which was presented as stupor, hemodynamic instability and renal failure after an initial improvement in the condition of patient due to amphotericin therapy. Infections (22%) and surgical procedures (10%) are the most common precipitating factors of catastrophic syndrome reported in catastrophic antiphospholipid syndrome registry followed by anticoagulation withdrawal or low INR (8%), medications (7%), obstetric complications (7%), neoplasia (5%) and SLE flare up (3%).¹⁰ In the present case, infection and immunosuppressive withdrawal were the main precipitating factors leading to catastrophic situation.

The lung cavitations were the main problem at admission. Pulmonary cavitations in patients with APL syndrome are rare, and there are only few case reports of the condition caused by pulmonary embolism and infarction followed by cavitations.^{1,2} It might be important to mention that the lung cavitations in the present case could not be due to microthrombosis, which is one of the major features of catastrophic syndrome. However constellation of long term uncontrolled hyperglycemia state, immunosuppressive therapy, and severely decompensated pulmonary circulation, could be predisposing the patient into opportunistic angioinvasive fungal infection such as mucormycosis.

Pulmonary mucormycosis is most often encountered in patients with diabetic ketoacidosis,

uncontrolled diabetes, hematological malignancy, severe burn, and after solid organ transplantation.^{11,12} The definite diagnosis of pulmonary mucormycosis is usually difficult and ante-mortem diagnosis has been made infrequently. Because of ill and decompensated condition in the present case, invasive diagnostic procedures such as bronchoscopy either percutaneous or open lung biopsy, were not possible. Postmortem autopsy was not also permitted by the patient's relatives either. Therefore, pulmonary mucormycosis was not confirmed pathologically.

Conclusion

The signs and symptoms of the present case might suggest that physicians should be aware of flare up of a catastrophic situation in patients with APL syndrome, if they decide to taper or discontinue the immunosuppressive or corticosteroid regimens. Besides, as the infection may be a possible cause of flare up or relapse, close observation of any infectious condition must be considered.

Conflict of Interest: None declared

References

- 1 Torok N, Abu Malouh A, Kasmani R, Abusamieh M. Cavitary lung lesions in systemic lupus: an unusual presentation. *Lupus* 2010; 19: 993-6.
- 2 Bertoli AM, Tabares AH, Casas JP, et al. Lung cavitation in primary antiphospholipid syndrome. *Lupus* 2002; 11: 57-9.
- 3 Wilson WA, Gharavi AE, Koike T, et al. International consensus statement on preliminary classification criteria for definite antiphospholipid syndrome: report of an international workshop. *Arthritis Rheum* 1999; 42: 1309-11.
- 4 Espinosa G, Cervera R, Font J, Asherson RA. The lung in the antiphospholipid syndrome. *Ann Rheum Dis* 2002; 61: 195-8.
- 5 Asherson RA, Cervera R, Piette JC, Shoenfeld Y. Editors, The antiphospholipid syndrome II: autoimmune thrombosis, Elsevier; 2002. p. 1-457.
- 6 Font J, López-Soto A, Cervera R, et al. The 'primary' antiphospholipid syndrome: antiphospholipid antibody pattern and clinical features of a series of 23 patients. *Autoimmunity* 1991; 9: 69-75.
- 7 Crowther MA. Anticoagulant therapy for the thrombotic complications of the antiphospholipid antibody syndrome. *Thromb Res* 2004; 114: 443-6.

- 8 Bucciarelli S, Erkan D, Espinosa G, Cervera R. Catastrophic antiphospholipid syndrome: treatment, prognosis, and the risk of relapse. *Clin Rev Allergy Immunol* 2009; 36: 80-4.
- 9 Cervera R. CAPS Registry Project Group. Catastrophic antiphospholipid syndrome (CAPS): update from the 'CAPS Registry'. *Lupus* 2010; 19: 412-8.
- 10 Cervera R, Bucciarelli S, Plasín MA, et al. Catastrophic antiphospholipid syndrome (CAPS): descriptive analysis of a series of 280 patients from the "CAPS Registry". *J Autoimmun* 2009; 32: 240-5.
- 11 Connolly JE Jr, McAdams HP, Erasmus JJ, Rosado-de-Christenson ML. Opportunistic fungal pneumonia. *J Thorac Imaging* 1999; 14: 51-62.
- 12 Yao Z, Liao W. Fungal respiratory disease. *Curr Opin Pulm Med* 2006; 12: 222-7.
- 13 Baker WF Jr, Bick RL. The clinical spectrum of antiphospholipid syndrome. *Hematol Oncol Clin North Am* 2008; 22: 33-52.
- 14 Asherson RA, Mackworth-Young CG, Boey ML, et al. Pulmonary hypertension in systemic lupus erythematosus. *Br Med J (Clin Res Ed)* 1983; 287: 1024-5.
- 15 Espinosa G, Cervera R, Font J, et al. Cardiac and pulmonary manifestation in the antiphospholipid syndrome, the antiphospholipid syndrome II: autoimmune thrombosis, Elsevier Science. B.V, 2002. p. 169-88.
- 16 Wolf M, Boyer-Neumann C, Parent F, et al. Thrombotic risk factors in pulmonary hypertension. *Eur Respir J* 2000; 15: 395-9.
- 17 Chaouat A, Weitzenblum E, Higenbottam T. The role of thrombosis in severe pulmonary hypertension. *Eur Respir J* 1996; 9: 356-63.
- 18 Asherson RA, Higenbottam TW, Dinh Xuan AT, et al. Pulmonary hypertension in a lupus clinic: experience with twenty-four patients. *J Rheumatol* 1990; 17: 1292-8.