

Leukemic Infiltration of the Appendix as an Unusual Site of Extramedullary Relapse: Report of Two Cases and Review of the Literature

Mahdi Shahriari^{1,2}, Mohammad Reza Bordbar^{1,2}, Bitā Geramizadeh³, Mehran Karimi^{1,2}

Abstract

The appendix is an unusual site for extramedullary relapse in acute leukemia. The present case report describes two cases of late course acute lymphoblastic leukemia presented with leukemic infiltration of the appendix and complete remission of bone marrow. The signs and symptoms of the cases suggest that leukemic involvement of the appendix should be considered in the differential diagnosis of leukemia patients presenting with acute abdomen.

Iran J Med Sci 2010; 35(3): 248-250.

Keywords • Acute lymphoblastic leukemia • appendix • appendicitis

Introduction

Acute leukemia is the most frequent malignancy of the childhood. Increased survival and prolonged remission of leukemic patients, as a result of modern combined anticancer therapies, has led to more frequent extramedullary infiltration of leukemic cells.¹ However, the involvement of the appendix in leukemia is extremely rare, especially when the disease is diagnosed antemortem or when a patient's bone marrow (BM) is in remission. Only sporadic reports of the antemortem recognition of leukemic appendiceal involvement have appeared in the literature.²⁻⁶

The present report describes the clinicopathologic features of two cases of acute lymphoblastic leukemia (ALL), while in complete BM remission, presented with leukemic involvement of the appendix and acute abdominal pain, which mimicked acute appendicitis requiring prompt appendectomy.

Case Description

Case 1

An 8.5 years old girl presented with one month history of fever, abdominal pain, and ankle and hip joints pain on January 2001. She had a moderate pallor, but no lymphadenopathy or hepatosplenomegaly. Complete blood count (CBC) revealed a hemoglobin level of 8.5 gm/dL, leukocyte count of 5700/mm³ with 43% lymphocyte and 6% lymphoblast, and platelet count of 209000/mm³. Bone marrow aspiration confirmed the diagnosis of ALL, with positive immunoreactivity of malignant cells for CD79 α , CD19, CD68, CD13, and negative immunoreactivity for CD10, CD7, CD3 and IgM. Chemotherapy of the patient began according to standard-risk pre-B-cell ALL protocol.⁷

After two years of chemotherapy, she was in complete BM remission, and her treatment was discontinued for almost two years. In March 2004, she referred back with the right lower

¹Hematology Research Center,
²Department of Pediatrics,
Nemazee Hospital,
³Department of Pathology,
Shiraz University of Medical Sciences,
Shiraz, Iran.

Correspondence:
Mohammad Reza Bordbar MD,
Department of Pediatrics,
Nemazee Hospital,
Shiraz University of Medical Sciences,
P.O. BOX: 71937-11351
Shiraz, Iran.
Tel/Fax: +98 711 6476298
Email: bordbarm@sums.ac.ir
Received: 1 August 2009
Revised: 18 October 2009
Accepted: 21 January 2010

quadrant abdominal pain that had been around for one month. Abdominopelvic sonography showed appendicular and bilateral ovarian masses. Exploratory laparotomy revealed a large unresectable retroperitoneal mass, an appendicular mass, and a bilateral ovarian mass. Biopsies of the above-mentioned masses revealed leukemic infiltration (figure 1). Meanwhile, BM examination was normal. Systemic re-induction chemotherapy began according to the recurrent ALL protocol using vincristine, methotrexate, Ara-C and L-asparaginase.

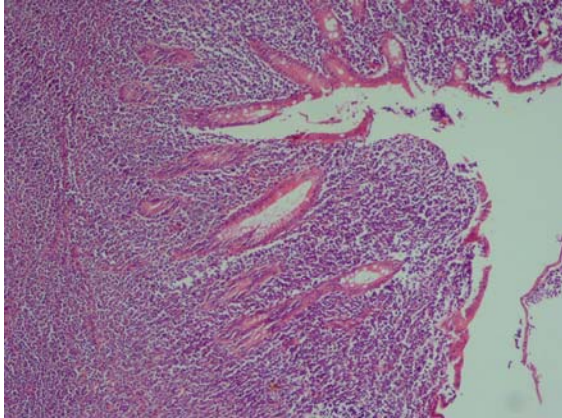


Figure 1: A microscopic section from appendiceal wall showing diffuse infiltration of leukemic cells (H&E ×250).

She was on maintenance chemotherapy using daily 6-mercaptopurine (6-MP), weekly methotrexate and monthly reinforcement courses of vincristine until January 2008, when she again developed abdominal pain. Abdominopelvic CT scan revealed multiple metastatic lesions in the bowel loops, mesentery, kidneys, ovaries and liver, suggestive of leukemic involvement. Biopsies of omental lymph nodes and small bowel mesentery were in favor of acute lymphoblastic leukemia/lymphoma of B-cell origin. Her BM was still in remission, and

she was treated according to recurrent ALL protocol,⁷ for the second time.

In July 2008, she presented with unilateral facial palsy. Her brain MRI was normal but cerebrospinal fluid (CSF) analysis confirmed CNS involvement. Bone marrow examination showed more than 80% lymphoblasts. Since she did not have any HLA-identical donor (related or unrelated), chemotherapy was changed to Ara-C, mitoxantrone and etoposide. However, she developed severe neutropenia followed by fulminant sepsis and severe coagulopathy, and finally died of disseminated aspergillus infection.

Case 2

An 18 month old boy presented with one week history of diarrhea, fever and abdominal pain on December 1998. Complete blood count showed thrombocytopenia and lymphoblasts in the peripheral blood. Bone marrow examination confirmed the diagnosis of ALL. Treatment started with vincristine, L-asparaginase and prednisone. He was in continuous complete remission until February 2002, when CSF analysis revealed CNS relapse. He was treated using the recurrent ALL protocol,⁷ followed by 12 sessions of 2400 CGY cranial irradiation.

He was in complete BM and CNS remissions until March 2005, when he presented with fever, diarrhea and abdominal pain. He was scheduled for laparotomy with presumptive diagnosis of acute appendicitis. At exploratory laparotomy, a normal-looking appendix and multiple mesenteric lymphadenopathy was detected. The lymph node biopsies and appendectomy specimen revealed leukemic infiltration (figure 2). His BM examination and CSF analysis were normal, and systemic re-induction chemotherapy was started. He was then put on maintenance chemotherapy till

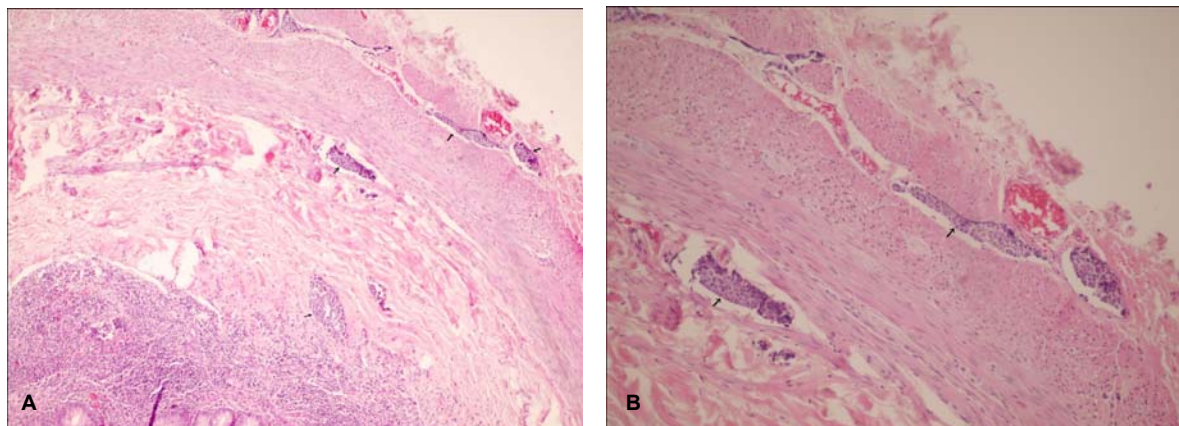


Figure 2: A-Case 2. Low-power view of the appendiceal wall. The arrows point to the nests of leukemic cells. B-High power view of the same field.

May, 2008. He was disease-free at the time of writing this report (mid 2009).

Discussion

Leukemic infiltration of the appendix, which was first described over one hundred years ago by Askanazy,⁸ is recently more prevalent. The results of autopsies have revealed a frequency of 10-40% in different studies.² However, leukemic involvement of the appendix diagnosed antemortem has been rarely seen. In an extensive review of the literature using PubMed and Embase databases with appendix, leukemic infiltration, appendicitis and appendectomy as keywords, about 20 cases of acute leukemia with the involvement of the appendix as the sole extramedullary organ, or accompanied by other organs including uterus, cervix, ovaries and other pelvic soft tissue were found.^{2-6,9}

Both cases of the present study presented with signs and symptoms of acute abdomen, and were scheduled for laparotomy with presumptive diagnosis of acute appendicitis. They were found to have leukemic infiltration of the appendix, while their BM was in complete remission. The relapses occurred late in the courses of the disease (3 and 7 years after initial diagnosis of ALL for case one and two, respectively).

Given that the patients, especially case 1, had multiple relapses in different organs including ovaries, bowel, intra-abdominal lymph nodes, liver and CNS, while their BM was in complete remission, the appendix should be considered as a sanctuary area like CNS, testes and kidneys, in which the presence of leukemic cells have been reported.¹

We believe that the reason for the frequent relapses of the first case, despite the administration of appropriate chemotherapeutic agents, was the presence of dormant leukemic cells in sanctuaries. These cells could escape the effects of chemotherapy, and repopulate in other organs including ovaries, bowel and finally BM. It should be kept in mind that BM remission does not imply the complete clearance of leukemic cell from the body.³ Furthermore, the increasing survival of leukemia patients with the aid of modern chemotherapy regimens justifies further the detection of extramedullary relapses even in unusual sites like the appendix.

Conclusion

The sign, symptoms and findings of the two

cases suggest that leukemic infiltration of the appendix should be considered in differential diagnosis of known cases of leukemia, who present with signs and symptoms of acute appendicitis.

Acknowledgement

We would like to express our special thanks to Dr. N. Shokrpour for editorial assistance and Mrs. M. Farahmandi for typing this manuscript.

Conflict of Interest: None declared

References

- 1 Mathé G, Schwarzenberg L, Mery AM et al. Extensive histological and cytological survey of patients with acute leukemia in "complete remission". *Br Med J* 1966; 1: 640-2.
- 2 Müller G, Dargent JL, Duwel V, et al. Leukemia and lymphoma of the appendix presenting as acute appendicitis or acute abdomen: four case reports with a review of the literature. *J Cancer Res Clin Oncol* 1997; 123: 560-4.
- 3 Cecalupo AJ, Frankel LS, Sullivan MP. Pelvic and ovarian extramedullary leukemic relapse in young girls: A report of four cases and review of the literature. *Cancer* 1982; 50: 587-93
- 4 Toubai T, Kondo Y, Ogawa T, et al. A case of leukemia of the appendix presenting as acute appendicitis. *Acta Haematol* 2003; 109: 199-201
- 5 Lyman MD, Neuhauser TS. Precursor T-cell acute lymphoblastic leukemia/lymphoma involving the uterine cervix, myometrium, endometrium and appendix. *Ann Diagn Pathol* 2002; 6: 125-8.
- 6 Palomino-Portilla EA, Valbuena JR, Quinones-Avila Mdel P, Medeiros LJ. Myeloid sarcoma of appendix mimicking acute appendicitis. *Arch Pathol Lab Med* 2005; 129: 1027-31.
- 7 Lanzkowsky P. Manual of pediatric Hematology and Oncology. 3rd ed. Elsevier academic press, 2000.
- 8 Askanazy M. Ueber acute leukämie und ihre Beziehung ZU geschwürigen prozessen im verdauungskanal. *Arch Pathol Anat Physiol Klin Med* 1894; 137: 1-24.
- 9 Shirkhoda A, Eftekhari F, Frankel LS, Lewis E. Diagnosis of leukemic relapse in the pelvic soft tissues of juvenile females. *J Clin Ultrasound* 1986; 14: 191-5.