

# An Aortoenteric Fistula Arising after Endovascular Management of a Mycotic Abdominal Aortic Aneurysm Complicated with a Psoas Abscess

Aytaç Gülcü<sup>1</sup>, MD;  
Naciye Sinem Gezer<sup>1</sup>, MD;  
Şevket Baran Uğurlu<sup>2</sup>, MD;  
Ahmet Yiğit Göktay<sup>1</sup>, MD

<sup>1</sup>Department of Radiology, Dokuz Eylül University Faculty of Medicine, Izmir, Turkey;

<sup>2</sup>Department of Cardiovascular Surgery, Dokuz Eylül University Faculty of Medicine, Izmir, Turkey

## Correspondence:

Naciye Sinem Gezer, MD;  
Department of Radiology,  
Faculty of Medicine,  
Dokuz Eylül University Hospital,  
Mithatpaşa Cad. 35340 Inciralti-Izmir,  
Turkey

Tel: +90 532 6818774

Email: drsinemgezer@gmail.com

Received: 14 October 2014

Accepted: 04 January 2015

## Abstract

Mycotic aortic aneurysms account for 1–3% of all aortic aneurysms. The management of this disease is controversial. Since open surgical repair is associated with high morbidity and mortality rates, endovascular aneurysm repair is an alternative treatment method with promising early and midterm outcomes, although its long-term durability is unknown.

Secondary aortoenteric fistulas may occur iatrogenically after either aortic reconstructive surgery or endovascular repair. As the number of aneurysms managed with endovascular aneurysm repair has substantially increased, cases of aortoenteric fistulas referred for endovascular repair are augmented.

We report the case of an aortoduodenal fistula manifested with duodenal perforation after staged endovascular and surgical treatment of a mycotic aortic aneurysm.

Please cite this article as: Gülcü A, Gezer NS, Uğurlu ŞB, Göktay AY. An Aortoenteric Fistula Arising after Endovascular Management of a Mycotic Abdominal Aortic Aneurysm Complicated with a Psoas Abscess. *Iran J Med Sci.* 2016;41(4):350-353.

**Keywords** • Aortic aneurysm • Infection • Fistula • Endovascular aortic repair

## What's Known

- Mycotic aortic aneurysms constitute a rare condition with an incidence of 1–3% of all aortic aneurysms. Patients present late with nonspecific symptoms. Early diagnosis and urgent treatment is vital.
- Surgical conversion after endovascular aortic repair (EVAR) is recommended when the patient is amenable to open surgery.

## What's New

- In mycotic aortic aneurysm patients with an aortoenteric fistula, EVAR should be accepted as a temporary method to save time and improve the patient's condition for surgery.
- Our case highlights the importance of meticulous follow-up for any possible complications after EVAR of a mycotic aneurysm.

## Introduction

Mycotic aortic aneurysms are a rare condition with a relative incidence of 1–3% of all aortic aneurysms.<sup>1</sup> The patients often present late with nonspecific symptoms, and these aneurysms are prone to rupture; therefore, early diagnosis and urgent treatment is vital. Computed tomography angiography (CTA) is the first-line imaging modality for the diagnosis of both mycotic aneurysms and complications such as aortoenteric fistulas (AEFs).

AEFs constitute a devastating clinical condition, which may cause abundant gastrointestinal hemorrhage with or without sepsis. Primary AEFs are secondary to degenerative abdominal aortic aneurysms. Secondary AEFs occur iatrogenically after either aortic reconstructive surgery or endovascular repair. Prompt diagnosis and treatment is mandatory because without surgical intervention, the mortality rate approaches 100%.

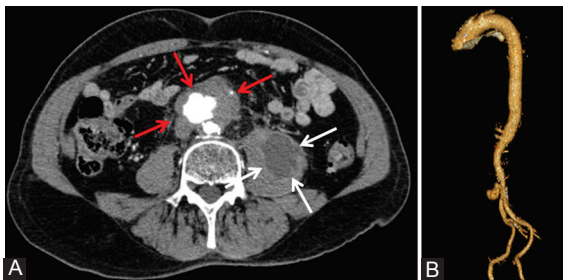
Surgical conversion after endovascular aortic repair (EVAR) is recommended for mycotic aneurysms when the patient is amenable to open surgery. Sugimoto et al.<sup>2</sup> reported that timely surgical intervention after the control of sepsis provided excellent outcomes, whereas the mortality rate of patients with sepsis or rupture was high.

## Case Report

A 72-year-old man was admitted to the emergency room with abdominal pain radiating to the back and high fever after extracorporeal shock-wave lithotripsy procedure. CTA revealed an irregularly shaped, saccular mycotic infrarenal abdominal aortic aneurysm with a maximum diameter of 59 mm (figure 1A and B). A left-sided psoas abscess (55×45×22 mm) was also recognized (figure 1A). Under ultrasonographic guidance, the psoas abscess was punctured with a Seldinger needle. A drainage catheter could not be placed; hence, the abscess cavity was not liquefied. However, 20 mL of fluid was successfully aspirated for microbiological examinations. Empiric intravenous antibiotherapy was administered upon clinical diagnosis since the aspirate and blood cultures were negative.

The infrarenal mycotic abdominal aortic aneurysm was treated with endovascular repair. Because it was saccular with adequate proximal and distal lengths, a tubular stent graft (23–23–70 mm, Endurant–Medtronic) was implanted. The aneurysm was totally excluded from the circulation. Control CTA was obtained at the first month, and it demonstrated total thrombosis of the mycotic aneurysm; however, the psoas abscess persisted.

The patient was admitted to the hospital with the same complaints 3 months after EVAR. Abdomen CTA examination showed growth and pressurization of the aneurysm sac by type 1B endoleak (figure 2) and expansion of the tubular stent graft at the distal end due to the growth of the aneurysm. The patient was retreated with a bifurcated stent graft. A main body (25–13–120 mm, Endurant–Medtronic) and a contralateral limb (16–13–80 mm, Endurant–Medtronic) were implanted. Both limbs of the stent grafts were dilated simultaneously with a 10-mm balloon.

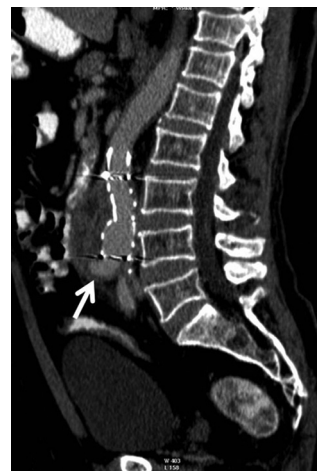

**Figure 1:** (A) Axial computed tomography angiography image of the irregularly shaped, saccular mycotic infrarenal abdominal aortic aneurysm (red arrows) and the left-sided psoas abscess (white arrows) is presented here. (B) Three-dimensional view of the mycotic aortic aneurysm is depicted.

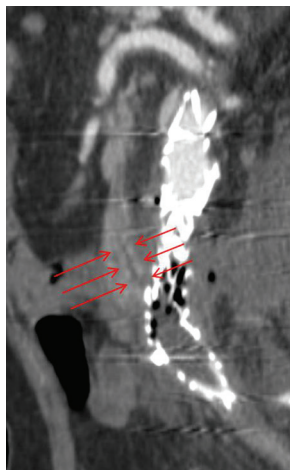
One month after re-intervention, the patient's left leg developed claudication in consequence of left-limb thrombosis due to compression. An extra-anatomic femorofemoral bypass graft was constituted surgically in order to cure the claudication.

The mycotic aneurysm sac had disappeared on CTA at 7 months' follow-up. Nonetheless, perigraft infection, air densities within the perigraft soft tissue and the main body of the tubular graft, and the thrombosed limb graft were observed. The psoas abscess remained stable since the diagnosis, and the symptoms relapsed despite the fact that the patient was on antibiotherapy. This time, total evacuation of the abscess cavity by percutaneous aspiration was performed successfully, but the aspirate and blood cultures were negative for the second time. Air densities inside the graft and perigraft soft tissue also became prominent during the follow-up period.

The patient was admitted to the emergency room with a septic syndrome after 14 months. Laboratory values demonstrated leukocytosis, neutrophilia, and increased C-reactive protein and sedimentation levels. Creatinine and bilirubin levels were also above normal values. Abdominal CT scan showed that the left-sided psoas abscess had grown to 9 cm in diameter and contained air fluid levels. The horizontal segment of the duodenum was adhered to the perigraft infectious tissue (figure 3). Therefore, stent graft explantation, extensive surgical debridement, aortic ligation, and extra-anatomic right axillofemoral bypass graft reconstruction were performed. The psoas abscess was drained with a percutaneously placed large-bore catheter, and intravenous antibiotherapy was



**Figure 2:** Sagittal reformat contrast-enhanced computed tomography images show the growing aneurysm sac by type 1B endoleak and the expanding tubular stent graft at the distal end due to the growing aneurysm.



**Figure 3:** Multiplanar reformat images of the aortoenteric fistula (red arrows) with negative oral contrast media.

administered. Although the abscess completely resolved and the catheter was withdrawn, it relapsed within 10 days. A drainage catheter needed to be introduced once again.

In the early postoperative period, symptoms of acute abdomen emerged and small-bowel content was drained out through the surgical drain. CT scan with positive oral contrast media revealed free fluid and air in the peritoneal cavity and contrast media leakage through the surgical drain due to a duodenal fistula. Another surgical operation was performed to repair the AEF. Finally the patient recovered and was discharged.

When preoperative CT scans were reviewed retrospectively, an AEF to the perigraft soft tissue was recognized. Although the duodenum was free from the process in the beginning, it became adherent to the perigraft infectious tissue as the disease advanced. A fistula could be differentiated in the CT scans with either positive or negative oral contrast media, which were acquired after the giant psoas abscess developed.

## Discussion

CTA is the modality of choice for the early recognition of mycotic aneurysms. Imaging findings include eccentric, saccular shaped, rapidly growing aneurysms with periaortic soft tissue stranding, free fluid, and gas. The involvement of the adjacent anatomical structures (vertebral body destruction, discitis, psoas abscess, and AEF) can accompany these features.<sup>3</sup>

Open surgical repair with long-term antibiotherapy is accepted as the gold standard of treatment for a mycotic aortic aneurysm.<sup>4</sup> It includes the resection of the infected aortic

segment, extensive debridement, and either an extra-anatomical bypass or in situ bypass with a cryopreserved arterial allograft.<sup>5</sup> Consequently, surgery has high morbidity and mortality rates.

Recently, EVAR has been considered an alternative for high-risk patients or patients who are in an unstable condition.<sup>4</sup> EVAR is a minimally invasive procedure with promising early and midterm outcomes; its long-term durability, however, is still undetermined.<sup>1,6</sup>

Based on data currently available, Strahm et al.<sup>7</sup> concluded that the early mortality rate of EVAR appeared to be lower than that of surgical repair. Nevertheless, late aneurysm-related complications and mortality appear to be higher in EVAR than in surgery because there is no possibility to debride the infectious tissue and the infected aortic wall.<sup>7,8</sup> Infection control gains major importance when an endograft is implanted in an infected hostile environment. Preoperative antibiotherapy duration has a major effect on the outcome of EVAR since persistent infection after EVAR is associated with a poor prognosis.<sup>7</sup> However Jia et al.<sup>9</sup> reported that in a series of 12 cases treated with EVAR for a primary mycotic aneurysm, the late relapse rate was high despite adjunctive drainage and aggressive antibiotherapy.

In our case, the patient was first subjected to EVAR for the mycotic aneurysm. However, the persistence of the infection caused the regrowth of the aneurysm, which was repaired with a bifurcated graft. Although the mycotic aneurysm sac vanished and the patient had asymptomatic periods, the third segment of the duodenum became adherent to the periaortic region because of ongoing infection. Eventually, a fistula between aorta and duodenum evolved, producing gas within the first tubular graft and its occluded left limb. The psoas abscess also changed its character and emerged as a giant anaerobic abscess. We evaluated this condition as an exacerbation of the psoas abscess; nonetheless, not only should it be regarded as a complication of an AEF but also other possible sources of infection should be evaluated.

The prognosis of patients with AEFs is known to be worse.<sup>1,6</sup> The incidence of secondary AEFs related to open surgical repair is reported to range between 0.4 and 1.6%.<sup>10</sup> The incidence of AEFs due to EVAR is uncertain. As the proportion of aneurysms managed with EVAR has substantially increased, cases of AEFs referred for endovascular repair are augmented.<sup>10-12</sup> Progressive aortic wall erosion by the rigid extremities of the stent and infectious and inflammatory processes inside the wall of the aneurysm are among the major reasons

for fistula formation. Endoleak coil embolization and endotension are other proposed causative mechanisms.<sup>6,10,12</sup> Therefore, the risk of an AEF is further increased in EVAR-treated mycotic aneurysms. Surgical conversion after EVAR is recommended for mycotic aneurysms when the patient is amenable to open surgery. EVAR can provide opportunity to stabilize the patient's condition and infection before the operation. Sugimoto et al.<sup>2</sup> reported that timely surgical intervention after the control of sepsis provided excellent outcomes, whereas the mortality rate of patients with sepsis or rupture was high.

## Conclusion

In mycotic aortic aneurysm patients with AEFs, endovascular repair should be accepted as a temporary method to save time and improve the patient's condition for surgery. Although the risk of the rupture of the aneurysm is eliminated, there is a predisposition for the recurrence of the mycotic aneurysm and the development of an AEF in this hostile environment if the infection source is not eradicated, as was the case in our patient. Surgical conversion after EVAR is recommended for mycotic aneurysms when the patient is amenable to open surgery. Our case highlights the importance of a careful follow-up of any possible complications after EVAR on a mycotic aneurysm and optimal timing for surgical repair.

**Conflict of Interest:** None declared.

## References

- Clough RE, Black SA, Lyons OT, Zayed HA, Bell RE, Carrell T, et al. Is endovascular repair of mycotic aortic aneurysms a durable treatment option? *Eur J Vasc Endovasc Surg.* 2009;37:407-12. doi: 10.1016/j.ejvs.2008.11.025. PubMed PMID: 19211280.
- Sugimoto M, Banno H, Idetsu A, Matsushita M, Ikezawa T, Komori K. Surgical experience of 13 infected infrarenal aortoiliac aneurysms: preoperative control of septic condition determines early outcome. *Surgery.* 2011;149:699-704. doi: 10.1016/j.surg.2010.12.015. PubMed PMID: 21429546.
- Vu QD, Menias CO, Bhalla S, Peterson C, Wang LL, Balfe DM. Aortoenteric fistulas: CT features and potential mimics. *Radiographics.* 2009;29:197-209. doi: 10.1148/rg.291075185. PubMed PMID: 19168845.
- Tamura K, Yoshitaka H, Totsugawa T, Tsushima Y, Chikazawa G, Ohno T, et al. Bridge use of endovascular repair and delayed open operation for infected aneurysm of aortic arch. *Ann Thorac Surg.* 2013;96:1471-3. doi: 10.1016/j.athoracsur.2013.01.095. PubMed PMID: 24088465.
- Woon CY, Sebastian MG, Tay KH, Tan SG. Extra-anatomic revascularization and aortic exclusion for mycotic aneurysms of the infrarenal aorta and iliac arteries in an Asian population. *Am J Surg.* 2008;195:66-72. doi: 10.1016/j.amjsurg.2007.01.032. PubMed PMID: 18082544.
- Kan CD, Lee HL, Yang YJ. Outcome after endovascular stent graft treatment for mycotic aortic aneurysm: a systematic review. *J Vasc Surg.* 2007;46:906-12. doi: 10.1016/j.jvs.2007.07.025. PubMed PMID: 17905558.
- Strahm C, Lederer H, Schwarz EI, Bachli EB. Salmonella aortitis treated with endovascular aortic repair: a case report. *J Med Case Rep.* 2012;6:243. doi: 10.1186/1752-1947-6-243. PubMed PMID: 22894684; PubMed Central PMCID: PMC3443667.
- Forbes TL, Harding GE. Endovascular repair of Salmonella-infected abdominal aortic aneurysms: a word of caution. *J Vasc Surg.* 2006;44:198-200. doi: 10.1016/j.jvs.2006.03.002. PubMed PMID: 16828445.
- Jia X, Dong YF, Liu XP, Xiong J, Zhang HP, Guo W. Open and endovascular repair of primary mycotic aortic aneurysms: a 10-year single-center experience. *J Endovasc Ther.* 2013;20:305-10. doi: 10.1583/13-4222MR.1. PubMed PMID: 23731302.
- Chenu C, Marcheix B, Barcelo C, Rousseau H. Aorto-enteric fistula after endovascular abdominal aortic aneurysm repair: case report and review. *Eur J Vasc Endovasc Surg.* 2009;37:401-6. doi: 10.1016/j.ejvs.2008.11.037. PubMed PMID: 19211278.
- Shree D, Jeppu S, Puneet P, Rani K. Computed tomography diagnosis of a primary aortoduodenal fistula in a patient with a partially thrombosed abdominal aortic aneurysm. *Jpn J Radiol.* 2010;28:534-7. doi: 10.1007/s11604-010-0457-6. PubMed PMID: 20799019.
- Saratzis N, Saratzis A, Melas N, Ktenidis K, Kiskinis D. Aortoduodenal fistulas after endovascular stent-graft repair of abdominal aortic aneurysms: single-center experience and review of the literature. *J Endovasc Ther.* 2008;15:441-8. doi: 10.1583/08-2377.1. PubMed PMID: 18729556.