

Sulfur Mustard Exposure and Non-Ischemic Central Retinal Vein Occlusion

Nasser Shoeibi^{1,2}, MD;
Mahdi Balali-Mood^{3,4}, MD, PhD;
Mojtaba Abrishami⁵, MD

¹Retina Research Center, Department of Ophthalmology, School of Medicine, Mashhad University of Medical Sciences, Mashhad, Iran;

²Eye Research Center, Department of Ophthalmology, School of Medicine, Mashhad University of Medical Sciences, Mashhad, Iran;

³Medical Toxicology Research Center, School of Medicine, Mashhad University of Medical Sciences, Mashhad, Iran;

⁴Department of Clinical Toxicology, Imam Reza Hospital, School of Medicine, Mashhad University of Medical Sciences, Mashhad, Iran;

⁵Eye Research Center, Department of Retina and Vitreous, Farabi Eye Hospital, Tehran University of Medical Sciences, Tehran, Iran

Correspondence:

Mojtaba Abrishami, MD;
Farabi Eye Hospital, Qazvin Square,
Postcode: 1336616351, Tehran, Iran
Tel: +98 21 55400003
Fax: +98 21 55418080
Email: mojtaba_abrishami@yahoo.com
Received: 01 September 2013
Revised: 27 November 2013
Accepted: 22 December 2013

What's Known

- Central retinal vein occlusion (CRVO) has various etiologies, mostly because of hypercoagulopathies or cardiovascular diseases.
- Ocular manifestations of mustard gas have been mostly reported in the anterior segment.

What's New

- Mustard gas exposure may have retinal manifestations.
- Mustard gas is an etiology of non-ischemic central retinal vein occlusion.

Abstract

A 41-year-old man was referred with a complaint of visual loss in his left eye and his best corrected visual acuity was 20/80. Slit lamp examination showed arborizing conjunctival vessels and dry eye. Fundus examination and fluorescein angiography revealed a non-ischemic central retinal vein occlusion. Cardiovascular, rheumatologic, and hematologic work up showed no abnormal findings. An ascertained history of exposure to sulfur mustard during the Iran-Iraq war was documented in his medical history. Four sessions of intravitreal bevacizumab injections were done as needed. After two-year follow-up, visual acuity in his left eye improved to 20/25 and macular edema was resolved without any need for further interventions. We conclude that sulfur mustard gas exposure may be considered as a predisposing factor for central retinal vein occlusion, as was found in our patient (an Iranian war veteran) by excluding all yet known etiologies and predisposing factors.

Please cite this article as: Shoeibi N, Balali-Mood M, Abrishami M. Sulfur Mustard Exposure and Non-Ischemic Central Retinal Vein Occlusion. *Iran J Med Sci.* 2016;41(1):59-63.

Keywords • Sulfur mustard • Central retinal vein occlusion • Retina • Visual loss • Iran

Introduction

Chemical warfare agents (CWA) such as sulfur mustard (SM), a vesicant agent, were extensively used against the Iranian troops and civilians during 1983-1988.¹ Initial toxic effects of SM involve the lungs, skin, and eyes. Moreover, proliferating cells of bone marrow may also be affected. Other proliferating stem cells may also involve and induce long-term impairments, including respiratory and ocular complications.²⁻⁸

Central retinal vein occlusion (CRVO) is a relatively common retinal vascular disorder and a frequent cause of visual morbidity in patients older than 50 years and can be associated with systemic vascular disease and coagulopathy. Although most patients with CRVO are over 65 years, it can occur in younger patients commonly termed papillophlebitis. Younger patients frequently have an associated inflammatory cause or coagulopathy, which deserve particular attention.⁹

Up to now, as far as we are aware, no early or late retinal complication of SM exposure has been reported. Here, we report a fairly young man presented with non-ischemic CRVO without any systemic known predisposing factor except for a history of SM exposure.

Case Report

A 41-year-old man was referred to our eye hospital with a complaint of sudden visual loss in his left eye. An eye examination showed that his best corrected visual acuity (BCVA) in the right eye (RE) was 20/20 and in the left eye (LE) was 20/80. Relative afferent pupillary defect (RAPD) was slightly positive in the left eye as sluggish movement of the iris. Intraocular pressure (IOP) was 13 and 15 mmHg in RE and LE, respectively. Slit lamp examination showed arborizing conjunctival vessels and dryness in both eyes. Tear break-up time was less than five seconds, which indicated an abnormal tear film. Fundusoscopic examination of his right eye showed no specific abnormality. In the left eye, retinal hemorrhage in all quadrants of the retina, retinal edema, venous tortuosity, and macular edema were present (Figure 1). In fluorescein angiography delayed circulation, hyperfluorescence due to the breakdown of the blood-retinal barrier, venous tortuosity, and blockage due to retinal hemorrhages were obvious (Figure 2). In ocular optical coherence tomography (OCT), macular edema was obvious and central macular thickness was increased to 357 microns (Figure 3). The findings were compatible with a diagnosis of non-ischemic CRVO.

Systemic workup and initial laboratory tests for known causes of CRVO were performed. Purified protein derivative (PPD) test was negative (4 millimeters). HIV (ELIZA), antinuclear antibody (ANA), and rheumatoid factor (RF) tests were also negative. Chest X-ray was normal. All biochemical, immunological and hematologic investigations revealed no abnormalities and the results are summarized in Tables 1 and 2.

The patient had no history of systemic arterial hypertension, no obvious cardiac disease, and no connective tissue diseases. However, cardiology and rheumatology consultations were requested. Echocardiographies, both trans-thoracic and trans-esophageal, were negative for structural cardiac abnormalities. Carotid Doppler ultrasonography results were within normal limits. Rheumatology consultation also revealed no related connective tissue disease. Although all routine coagulation laboratory tests were within normal limits, we also requested hematologic consultation to rule out any coagulopathies. The result was normal. After 15 months, the consultations were repeated and again all were reported as normal.

Again, we reviewed his possible use of any drug, medication (either chemical or herbal) trauma, smoking, and familial history of such

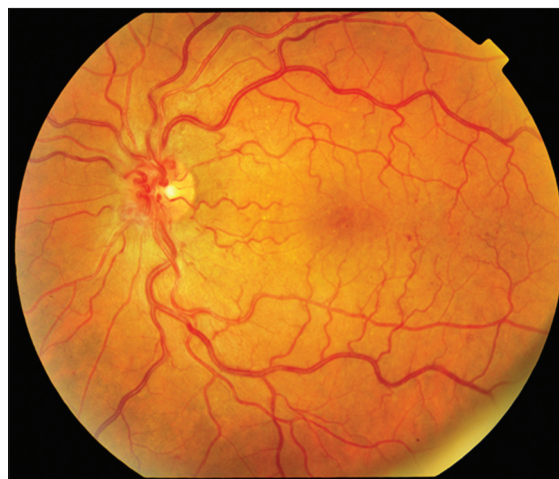

Figure 1: Shows fundus photo of the patient who was exposed to sulfur mustard showing vascular tortuosity, hemorrhages, and macular edema.

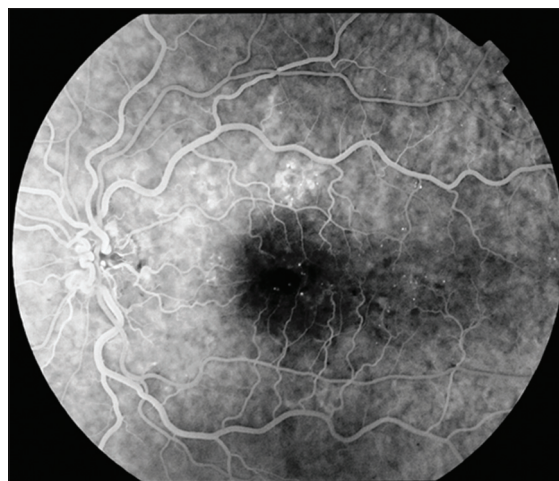

Figure 2: Fluorescein angiography showing vascular tortuosity, macular edema, hemorrhages, multiple hypo and hyperfluorescence of the fundus in a 41-year-old male patient who was exposed to sulfur mustard.

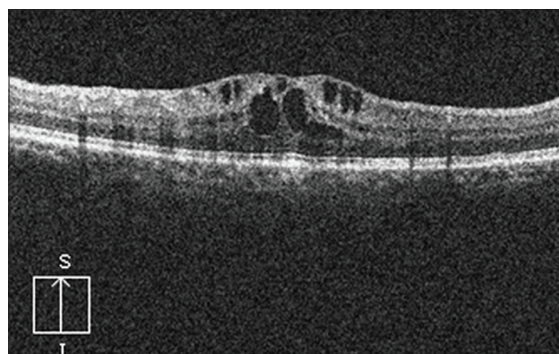


Figure 3: Optical coherent tomography (OCT) of the macula showing macular edema in a 41-year-old male patient who was exposed to sulfur mustard.

diseases. They were all negative. However, the patient had three times exposure to SM during 1987-1988 Iran-Iraq war. He had ambulatory admission and treatment in a field hospital after

Table 1: Results of the biochemical and immunological investigations

Test	Result	Unit	Normal
Serum protein C	88	%	70-150%
Serum protein S	124	%	65-135%
Protein C activity	140	%	70-160%
Protein S activity	131	%	55-160%
Anticardiolipin (IgM)	1	Mpl/ml	Up to 12
Anticardiolipin (IgG)	2	Gpl/ml	Up to 12
Anti-phospholipid Antibody (IgM)	2	IU/ml	Up to 15
Anti-Phospholipid antibody (IgG)	1	IU/ml	Up to 12
Prothrombin time (PT)	13	Seconds	13
Partial thromboplastin time	29	Seconds	30
Fasting blood sugar	92	Mg/dl	70-100
Cholesterol	163	Mg/dl	120-200
Triglyceride	46	Mg/dl	40-200
LDL-C	39	Mg/dl	30-80
HDL-C	88	Mg/dl	Up to 160
Creatinine	0.9	Mg/dl	Up to 1.2
Homocysteine	13.4	Micromol/l	5-15

Table 2: Results of the hematologic investigations

Test	Result	Unit	Normal
Antithrombin III	115	%	80-125
Factor V leiden	3.3	Ratio	More than 2
Serum protein electrophoresis			
Albumin	59.66	%	52-63
Alpha 1	1.64	%	1.5-4.5
Alpha 2	9.75	%	6-12
Beta	13.46	%	11-17
Gamma	14.67	%	11-19
Complete blood count			
White blood cell	6500	Cell/microL	4500-11000
Neutrophil	3600	Cell/microL	2000-7500
Lymphocyte	2100	Cell/microL	1500-3500
Red blood cell	5.14	$\times 10^6$ cell/microL	4.5-6
Hematocrit	46.0	%	42-48
Platelet	178	$\times 10^3$ cell/microL	100-450
C reactive protein (CRP)	1	Mg/l	0-5
Erythrocyte sedimentation rate (ESR)			
First hour	2	Millimeter	2-6
Second hour	4	Millimeter	4-10
Katz index	2.0	Index	4-10

the last SM exposure in 1988 and recovered within two days. Since then, he has never had any serious complication.

Following written informed consent, he received four serial intravitreal injections of an anti-vascular endothelial growth factor,

bevacizumab (1.25 mg/0.05 milliliter), as an off-label treatment modality. After one year, the central macular thickness decreased to 334 microns and vision improved to 20/25. No obvious systemic or ocular complications related to the injection were noticed. The patient was followed up for more than 24 months during which he had stable retina and vision. IOP did not increase more than 20 mmHg during the follow up period. The patient was informed about the publication of this case report and an oral consent was obtained.

Discussion

Sulfur mustard (SM) [bis-(2-chloroethyl) sulfide] is an oily liquid. SM and similar bifunctional agents have been produced as chemical weapons since the 19th century. High dose exposure to SM may result in death within hours or weeks.⁴ However, low-dose exposure may cause injury to the eyes, skin, and respiratory tract without any mortality. Very low dose of SM exposure may not induce any symptom or sign and thus it is called subclinical exposure. It seems that our patient had two subclinical exposures in 1987 and one mild symptomatic SM exposure in 1988, after which he recovered within a couple of days.³⁻⁷ However, long term effects and delayed complications of SM poisoning are well known and several reports are available, particularly on the respiratory tract, skin and the eyes.⁶⁻⁸

The eye is the most sensitive organ to SM. It could be due to ocular characteristics such as high turnover rate, intense metabolic activity of corneal epithelial cells, and the aqueous-mucous surface of the cornea and conjunctiva.¹⁰⁻¹² As it is absorbed by the lungs and skin, it may disseminate in the body and act as a toxic agent involving the internal organs as well.¹³ To our knowledge, no retinal abnormal finding ensuing SM exposure has been reported yet. Endothelial cells are proposed to be injured in the SM toxicities and may induce apoptosis and necrosis in endothelial cells all over the body.¹³ This may explain the vascular permeability in acute phase after exposure, which can result in bronchial edema.¹⁴ Long term effect of SM on vessels may predispose them to occlusion, particularly in microvasculature system such as the retina. This may explain possible mechanism of retinal vein occlusion in our patient.

CRVO is usually associated with systemic cardiovascular diseases and coagulopathies; and is mostly observed in elderly.¹⁰ However, it is difficult to find the etiology of CRVO in youth.

It has been evident that CRVO is different in young adults from older patients. CRVO in young adults is probably a general (nonspecific) change that results from a number of individual causes or a combination of causes. In unusual cases, the cause is known but in the vast majority of the patients, the specific cause or even the contributing factors are unknown. This is mainly due to limited literature and the paucity of histopathologic material from patients with such condition.¹¹

In our case, we performed a wide array of laboratory tests, systemic work up, and consultations according to the current findings and algorithms.^{10,11}

As all our tests and consultations were normal, we re-evaluated the patient and found a history of exposure to SM, a highly toxic chemical warfare agent that may have caused or played a predisposing factor for his non-ischemic CRVO. We thus propose that SM may cause or act as a predisposing factor for non-ischemic CRVO. However, experimental and clinical studies are required to confirm this hypothesis.

Acknowledgement

The authors thank Mrs. M. Kadkhoda for her assistance with fluorescein angiography and fundus photographs of the patient. This research received no specific grant from any funding agency in the public, commercial, or nonprofit sectors.

Conflict of Interest: None declared.

References

1. Council UNS. Report of the mission dispatched by the secretary general to investigate allegations of the use of chemical weapons in the conflict between the Islamic Republic of Iran and Iraq. New York: United Nations Council, 1988.
2. Safarinejad MR, Moosavi SA, Montazeri B. Ocular injuries caused by mustard gas: diagnosis, treatment, and medical defense. *Mil Med.* 2001;166:67-70. PubMed PMID: 11197102.
3. Ghabili K, Agutter PS, Ghanei M, Ansarin K, Panahi Y, Shoja MM. Sulfur mustard toxicity: history, chemistry, pharmacokinetics, and pharmacodynamics. *Crit Rev Toxicol.* 2011;41:384-403. doi: 10.3109/10408444.2010.541224. PubMed PMID: 21329486.
4. Balali-Mood M, Hefazi M. The pharmacology, toxicology, and medical treatment of sulphur mustard poisoning. *Fundam Clin Pharmacol.* 2005;19:297-315. doi: 10.1111/j.1472-8206.2005.00325.x. PubMed PMID: 15910653.
5. Hefazi M. The clinical toxicology of sulfur mustard. *Arch Iran Med.* 2005;8:162-79.
6. Balali-Mood M, Hefazi M, Mahmoudi M, Jalali E, Attaran D, Maleki M, et al. Long-term complications of sulphur mustard poisoning in severely intoxicated Iranian veterans. *Fundam Clin Pharmacol.* 2005;19:713-21. doi: 10.1111/j.1472-8206.2005.00364.x. PubMed PMID: 16313284.
7. Balali-Mood M, Afshari R, Zojaji R, Kahrom H, Kamrani M, Attaran D, et al. Delayed toxic effects of sulfur mustard on respiratory tract of Iranian veterans. *Hum Exp Toxicol.* 2011;30:1141-9. doi: 10.1177/0960327110389501. PubMed PMID: 21071549.
8. Etezad-Razavi M, Mahmoudi M, Hefazi M, Balali-Mood M. Delayed ocular complications of mustard gas poisoning and the relationship with respiratory and cutaneous complications. *Clin Experiment Ophthalmol.* 2006;34:342-6. doi: 10.1111/j.1442-9071.2006.01220.x. PubMed PMID: 16764654.
9. London NJ, Brown G. Update and review of central retinal vein occlusion. *Curr Opin Ophthalmol.* 2011;22:159-65. doi: 10.1097/ICU.0b013e3283459737. PubMed PMID: 21460724.
10. Hayreh SS, Podhajsky PA, Zimmerman MB. Natural history of visual outcome in central retinal vein occlusion. *Ophthalmology.* 2011;118:119-33 e1-2. doi: 10.1016/j.ophtha.2010.04.019. PubMed PMID: 20723991; PubMed Central PMCID: PMC2989417.
11. Fong AC, Schatz H. Central retinal vein occlusion in young adults. *Surv Ophthalmol.* 1993;37:393-417. doi: 10.1016/0039-6257(93)90138-W. PubMed PMID: 8516752.
12. Sharma M, Pant SC, Pant JC, Vijayaraghavan R. Nitrogen and sulphur mustard induced histopathological observations in mouse visceral organs. *J Environ Biol.* 2010;31:891-905. PubMed PMID: 21506473.
13. Dabrowska MI, Becks LL, Lelli JL, Jr., Levee MG, Hinshaw DB. Sulfur mustard induces apoptosis and necrosis in endothelial cells. *Toxicol Appl Pharmacol.* 1996;141:568-83. doi: 10.1006/taap.1996.0324. PubMed PMID: 8975783.

14. Veress LA, O'Neill HC, Hendry-Hofer TB, Loader JE, Rancourt RC, White CW. Airway obstruction due to bronchial vascular injury after sulfur mustard analog inhalation. Am

J Respir Crit Care Med. 2010;182:1352-61. doi: 10.1164/rccm.200910-1618OC. PubMed PMID: 20639443; PubMed Central PMCID: PMC3029928.