

Spontaneous Resolution of Symptomatic Thoracic Spine Calcified Disc Herniation: A Case Report and Literature Review

Ali Babashahi¹, MD; Morteza Taheri², MD; Parham Rabiee³, MD

¹Department of Neurosurgery, Rasool Akram Hospital, Iran University of Medical Sciences, Tehran, Iran;

²Department of Neurosurgery, Iran University of Medical Sciences, Tehran, Iran;

³Department of Radiology, Lar University of Medical Sciences, Fars, Iran

Correspondence:

Morteza Taheri, MD;

Department of Neurosurgery, Rasool Akram Hospital, Postal Code:

14456-13131, Tehran, Iran

Tel: +98 912 0194908

Fax: +98 21 66509120

Email: drtaheri38@yahoo.com

Received: 12 December 2017

Revised: 14 May 2018

Accepted: 3 June 2018

What's Known

- Calcification of the intervertebral disc is an uncommon but well-defined clinical syndrome in children. The spontaneous regression of a calcified disc is more common in cervical and lumbar regions; hence thoracic is a rare site.
- Despite this benign nature, occasionally, calcified nucleus pulposus herniates within the ruptured annulus fibrosus, and become symptomatic.

What's New

- A rare case of calcified disc herniation in the thoracic spine in a child (at the mid-thoracic) is reported, which is the rarest site for this pathology.
- The occurrence of calcification within disc herniation is rare. Conservative management resulted in spontaneous resolution of the pathology despite its neurological symptoms.

Abstract

Calcification of intervertebral disc (IVD) is an uncommon but well-defined clinical syndrome in children. Despite its benign nature, occasionally, calcified nucleus pulposus can herniate into the spinal canal. We report an interesting case of calcified disc herniation in the thoracic spine. Although it resulted in cord compression and syrinx formation, it well responded to conservative management. An 8-year-old girl presented with back pain and lower limbs hyperreflexia. The spinal imaging revealed that calcification within IVD, associated with huge calcified disc herniation on the T5/6, resulted in cord compression and syrinx formation within the spinal cord from T4/5 through T9/10. Despite cord compression and syrinx formation, the patient underwent conservative management. After a 6-month follow-up, the control imaging showed complete resolution of the calcified disc herniation and decreased syrinx size. In the patients with a calcified herniated IVD, in the absence of motor neurological deficit, conservative management consisting of bed rest, lifestyle adjustment, weight loss, and brace or collar wearing combined with a close follow-up can result in spontaneous regression of calcification, improvement of symptoms, and partial to complete resolution of the underlying pathology.

Please cite this article as: Babashahi A, Taheri M, Rabiee P. Spontaneous Resolution of Symptomatic Thoracic Spine Calcified Disc Herniation: A Case Report and Literature Review. *Iran J Med Sci.* 2019;44(3):251-256. doi: 10.30476/IJMS.2019.44981

Keywords • Intervertebral disc herniation • Calcified disc herniation • Spontaneous regression • Thoracic spine

Introduction

Calcified intervertebral disc (IVD) is an uncommon well-defined entity in children.¹ The etiology of this health problem is, however, not known yet.²

Despite its benign nature, occasionally, calcified nucleus pulposus passes the ruptured annulus fibrosus, herniates to the spinal canal, and results in neurological symptoms.² Herniated IVD, as a rare entity mainly occurring in the thoracolumbar region, is less common in thoracic spine than cervical and lumbar regions.³ The T11/12 is the most common site of herniation, due to the higher mobility of this region and a weakened posterior longitudinal ligament.³

Spontaneous regression of a large symptomatic calcified thoracic disc herniation is a rare phenomenon, with few cases reported in the literature.³ The prognosis for this condition is good in children. Besides, the pain is resolved in this process and spontaneous resolution of the calcification occurs.²

Despite its benign nature, occasionally, calcified nucleus pulposus herniates within ruptured annulus fibrosus, leading to extradural space occupying lesion and spinal root or cord compression.² In this situation, one might ask whether surgical intervention may ultimately be necessary.

In the present study, we report an interesting case of calcified disc herniation in the thoracic spine. Although it resulted in cord compression and syrinx formation, it responded well to a conservative management.

Case Presentation

An 8-year-old girl was presented with back pain for several months. Physical examination demonstrated only hyperreflexia in the lower limbs with no paraparesis, sphincter deficits, or Babinski sign. The spinal computed tomography scan (CT scan) and magnetic resonance imaging (MRI) revealed the calcification within IVD associated with huge calcified disc herniation at T5/6 (black arrows in figure 1 and 2). Herniation resulted in cord compression and syrinx formation within the spinal cord from T4/5 through T9/10 (red arrow in figure 1). Despite cord compression and syrinx formation, due to only minimal neurological deficit, the patient underwent conservative and medical management including weight loss, lifestyle modification (adapting to a correct posture and keeping the spine in normal alignment; adjustments to daily standing, sitting, and sleeping habits; avoidance of stress, heavy work, and lifting heavy objects; having more rest), and brace wearing. After a 6-month follow-up, the control imaging showed a complete resolution of the calcified disc herniation and a decrease in syrinx size (figure 3). At the last clinical follow-up, one year later, the patient was symptom-free and hyperreflexia was improved.

A written informed consent was obtained from the patient's parents for the publication of this case report.

Discussion

Calcification of IVD is an uncommon but well-defined clinical syndrome in children; however, its etiology is not known yet.^{1, 2} The most common causes of calcification include trauma, inflammation, and increased hydrostatic pressure within a disc; however, the definite etiology is not known.² Recently, one study demonstrated that viral-induced vasculitis can be a probable etiology via interruption of the blood supply and ischemia.¹ Also, the occurrence of mild upper

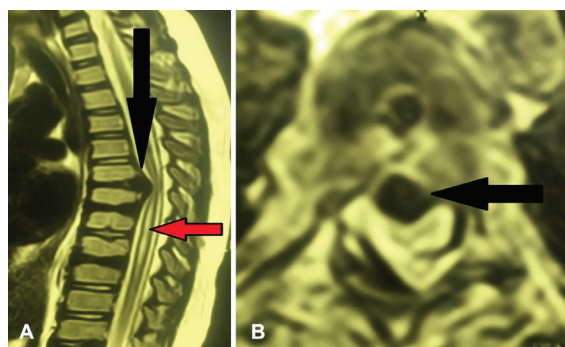


Figure 1: The spinal MRI of the central disc herniation, cord compression, and syrinx formation. A: Sagittal T2, B: Axial T2.

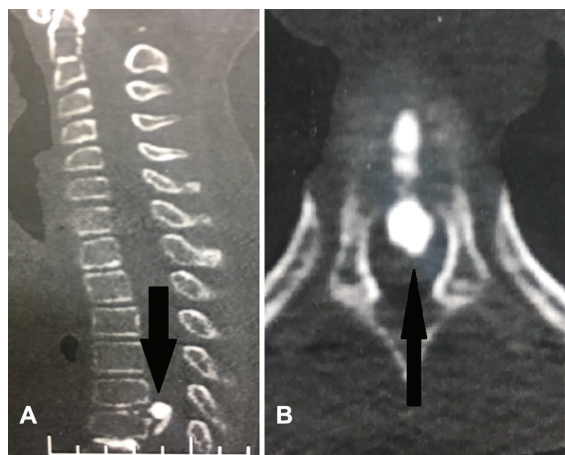


Figure 2: The spinal CT scan of the central calcified disc herniation. (A) Sagittal plane, (B) Axial plane.

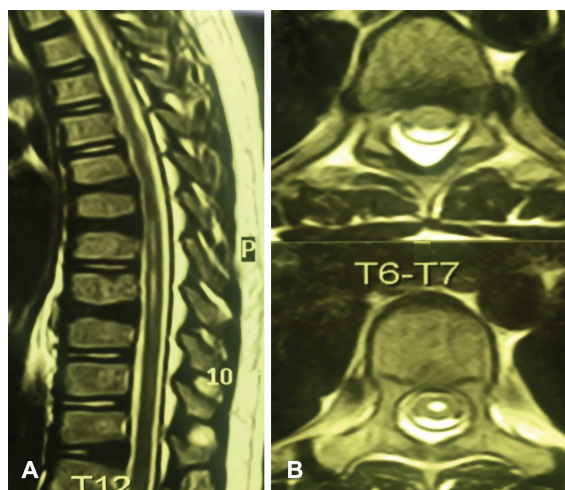


Figure 3: The 6-month follow-up MRI of the complete resolution of the disc herniation associated with partial improvement of the spinal syrinx. (A) Sagittal plane, (B) Axial T2.

tract infection/injury has been proposed as a possible cause by some researchers.⁴

Calcification of IVD in adults is different from that in children. First, calcification is more common in adults. Secondly, in adults, it involves annulus fibrosus in addition to nucleus pulposus. Thirdly, it is mainly a degenerative process; however, it can also reflect a systemic disease.

Finally, it is more common at the mid-thoracic and upper lumbar regions.² Herniation of a calcified IVD is the most serious complication of this condition.² It is more common in children with an age range of 5-10 years, men suffer from it more often than women, and the cervical region is affected more than the lumbar and thoracic regions.¹

The differential diagnoses consist of metabolic disorders (hyperparathyroidism, homocystinuria, alkaptonuria, and acromegaly), arthritis (ankylosing spondylitis, gout, and pseudogout), amyloidosis, and rarely disc hemorrhage in hemochromatosis. Compared to the calcified disc herniation, these differential diagnoses usually affect more than one level of the IVD space, involve other joint spaces rather than IVD space only, and affect the patients in an age group different from patients with calcified disc herniation.¹ These underlying conditions have not been frequently demonstrated in children.⁴

In the majority of patients, treatment is conservative and consists of bed rest, collar or brace wearing for immobility, and nonsteroidal anti-inflammatory drugs (NSAIDs). In addition, surgery is recommended in case of uncontrolled pain or progressive neurological deficit.¹ The definite mechanisms for the regression of calcified disc herniation are not well defined, but some probable mechanisms have been proposed: (i) disc dehydration and subsequent resolution of a dehydrated disc fragment, (ii) degradation and resolution of the disc fragment due to an activated inflammatory process, (iii) adjustment of the nucleus pulposus within disc material in the new situation, (iv) facilitated neovascularization due to the presence of a disc fragment within extradural space, and (v) macrophage infiltration and phagocytosis.³ Due to the higher prevalence of spontaneous regression of a calcified disc in the cervical and lumbar regions, thoracic is a rare site for this condition.⁵

Jevtic,² Mahapatra and others,⁶ Donmez and others,⁷ and Sieron and others⁸ reported cases of calcification only within IVD material without a considerable herniation of the disc material. All their patients were symptomatic and responded to the conservative and medical management. In contrast to the above-mentioned studies, there are some reports of IVD calcification accompanied by calcification of the herniated disc. The decision to opt for conservative or surgical treatment is a problematic issue with such patients; however, it mainly depends on the clinical condition of the patients. Ho and others¹ reported two cases of calcified IVD. The first case was a 7-year-old boy presented

with calcification of the IVD and extrusion of the herniated disc at C2/3 level. They managed the patient with medical and conservative treatments. At 6-month follow-up, they observed a marked decrease in the calcification of IVD and a complete resolution of calcified disc extrusion. The second case was a 4-year-old girl with calcification of disc herniation. After conservative management, at 3-year follow-up, a complete resolution of calcification occurred at C4/5 and significantly decreased at C5/6.¹

Dhammi and others⁴ reported the case of a 2-year-old girl with a calcified disc herniation at T11/12 level accompanied by the thecal sac herniation. At 10-month follow-up, a complete resolution of the calcification had occurred. Li and others,⁹ and O'Dell and others¹⁰ also reported cases of calcified disc herniation in children. They managed their patients conservatively. A follow-up demonstrated a complete or significant decrease in calcification of the disc herniation and improvement of the symptoms. Nevertheless, Sato and others¹¹ reported the case of a 13-year-old girl with a calcified disc herniation at C7/T1 and T1/2 levels. Due to progressive paraparesis, surgical intervention was performed. At 5-year follow-up, a marked decrease in calcification at C7/T1 and a complete resolution at T1/2 was observed. Gerlach and others¹² also reported a similar case in which the patient was operated on due to the progressive neurologic deterioration. The above-mentioned reports indicate a tendency toward medical and conservative management, and surgical intervention is performed only in the setting of progressive neurological symptoms. Moreover, they demonstrate that good results in both clinical and radiologic examinations are expected following conservative management. Table 1 summarizes some of the most important studies that reported a spontaneous regression of calcified herniated disc.

The present case report demonstrated a rare pathology in an 8-year-old girl. Considering her age, there was no significant difference compared to other studies. Similar to a study by Fremont and Peck¹³ (T6 involvement) and Dhammi and others⁴ (T7/8 involvement), the pathology in our patient occurred in the mid-thoracic level (T5/6) which is the rarest site for this entity. However, in the majority of the surveyed studies, the site of involvement was the cervical or cervicothoracic junction.^{1, 6-12}

The surveyed studies demonstrated that surgical intervention is performed on patients with cord compression and associated symptoms. However, despite cord compression and the associated compressive sequel, we followed up

Table 1: Summarized results of the studies reporting calcified IVD herniation

Study	Year	Age	Sex	Symptom	Level	Management	Symptom improvement	Radiological improvement
Fremont ¹³	1956	12	Male	Pain in the mid-scapular region	T6	Surgical (partial resection)	Painless at discharge	Only a trace of residual calcium at 6 months
Dhammi and others ⁴	2002	12	Female	Mid-back pain	T7/8, T11/12	Conservative	Diminish at 3 weeks, disappeared at 10 months	Asymptomatic at 4 years, no radiological change at 4 years
Jevtic ²	2004	7	Male	Neck pain and stiffness	C4/5 to C7/1	Conservative	Asymptomatic after 6 weeks	Minimal remnants after six weeks
Ho and others ¹	2012	7	Male	Severe neck pain	C2/3	Conservative	Resolution at 6 months	Marked decrease in disc calcification, near-complete resolution of the extruded calcified disc at 6 months
Li and others ⁹	4	4	Female	Neck pain	C4/5, C5/6	Conservative	Rapid improvement	Complete resolution at C4-C5, decreased but persistent calcification at C5-C6
Sato and others ¹¹	2012	13	Female	Radiating neck pain	C5/6	Conservative	Asymptomatic after 4 weeks	Small areas of calcification at C5-C6 disk after 4 months, completely resolved herniated region
Gerlach and others ¹²	2005	13	Female	Neck pain/progressive paresis and sensory loss	C7/1, T1/2	Surgical (C5-T2 laminoplasty)	Able to walk within 1 month after surgery	Unchanged on C7-T1 and T1-T2 at 5 years after surgery, diminished calcification of the spinal canal at C7-T1 and disappearance at T1-T2
Mahapatra and others ⁶	2013	8	Male	Severe radiating neck pain/progressive paresis and sensory loss	C6/7, T1/2	Surgical (CDF)**	Neurological deficits completely resolved 2 weeks after surgery.	No further compression after 3 months post-surgery
O'Dell and others ¹⁰	2016	9	Male	Pain and stiffness*	C3/4	Conservative	Pain and spasm gradually reduced in 12 days	Not reported
Dönmez and others ⁷	2008	7	Male	Neck pain and stiffness	C2/3	Conservative	Not reported	Complete resolution after 3 months
Sieron and others ⁸	2013	5	Female	Neck pain	C6/7	Conservative	Diminished 10 days later	Almost completely resolved in 6 months
Garg and others ¹⁴	2012	7	Male	Headaches, torticollis, and neck pains	C2/3, C3/4	Not reported	Not reported	Not reported
Our study	2017	8	Female	Severe neck pain	C2/3	Conservative	Significant improvement in 1 week and complete resolution in 8 weeks	Near-complete resolution after 3 months
				Back pain	T5/6	Conservative	Gradually diminished over 3 months	Complete resolution in 6 months

*He underwent treatment and received completed 22 weeks of chemotherapy as a misdiagnosis of pulmonary TB. **ACDF: Anterior cervical discectomy and fusion

our patient conservatively due to non-progressive symptoms and minimal neurologic signs. In comparison with the surveyed studies, the unique feature of our case report is the presence of syrinx in the spinal cord due to the compressive effect of the calcified disc herniation. Moreover, our patient responded well to a conservative therapy with early improvement of the symptoms and radiological improvement at 6-month follow-up. The latest follow-up demonstrated the durable effect of conservative management; similar to the findings in the majority of the reported studies.

In summary, the present case report highlighted some unique features. First, it presented calcified herniated IVD, which is generally a rare entity. Secondly, the pathology occurred in the thoracic spine, which is a less common site for IVD and calcified IVD. Thirdly, calcified herniated IVD occurred at the T5/6 level (mid-thoracic level), which is the rarest site for IVD within the thoracic spine. Fourthly, calcified herniated IVD resulted in cord compression and somewhat in syrinx formation, but only with minimal neurological deficits. Finally, regarding the management of this condition, we followed the recommendations stated in the literature and began management with medical treatment despite the presence of syrinx, and obtained good clinical and radiological responses.

Conclusion

Based on the recommendations stated in the literature, we treated our patient conservatively despite the presence of compressive signs on the spinal cord (syrinx and hyperreflexia). Consequently, good clinical and radiological responses were obtained. In patients with calcified herniated IVD, in the absence of significant and progressive neurological deficit, this health problem can be managed conservatively even in severe radiological cases.

Conservative management consisting of bed rest, lifestyle adjustment, brace or collar wearing, and weight loss combined with a close follow-up can result in spontaneous regression of calcification, improvement of symptoms, and partial to complete resolution of the underlying pathology.

Conflict of Interest: None declared.

References

- 1 Ho C, Chang S, Fulkerson D, Smith J. Children presenting with calcified disc herniation: a self-limiting process. *J Radiol Case Rep.* 2012;6:11-9. doi: 10.3941/jrcr.v6i10.1162.

- PubMed PMID: 23378872; PubMed Central PMCID: PMC3558272.
- 2 Jevtič V. A calcified cervical intervertebral disc in a child and a thoracic disc calcification in an adult with posterior herniation-radiographic, computed tomography and magnetic resonance imaging findings. *Radiol Oncol.* 2004;38: 339-47.
- 3 Harshavardhana NS, Panvica TP, Pinto MR. Spontaneous Regression of a Large Symptomatic Calcified Central Thoracic Disc Herniation: A Case Report with a Review of the Literature. *J Head Neck Spine Surg.* 2017;1:555565. doi: 10.19080/jhns.2017.01.555565.
- 4 Dhammi IK, Arora A, Monga J. Calcified thoracic intervertebral disc at two levels as a cause of mid-back pain in a child: a case report. *J Orthop Sci.* 2002;7:587-9. doi: 10.1007/s007760200105. PubMed PMID: 12355136.
- 5 Sari H, Misirlioglu TO, Palamar D. Regression of a symptomatic thoracic disc herniation with a calcified intervertebral disc component. *Acta Orthop Traumatol Turc.* 2016;50:698-701. doi: 10.1016/j.aott.2015.05.002. PubMed PMID: 27956079.
- 6 Mahapatra SK, Sud A, Mehtani A. Pediatric cervical disc calcification simulating tubercular spondylitis - A case report. *J Clin Orthop Trauma.* 2013;4:46-8. doi: 10.1016/j.jcot.2013.02.002. PubMed PMID: 26403776; PubMed Central PMCID: PMC3880512.
- 7 Donmez H, Mavili E, Ikizceli T, Koc RK. Pediatric intervertebral disc calcification. *Diagn Interv Radiol.* 2008;14:225-7. PubMed PMID: 19061169.
- 8 Sieron D, Gruszczynska K, Machnikowska-Sokolowska M, Olczak Z, Knap D, Baron J. Intervertebral disc calcification in children: Case description and review of relevant literature. *Pol J Radiol.* 2013;78:78-80. doi: 10.12659/PJR.883773. PubMed PMID: 23493855; PubMed Central PMCID: PMC3596152.
- 9 Li M, Rong W, Pan X, Yu L. Single-level calcified cervical disk herniation in a 13-year-old girl. *Orthopedics.* 2012;35:e1297-301. doi: 10.3928/01477447-20120725-40. PubMed PMID: 22868626.
- 10 O'Dell MC, Flores M, Murray JV, Jr. Pediatric Idiopathic Intervertebral Disc Calcification. *Pediatr Neurol.* 2016;61:115-6. doi: 10.1016/j.pediatrneurol.2016.04.009. PubMed PMID: 27215406.
- 11 Sato K, Nagata K, Park JS. Calcified intervertebral disc herniation in a child with myelopathy treated with laminoplasty. *Spinal Cord.*

- 2005;43:680-3. doi: 10.1038/sj.sc.3101755. PubMed PMID: 15968306.
- 12 Gerlach R, Zimmermann M, Kellermann S, Lietz R, Raabe A, Seifert V. Intervertebral disc calcification in childhood--a case report and review of the literature. *Acta Neurochir (Wien)*. 2001;143:89-93. PubMed PMID: 11345723.
- 13 Peck FC, Jr. A calcified thoracic intervertebral disk with herniation and spinal cord compression in a child; case report. *J Neurosurg*. 1957;14:105-9. doi: 10.3171/jns.1957.14.1.0105. PubMed PMID: 13385709.
- 14 Garg M, Kumar S, Satija B, Gupta R. Pediatric intervertebral disc calcification: A no touch lesion. *J Craniovertebr Junction Spine*. 2012;3:23-5. doi: 10.4103/0974-8237.110123. PubMed PMID: 23741126; PubMed Central PMCID: PMC3669470.