

Adult Ileo-Ileal Intussusception Caused by Intestinal Lipoma

Dear Editor,

Intussusception is an invagination of a portion of bowel into distal segment. While common in children, it is a rare cause of bowel obstruction in adults and usually is caused by a lead point. Most causes of adult small bowel intussusceptions are benign intestinal lesions like lipoma, leiomyoma, neurofibroma, inflammatory polyps, and meckel diverticulum.¹ Patients usually present with bowel obstruction or vague abdominal symptoms. Diagnosis is not usually achieved clinically or by laboratory data, but CT imaging is helpful for diagnosis.² Our patient is a 45-year-old woman presented with intermittent abdominal pain. Physical examination was unremarkable and abdominopelvic sonography and upper GI endoscopy were normal. Abdominopelvic CT-Scan performed during an episode of pain showed thickening and invagination of a bowel segment (figure 1). The patient underwent surgery and an Ileo-Ileal intussusception was noticed approximately 100 cm to ileocecal valve invagination was reduced. A palpable mass was found in Ileum. Resection and anastomosis of affected bowel were done. The patient postoperative course was uneventful. Histopathological examination reported a sub mucosal lipoma of ileum.

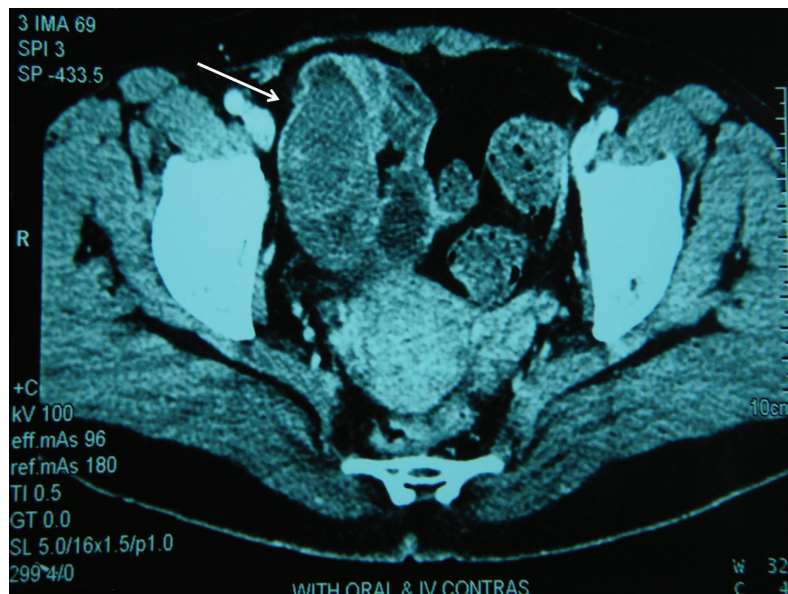


Figure 1: Abdominal CT-Scan shows thickening and invagination of a bowel segment into distal portion (white arrow).

Conflict of Interest: None declared.

Please cite this article as: Fazeli MS, Kazemeini AR, Elyasinia F, Parsaei R. Adult Ileo-Ileal Intussusception Caused by Intestinal Lipoma. *Iran J Med Sci.* 2014;39(6):589-590.

Mohammad Sadegh Fazeli, MD; Alireza Kazemeini, MD; Fezzeh Elyasinia, MD; Reza Parsaei, MD
Department of Surgery, Tehran University of Medical Sciences, Tehran, Iran

Correspondence:

Reza Parsaei, MD;
Department of General surgery,
Imam Khomeini Hospital,
Keshavarz Boulevard, Tehran, Iran
Tel: +98 216 1192606
Fax: +98 216 6581657
Email: parsaeir@irimc.org
Received: 4 January 2014
Revised: 26 April 2014
Accepted: 18 May 2014

References

- 1 Azar T, Berger DL. Adult intussusception. *Ann Surg.* 1997;226:134-8. doi: 10.1097/00000658-199708000-00003. PubMed PMID: 9296505; PubMed Central PMCID: PMC1190946.
- 2 Sandrasegaran K, Kopecky KK, Rajesh A, Lappas J. Proximal small bowel intussusceptions in adults: CT appearance and clinical significance. *Abdom Imaging.* 2004;29:653-7. PubMed PMID: 15185038.