

Mesenteric Panniculitis: An Enigma

Dear Editor

Mesenteric panniculitis (MP) is one of the few rare chronic inflammatory disorders with an unknown etiology. This could be due to an autoimmune disease, trauma, ischemia, medications, or allergies. The disease is more common in men and affects all age groups, with a peak prevalence in the sixth and seventh decades of life.¹

MP is difficult to diagnose due to nonspecific and varying types of clinical presentation. The diagnostic difficulty in this case is further increased by the presence of concurrent renal stones.

On 15 September 2022, a 52-year-old woman from rural North India with a body mass index (BMI) of 25.4 was referred to our hospital. She was admitted with pain in the left side of her abdomen that was insidious in onset, dull hurting, continuous, mild to moderate, and without any radiation. There were no signs of fever, diarrhea, and vomiting. Before being admitted to our hospital, she was referred elsewhere for ultrasonography of the whole abdomen, which revealed a 4 mm renal stone with no other remarkable finding in the rest of the abdomen. Although she was treated for renal stone, her symptoms did not resolve completely. Within 3 months following the initial symptom, a mass developed on the left side of her abdomen, for which she was treated with a repeated course of antibiotics with little result. Nausea, vomiting, dizziness, abdominal distention, and constipation were all symptoms of the mass. However, no fever or diarrhea was reported. To conduct further investigation, written informed consent was obtained from the patient. Contrast-enhanced computed Tomography (CECT) of the whole abdomen was performed. The findings revealed non-obstructive left renal calculi measuring 5.6 mm in size (figure 1) as well as enhancing circumferential mural thickening of the rectum, sigmoid colon, and distal segment of descending colon with perifocal fat stranding and multiple sub centimetric discrete mesenteric lymph nodes with pseudo capsule (figure 2).

Following sigmoid-colonoscopy and biopsy, it was discovered that the rectosigmoid was non-negotiably narrowed with normal mucosa and vascular pattern. The findings of the biopsy pointed to a nonspecific inflammatory pathology with no granulomas or atypical cells. Based on the CECT findings, a provisional diagnosis of MP was determined. Except for total leucocyte counts, which were $14.2 \times 10^9/L$ and predominantly neutrophils, all the laboratory parameters were within normal ranges.

Methylprednisolone (Pfizer, India), 40 mg per day, was prescribed for 14 days. Then, decreased over the next 14 days while also using a stool softener. After four weeks of medication, her symptoms improved, and her laboratory results became normal. Monthly follow-up abdominal CT scans revealed a remarkable improvement over time (figures 3A and B).

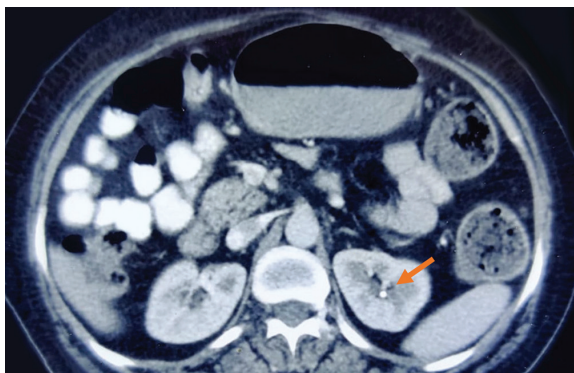


Figure 1: Contrast-enhanced computed tomography of the abdomen shows a left renal stone (size: 5.6 mm).

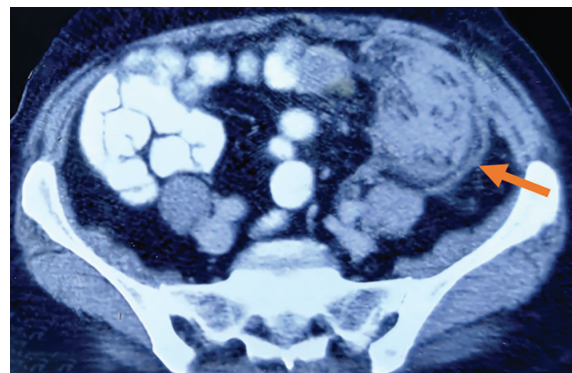


Figure 2: Contrast-enhanced computed tomography of the abdomen shows extensive fat stranding in the descending colon and proximal sigmoid colon suggestive of a large inflammatory mass (orange arrow).

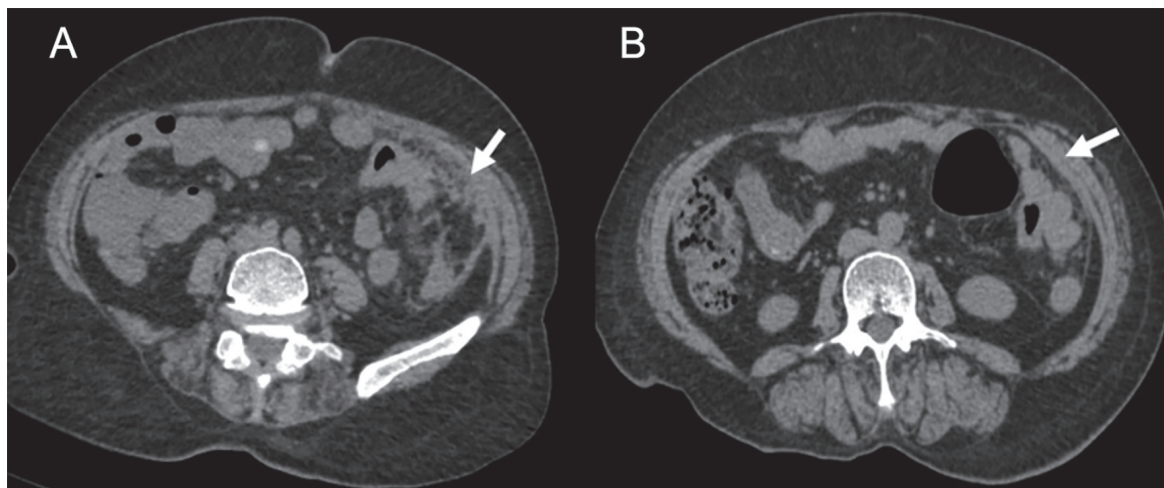


Figure 3: Contrast-enhanced computed tomography of the abdomen shows decreases in the size of inflammatory mass after one month (A), and complete disappearance of mass after three months (B).

Clinical manifestations of MP might range from asymptomatic to symptomatic. MP might be diagnosed as an incidental finding in as much as 7% of cases.² Gastrointestinal disturbance, abdominal pain, nausea, vomiting, diarrhea, constipation, weight loss, pyrexia of unknown origin, and chylous ascites are all possible symptoms.¹ The clinical presentation might resemble Crohn's disease.³ Moreover, it has an association with type 2 diabetes mellitus.⁴ Although MP might have an association with several neoplasms, no direct association was found between MP and malignancy.

CECT, magnetic resonance imaging (MRI), and biopsy are among the available diagnostic tools. In CECT, the fat ring sign, and the pseudo capsule sign are the two primary radiological signs, which are considered distinctive features of MP. Even so, the disease is not ruled out if these symptoms are absent. The retractile type of MP might differ significantly from the classic version. Depending on the degree of fibrosis, the retractile form may manifest as a mass that is mainly solid and fibrotic component or as a mass that lacks the pseudo capsule and fat ring sign.¹

Prednisolone with or without tamoxifen is the first-line treatment for symptomatic MP, with a positive response rate of 60% at 12-16 weeks.⁵ Other treatment options with different degrees of efficacy include colchicine, azathioprine, progesterone, cyclophosphamide, and thalidomide. Innovative treatments include thalidomide and low-dose naltrexone. According to the findings of a small case study, hormonal and immunomodulatory medications are also prescribed. However, they might have substantial side effects. Except for treating focal intestinal blockage caused by fibrotic types of the disease, surgical intervention is not curative and should be avoided.⁶

MP is a self-limiting inflammatory lesion, with a good prognosis, fewer recurrences, and serious complications. There is still no consensus on the duration of treatment and follow-up for asymptomatic cases. Due to the rarity of the disease, adequate randomized clinical trials on the most effective treatment approaches and the duration of prescribing immunosuppression have not been conducted.

Authors' Contribution

AK.G: Patient management and drafting, N.S: Data collection and reviewing of the manuscript. All authors have read and approved the final manuscript and agree to be accountable for all aspects of the work in ensuring that questions related to the accuracy or integrity of any part of the work are appropriately investigated and resolved.

Conflict of Interest: None declared.

Keywords • Mesentery • Panniculitis • Colon descending • Inflammation

Amit Kumar Gupta, MS; Niraj Shrivastava, MS

Department of General Surgery, AIIMS Raebareli, Uttar Pradesh, India

Correspondence:

Amit Kumar Gupta, MS;

Department of General Surgery, AIIMS Raebareli, Postal code: 229405, Uttar Pradesh, India

Tel: +91 84 33028881

Email: amitonline44@gmail.com

Received: 29 April 2023

Revised: 09 July 2023

Accepted: 28 July 2023

Please cite this article as: Gupta AK, Shrivastava N. Mesenteric Panniculitis: An Enigma. Iran J Med Sci. 2024;49(3):201-203. doi: 10.30476/IJMS.2023.98397.3074.

References

- 1 Buragina G, Magenta Biasina A, Carrafiello G. Clinical and radiological features of mesenteric panniculitis: a critical overview. *Acta Biomed.* 2019;90:411-22. doi: 10.23750/abm.v90i4.7696. PubMed PMID: 31910164; PubMed Central PMCID: PMC7233778.
- 2 Unlu E, Okur N, Acay MB, Kacar E, Ozdinc S, Balcik C, et al. The Prevalence of Incidentally Detected Idiopathic Misty Mesentery on Multidetector Computed Tomography: Can Obesity Be the Triggering Cause? *Can Assoc Radiol J.* 2016;67:212-7. doi: 10.1016/j.carj.2015.06.004. PubMed PMID: 27050489.
- 3 Nuzzo A, Zappa M, Cazals-Hatem D, Bouhnik Y. Crohn's disease mistaken for long-standing idiopathic mesenteric panniculitis: A case report and management algorithm. *Medicine (Baltimore).* 2016;95:e5073. doi: 10.1097/MD.0000000000005073. PubMed PMID: 27684882; PubMed Central PMCID: PMC5265975.
- 4 Tavares Pereira JP, Romao V, Eulalio M, Jorge R, Breda F, Calretas S, et al. Sclerosing Mesenteritis and Disturbance of Glucose Metabolism: A New Relationship? A Case Series. *Am J Case Rep.* 2016;17:55-9. doi: 10.12659/AJCR.896145. PubMed PMID: 26848804; PubMed Central PMCID: PMC4743678.
- 5 Gogebakan O, Osterhoff MA, Albrecht T. Mesenteric Panniculitis (MP): A Frequent Coincidental CT Finding of Debatable Clinical Significance. *Rofo.* 2018;190:1044-52. doi: 10.1055/a-0633-3558. PubMed PMID: 30189433.
- 6 Wagner C, Dachman A, Ehrenpreis ED. Mesenteric Panniculitis, Sclerosing Mesenteritis and Mesenteric Lipodystrophy: Descriptive Review of a Rare Condition. *Clin Colon Rectal Surg.* 2022;35:342-8. doi: 10.1055/s-0042-1743588. PubMed PMID: 35966977; PubMed Central PMCID: PMC9365492.