

# Exsanguinating Hemorrhage during Open Biopsy in a Primary Breast Angiosarcoma: A Case Report

Majid Akrami<sup>1</sup>, MD;  
Mastoureh Mohammadipour<sup>2</sup>, MD;  
Maral Mokhtari<sup>3</sup>, MD;  
Malihe Dayani<sup>3</sup>, MD

<sup>1</sup>Breast Diseases Research Center, Department of Surgical Oncology, Shiraz University of Medical Sciences, Shiraz, Iran;

<sup>2</sup>Department of Surgery, Shahid Faghihi Hospital, Shiraz University of Medical Sciences, Shiraz, Iran;

<sup>3</sup>Department of Pathology, Nemazee Hospital, Shiraz University of Medical Sciences, Shiraz, Iran

## Correspondence:

Mastoureh Mohammadipour, MD;  
Department of Surgery, Shahid Faghihi Hospital, Zand Blvd., Shiraz, Iran

Tel: +98 71 32331006

Fax: +98 71 32330724

Email: mohammadi\_mst@yahoo.com

Received: 3 February 2014

Revised: 2 March 2014

Accepted: 27 April 2014

## What's Known

- It is known that angiosarcomas are endothelial cell neoplasms in the lining of the blood vessel wall, accounting for about 0.04% of all breast malignancies with a high frequency of error in the primary diagnosis.
- As a breast angiosarcoma is a rare and uncommon pathology, it is mostly described as case reports and only a limited number of cases have been published.

## What's New

- Young women with solid breast tumors that are highly vascular should be considered malignant until proven otherwise.
- Accurate diagnosis may be difficult — even after imaging studies, fine-needle aspiration cytology, and biopsy.
- Open biopsy can be diagnostic, although exsanguination may occur. Thus, it should be performed in well-equipped operating rooms.

## Abstract

Angiosarcomas are endothelial cell neoplasms in the lining of the blood vessel wall and account for about 0.04% of all breast malignancies with a high rate of error in primary diagnosis. The breast angiosarcoma is a rare and uncommon pathology and has been described mostly as case reports. Indeed, only a limited number of cases have been published. Accordingly, the natural history of this tumor and its clinical course remain unclear, and as a consequence, no uniform treatment strategy exists. We present the clinical course and challenges in the diagnosis of a primary angiosarcoma of the breast in a young woman, presenting with a mass in her left breast. Fine-needle aspiration and core needle biopsy failed to confer a correct diagnosis. She suffered severe bleeding at the time of open biopsy and underwent total mastectomy, followed by adjuvant chemotherapy. Young women with solid breast tumors, especially those that are highly vascular, should be considered malignant until proven otherwise. Accurate diagnosis may be difficult. Open biopsy can be diagnostic, although exsanguinating bleeding may occur. Thus, performing open biopsy in locations other than equipped operating rooms may be hazardous and should be avoided.

Please cite this article as: Akrami M, Mohammadipour M, Mokhtari M, Dayani M. Exsanguinating Hemorrhage during Open Biopsy in a Primary Breast Angiosarcoma: A Case Report. *Iran J Med Sci*. 2016;41(2):154-156.

**Keywords** • Breast • Hemangiosarcoma • Hemorrhage • Case report

## Introduction

Angiosarcomas are endothelial cell neoplasms in the lining of the blood vessel wall, with the breast being their favorable site.<sup>1</sup> They may occur as a primary neoplasm (20%) or secondary to radiation therapy after breast conservation.<sup>2,3</sup> Primary angiosarcomas reportedly account for about 0.04% of all breast malignancies (incidence of 17 per million women) with a high rate of error in primary diagnosis.<sup>1,3</sup>

The primary angiosarcoma of the breast is commonly seen in young patients with no history of previous malignancy.<sup>4</sup> Although the type, distribution, and frequency of sarcomas in the breast are the same as those in the other sites of the body, angiosarcomas occur more frequently in the breast than in any other organ.<sup>5</sup> Given the new methods for the preoperative diagnosis of breast lesions (fine-needle aspiration or needle core biopsy), it is vitally important that non-epithelial tumors of the breast be taken into consideration.<sup>5,6</sup> The pathologist may encounter difficulties when there is a possibility of an angiosarcoma because it should be

differentiated from benign vascular proliferations, metaplastic carcinomas, and malignant phyllode tumors.<sup>5</sup>

The prognosis of primary angiosarcomas is much poorer than that of breast carcinomas, with a 56% five-year disease-free survival rate.<sup>7</sup> As the breast angiosarcoma is a rare and uncommon pathology, it is mostly described as case reports and only a limited number of cases have been published. Consequently, the natural history of this tumor and its clinical course remain unclear, and as a result, there is currently no uniform treatment strategy.<sup>3,6</sup>

We herein present the clinical course of a primary angiosarcoma of the breast in a young woman, together with complications during open biopsy. An informed consent was obtained from the patient for this report.

### Case Report

A 24-year-old healthy woman, without a significant medical family history, presented with a lump in the lower inner quadrant of her left breast 24 months prior to her referral to our center. At that time, the mass was diagnosed as a benign lesion after incisional biopsy. She became pregnant and about 1 year after child delivery, the left breast mass grew significantly larger. On clinical suspicion of malignancy with global infiltration of the left breast, she was referred to our center. Mammography showed an asymmetric increased density in the left breast. Multiple-site core needle biopsy was performed, but it led to no definite pathological diagnosis. Consequently, the patient was scheduled for open biopsy. Under general anesthesia, the mass was entered via an incision on the most prominent site. After the removal of a 2×2 cm tissue biopsy, a cavity was opened beneath the excised tissue which was full of blood clot. Following the removal of the clot, active bleeding occurred. Bleeding was diffuse and uncontrollable, such that within a few minutes, the patient lost about 1500 cm<sup>3</sup> of blood. Effective packing was performed. The next day, after the patient had stabilized, she was retransferred to the operating room for the removal of the pack. However, due to severe bleeding after the removal of the pack, packing was reapplied. Chest computed tomography scan revealed a large, well-enhanced mass in the left breast without invasion to the skin or pectoralis muscles and also enlarged left axillary lymph nodes (Figure 1).

According to the final pathology report, histological sections of the mass demonstrated a vascular tumor with interconnecting blood channels lined by atypical, pleomorphic

endothelial cells. Mitotic figures and areas of necrosis were also seen (Figure 2). The tumor cells were immunoreactive for CD31, CD34, and vimentin but not for cytokeratin. The Ki-67 labeling index was about 30%.

As the pathology study of the sample was suggestive of an angiosarcoma, the patient underwent left-side simple mastectomy and then was planned to undergo adjuvant chemotherapy.

### Discussion

Angiosarcomas are rare malignancies of the vascular endothelium and account for 8% of all breast sarcomas.<sup>8</sup> Primary angiosarcomas of the breast usually present with a painless palpable mass, and only 2% may present with diffuse enlargement of the breast.<sup>1</sup> Young patients usually have no known predisposing

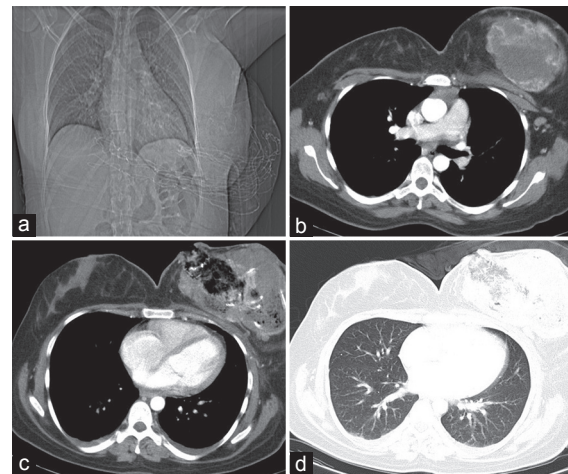


Figure 1: Chest computer tomography scan of the patient shows: (a) Coronal view of an enlarged left breast, (b and c) a huge left breast mass with a bleeding cavity and enlarged left axillary lymph nodes, and (d) no metastatic lesion in the pulmonary window.

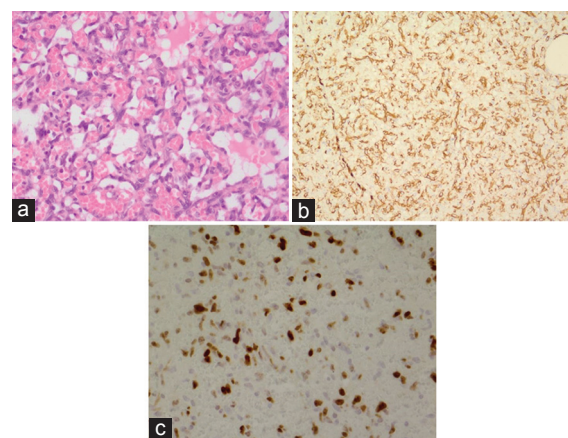


Figure 2: Microscopic appearance of the sample shows: (a) Interconnecting blood vessels lined by atypical endothelial cells and a mitotic figure (arrow), H&E, ×400; (b) immunoreactivity for CD31, ×200; and (c) Ki-67 labeling index, about 30% of tumor cells positive, ×400.

factors (primary angiosarcoma), whilst those in later age have previously received radiotherapy for breast adenocarcinomas (secondary angiosarcoma).<sup>5</sup>

Breast angiosarcomas exhibit no radiographic pathognomonic features and often appear as ill-defined masses (usually coarse) on mammograms without or with calcification.<sup>5</sup> Preoperative diagnosis, via fine-needle-aspiration cytology and biopsy, may prove difficult owing to the differential diagnoses and rarity of the disease, with a false-negative rate of 37%.<sup>2,9</sup> Large-core and open biopsies facilitate the diagnosis but are often difficult to perform due to the high vascularity of these tumors.<sup>10</sup>

As the breast angiosarcoma is very rare, there is no standard treatment. The mainstay of treatment is surgery, which generally consists of a total mastectomy, but axillary lymph node dissection is unnecessary on account of hematogenous dissemination.<sup>5</sup> The role of adjuvant chemotherapy is not well known,<sup>5</sup> but it is suggested as adjuvant treatment to afford the best prognosis, especially in high-grade lesions and metastatic settings. Radiotherapy is not beneficial in primary treatment. Although it appears to decrease the size of the tumor for a transient period, radiotherapy has yet to be proven effective on the survival or metastasis rate. Hormonal modulation may have a role in palliation, but it is not indicated because these tumors do not exhibit estrogen receptors.<sup>3,5</sup> Immunotherapy may also have a role in the treatment of this rare tumor.

We described a young woman presenting with a mass in her left breast. Fine-needle aspiration and core needle biopsy failed to confer a correct diagnosis, and open biopsy caused severe bleeding. The patient was subjected to total mastectomy, followed by adjuvant chemotherapy.

## Conclusion

Young women with solid breast tumors, especially those that are highly vascular, should be considered malignant until proven otherwise. Accurate diagnosis may be difficult, even after imaging studies, fine-needle-aspiration cytology, and biopsy. Open biopsy can be diagnostic; however, it may cause exsanguinating bleeding. Performing open biopsy in locations other than an equipped operating room may, therefore, be hazardous and should be avoided.

**Conflict of Interest:** None declared.

## References

1. Kim YS, Kim YJ, Yim KI, Park WC. A case report of primary breast angiosarcoma with fatal pulmonary hemorrhage due to thrombocytopenia. *J Korean Surg Soc.* 2012;82:251-5. doi: 10.4174/jkss.2012.82.4.251. PubMed PMID: 22493767; PubMed Central PMCID: PMC3319780.
2. Bennani A, Chbani L, Lamchahab M, Wahbi M, Alaoui FF, Badioui I, et al. Primary angiosarcoma of the breast: a case report. *Diagn Pathol.* 2013;8:66. doi: 10.1186/1746-1596-8-66. PubMed PMID: 23607567; PubMed Central PMCID: PMC3651285.
3. Desbiens C, Hogue JC, Levesque Y. Primary breast angiosarcoma: avoiding a common trap. *Case Rep Oncol Med.* 2011;2011:517047. doi: 10.1155/2011/517047. PubMed PMID: 22611503; PubMed Central PMCID: PMC3350177.
4. Johnson CM, Garguilo GA. Angiosarcoma of the breast: A case report and literature review. *Curr Surg.* 2002;59:490-4. doi: 10.1016/S0149-7944(02)00629-3. PubMed PMID: 15727796.
5. Georgiannos SN, Sheaff M. Angiosarcoma of the breast: a 30 year perspective with an optimistic outlook. *Br J Plast Surg.* 2003;56:129-34. doi: 10.1016/S0007-1226(03)00025-0. PubMed PMID: 12791356.
6. Lvoff NM, Leung JW. Case of the season: primary angiosarcoma of the breast: correlative imaging and pathology. *Semin Roentgenol.* 2007;42:208-10. doi: 10.1053/j.ro.2007.06.002. PubMed PMID: 17919522.
7. Vorburger SA, Xing Y, Hunt KK, Lakin GE, Benjamin RS, Feig BW, et al. Angiosarcoma of the breast. *Cancer.* 2005;104:2682-8. doi: 10.1002/cncr.21531. PubMed PMID: 16288486.
9. Zelek L, Llombart-Cussac A, Terrier P, Pivot X, Guinebretiere JM, Le Pechoux C, et al. Prognostic factors in primary breast sarcomas: a series of patients with long-term follow-up. *J Clin Oncol.* 2003;21:2583-8. doi: 10.1200/JCO.2003.06.080. PubMed PMID: 12829679.
10. Cornelis A, Verjans M, Van den Bosch T, Wouters K, Van Robaey J, Janssens JP, et al. Efficacy and safety of direct and frontal macrobiopsies in breast cancer. *Eur J Cancer Prev.* 2009;18:280-4. doi: 10.1097/CEJ.0b013e328329d885. PubMed PMID: 19352188.