



Infancy Urogenital Myiasis: A Case Report

Ehsan Mohammadi¹, MD;  Mohammad Abtahi², PhD; Parham Manouchehri³, MSc; Tahereh Saberi⁴, MSc; Sedigheh Saberi², PhD 

¹Department of Surgery, School of Medicine, Isfahan University of Medical Sciences, Isfahan, Iran;

²Department of Parasitology and Mycology, School of Medicine, Isfahan University of Medical Sciences, Isfahan, Iran;

³Department of Drug Transporter and Permeability, Cyprotex Discovery Ltd. Aldery Edge, Cheshire, England;

⁴Health Center No. 2, Isfahan University of Medical Sciences, Isfahan, Iran

Correspondence:

Sedigheh Saberi, PhD;
Department of Parasitology and Mycology,
School of Medicine, Isfahan University of
Medical Sciences. Hezar Jerib St., Postal
code: 81746-73461, Isfahan, Iran
Tel: +98 31 37929018

Email: sedisaberi@yahoo.com
sedisaberi@med.mui.ac.ir

Received: 03 April 2024

Revised: 19 May 2024

Accepted: 20 June 2024

Abstract

Myiasis is a parasitic infestation of fly larvae caused by dipterous larvae that live in the host's dead or living tissues. This study reported the first case of urogenital myiasis in infants from Iran caused by *Lucilia sericata*. The 10-month-old boy was taken to the hospital by his mother due to restlessness and abdominal pain. During the examination, motile and live larvae were observed in the penis area. The patient had no history of infectious disease or immune system deficiency, and his blood tests were normal. The entomological analysis found that the source of this myiasis was *Lucilia sericata* fly larvae.

The report of such cases highlighted the importance of physical examination and the awareness of physicians in dealing with myiasis, as well as the necessity of educating mothers on the hygiene of the living environment and child care in rural areas.

Please cite this article as: Mohammadi E, Abtahi M, Manouchehri P, Saberi T, Saberi S. Infancy Urogenital Myiasis: A Case Report. Iran J Med Sci. 2024;49(9):604-607. doi: 10.30476/ijms.2024.102202.3497.

Keywords • Myiasis • *Lucilia* • Urogenital • Calliphoridae • Infancy

What's Known

- Myiasis is primarily found in rural areas and is associated with poor hygienic conditions. There are very few cases of urogenital myiasis in children. Thus, any report can be unique and informative. Early referral of the patient to the hospital, as well as the physician's attention in examining the patient and making an accurate diagnosis, can help to reduce subsequent complications of myiasis.

What's New

- The present study reported the first case of urogenital myiasis in infants from Isfahan, Iran, which was caused by blowfly larvae (*Lucilia sericata*). The 10-month-old boy was taken to the hospital by his mother due to restlessness and abdominal pain. In the examination, motile and live larvae were observed in the penis area.

Introduction

Myiasis is a parasitic infestation with a fly larva that is caused by dipterous larvae and lives in the host's dead or living tissues. Flies are typically attracted to open wounds and areas of the body stained with urine or feces. However, some species, especially flies such as the botfly, blowfly, and screw fly can even attack and infest intact skin. This disease is frequent in rural areas; nonetheless, its genital variety is rare.¹ Myiasis is classified into three groups: obligatory or exclusive, optional or semi-exclusive, and random. Except for the skin, it can affect other organs such as the digestive system or the genitourinary system.² Adult *L. sericata* flies are metallic green or copper green in color, 8-10 mm in diameter, with hair on the back and hairless squama wings.

The developmental stage of *Lucilia* was reported 10-23 days, with the eggs converting into a conical larva with posterior respiratory spiracles in 8-12 hours. After developing in 4 to 8 days, the larvae fall to the soil and turn into adult flies 6 to 14 days later.³ Myiasis caused by *L. sericata* in humans was first reported in 1826 by Meigen. He isolated parasites from a patient's mouth, eyes, and paranasal sinuses.⁴ Since then, numerous cases of human myiasis have been reported due to *Lucilia* infestation, including skin tumors, nosocomial, wound, auricular, and tracheostomy wounds.⁵ Currently, basic information on the prevalence of myiasis is limited and scattered. In several societies, urogenital myiasis is overlooked as a disease and may not be properly diagnosed. Since no specific symptoms are known to be associated with this infection, it is important to report

cases to raise awareness of the healthcare staff and assist with medical diagnosis. According to a review study conducted in Iran until 2017, 81 cases of myiasis were reported in Iran in two age groups of 21 to 40 years and 65 years, with only a few cases of urinary-genital myiasis caused by vectors such as *Chrysomya bezziana* and *Wohlfahrtia magnifica*.

Another study found five cases of genitourinary myiasis, which were investigated between 1975 and 2017, related to Iran, and involved adults over the age of 18.^{6,7} Therefore, cases of urogenital myiasis in children are very few, and its report could be unique and valuable, especially in Iran, where urogenital myiasis in infants has not previously been reported. In this way, this is the first case report of myiasis in infants caused by blowfly larvae (*L. sericata*). This study aimed to investigate and identify the source of myiasis in this infected infant.

Case Presentation

The patient was a 10-month-old baby boy who lived in a rural area in Isfahan. His mother brought him to the Hazrat Rasool Akram Hospital in Fereydunshahr (Isfahan, Iran), with a complaint of restlessness and abdominal pain. During the physical and genital examination, the prepuce was somewhat red. He was carefully examined and extensively investigated. During the examination of the patient and the history taken from his mother, no history of any specific infectious disease was found in the child. In the penile examination, when the prepuce was pulled down, numerous alive and motile larvae were observed. The circumcision procedure was performed in the operating room. Following the entire removal of the larvae, the area was cleansed with a sterile

0.9% sodium chloride solution (Iranian Parenteral and Pharmaceutical Co., Iran) and povidone-iodine (Behsadin, CO., Iran) (figure 1).

There was no inflammation in the anus examination as well as other parts of the body. A complete urinalysis, complete blood count, and biochemical values were requested for the child. There was no history or signs of defects in the immune system. The urine and blood tests were normal in the first and second visits, which were checked 48 hours later, and the child was restored and calm, with no specific problem.

Some larvae were sent for identification to the Department of Parasitology and Mycology, School of Medicine of Isfahan University of Medical Sciences. Entomological studies were conducted on the collected live larvae. They were third instars, white or yellowish, conical-shaped, and had a complete peritreme on their posterior spiracles, which appeared as eyeballs and measured about 14 mm in length before pupation (figure 2A). In appropriate conditions (temperature 27 °C, humidity 80%, and 12:12 light-dark period) the larvae developed into pupae and finally into adult flies (figure 2B). After observing the morphological characteristics of the larvae and the fly and using the morphologic identification key, the isolate was detected as *L. sericata* (figure 2).⁸ The adult fly is identified by the presence of three bristles on the dorsal mesothorax. This body region is found in the middle of the fly's back. The identification between *L. sericata* and *Lucilia cuprina* (*L. cuprina*), its sister species, requires microscopic examination to detect two major differentiating characteristics. In this respect, the femoral joint in the first pair of legs in *L. cuprina* has a metallic green color, while in *L. sericata* it is blue-black. Furthermore, in

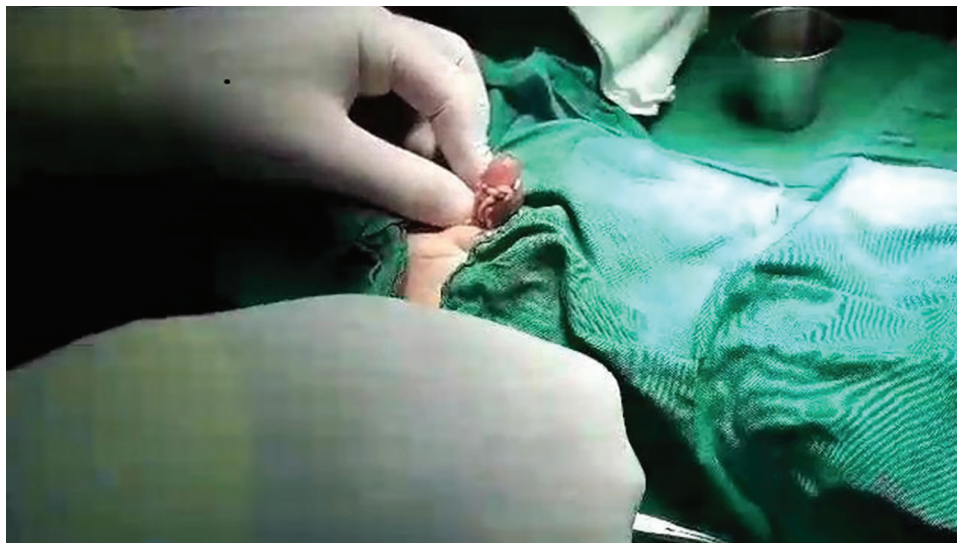


Figure 1: Circumcision was performed for the infant. By removing the foreskin, live larvae were clearly seen in the penis area.

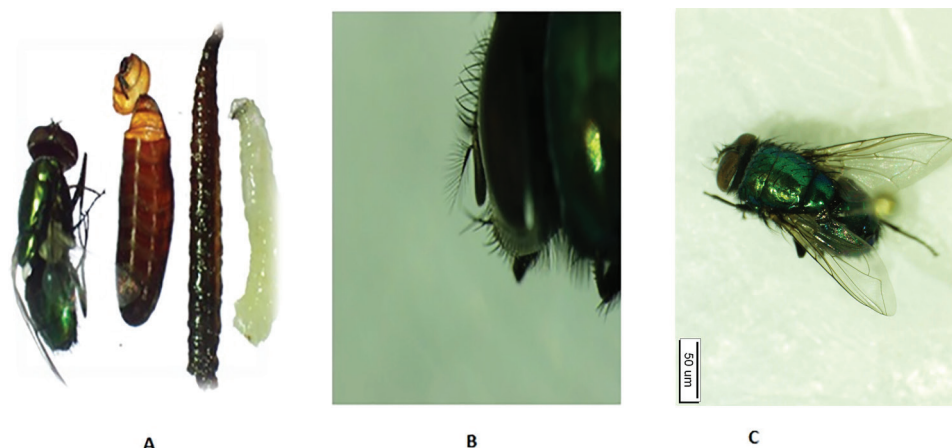


Figure 2: A: The four stages of transformation of isolated larvae into adult flies are shown in figure A. The larvae were first transformed into pupae and then into adult flies. B: The head area in an adult fly, the arista, and its hair pattern are shown in figure B. C: According to the color of the body and the key characteristics of the head area of the whole fly, *Lucilia sericata* was diagnosed.

the microscopic view of the occipital setae, unlike *L. sericata* which has one to nine bristles on each side, *L. cuprina* has three or fewer.^{4, 8} Photographs of larval to adult fly stages were taken using a zoom stereo microscope (SZM-900LCD, LABEX, China). Written informed consent was obtained from the child's parents for the publication of this case report and any accompanying image. The present study was approved by Isfahan University of Medical Sciences (Isfahan, Iran), code: IR.ARI.MUI.REC.1402.108.

Discussion

Myiasis is primarily found in rural areas and is associated with poor hygienic conditions. Iran is located in subtropical regions, and myiasis-causing flies in the Caliphoridae family are prevalent, particularly in villages where the main occupation of the residents is animal husbandry and agriculture, which can expose them to contaminated body tissues with their larvae. Urogenital myiasis occurs due to the deposition of fly larvae in the genitourinary system, which occurs rarely as the disease affects exposed areas of the body. In the present case, the child lived in a rural area near a livestock farm. Besides, probably due to not wearing proper clothes, the genital area was wet and contaminated with urine, attracting female flies to lay eggs in the child's penis. Then, the larvae migrated into the prepuce to feed and induce early signs of disease in the subcutaneous area. The entomological study in the present case report indicated that *Lucilia sericata* was the responsible species. *L. sericata* female lays her eggs in meat, fish, and animal corpses, as well as infected wounds of humans or animals, and

excrement, and the larvae feed on decomposing tissue. The most reported responsible species for urogenital cases include *Fannia scalaris*, *Chryzomya bezziana*, and *Sarcophaga* spp.^{9, 10} Some of this type of myiasis was reported in Brazil by *Dermatobia hominis*, in Turkey by *Psychoda albipennis*, in India by *Chryzomya bezziana*, and also from Spain by *Eristalis tenax*.¹¹ In Iran, two cases of human urogenital myiasis caused by *Chryzomya bezziana* and another by *Lucilia sericata* together with *Wohlfahrtia magnifica* were reported.¹² Based on the conducted studies, three main approaches for myiasis control were mentioned: preventing contact with potential hosts and myiasis flies, early treatment, and reducing or eliminating the population of myiasis flies.¹³ The treatment for urogenital myiasis varies depending on the location of contamination and the severity of symptoms in urogenital myiasis. It might include the mechanical removal of larvae in case of access, drinking plenty of fluids to help wash the ducts, urinary tract disinfectants, and the use of appropriate antibiotics if the symptoms of the disease are severe.¹² In this case report, after cleaning the area from larvae, the infected area was cleansed and disinfected with a sterile 0.9% sodium chloride solution and povidone-iodine. Fortunately, no inflammation, infection, or tissue damage was observed in the first and subsequent visits. Since myiasis is one of the most neglected diseases, and the sufferers, particularly those with urogenital myiasis, might not seek medical attention, residents, particularly mothers, should be trained in child care, living environment health, and prevention and early referral strategies. In addition, medical, nursing, and health care students should be properly educated about the prevalence of myiasis, its

types, causative factors, disease symptoms, careful examination of the patient, and consultation with an entomologist when dealing with myiasis. Moreover, it is recommended to report the cases and their significance in the monthly or periodicals to train physicians and specialists.

Conclusion

The urogenital myiasis in the present case was caused by poor environmental health conditions and negligence in child care, which indicated the necessity of knowledge of residents and mothers in maintaining hygiene and cleanliness in rural areas, especially near livestock with a large population of flies. Clinicians should pay close attention to the symptoms of the disease and the likelihood of myiasis in rural areas. Urogenital myiasis in infants has not been previously reported in Iran, and this is the first case of myiasis in infants caused by blowfly larvae (*L. sericata*) in Iran.

Authors' Contribution

E.M: Conceptualization, Surgeon who referred the patient, scientific consultant, methodology, Investigation; M.A: Entomological studies and participation in final diagnosis, conceptualization, and design, Methodology, Investigation; P.M: Conceptualization, supervision, Investigation, Resources; T.S: Conceptualization, supervision, Investigation; S.S: Conceptualization and design, Methodology, Investigation, Supervision. All authors involved in drafting the work or reviewing the manuscript, and final approval of the version to be published, and agreed to be accountable for all aspects of the work in ensuring that questions related to the accuracy or integrity of any part of the work are appropriately investigated and resolved.

Conflict of Interest: None declared.

References

- Smith KG. A manual of forensic entomology. London: British Museum; 1986. 205p
- Kettle DS. Medical and veterinary entomology. London: Croom Helm Ltd; 1984.
- Holloway BA. Morphological characters to identify adult *Lucilia sericata* (Meigen, 1826) and *L. cuprina* (Wiedemann, 1830) (Diptera: Calliphoridae). New Zealand Journal of Zoology. 1991;18:413-20. doi: 10.1080/03014223.1991.10422847.
- Daniel M, Sramova H, Zalabska E. *Lucilia sericata* (Diptera: Calliphoridae) causing hospital-acquired myiasis of a traumatic wound. J Hosp Infect. 1994;28:149-52. doi: 10.1016/0195-6701(94)90141-4. PubMed PMID: 7844348.
- Martinez-Rojano H, Huerta H, Hernandez-Triana LM, Ruiz Perez EF, Samano R. Nosocomial Myiasis Caused by *Lucilia sericata* (Diptera: Calliphoridae) in a Pediatric Patient in Mexico. Case Rep Infect Dis. 2020;2020:1285459. doi: 10.1155/2020/1285459. PubMed PMID: 32082658; PubMed Central PMCID: PMC7008277.
- Hazratian T, Dolatkah A, Akbarzadeh K, Khosravi M, Ghasemikhah R. A Review of Human Myiasis in Iran With an Emphasis on Reported Cases. Malaysian Journal of Medicine & Health Sciences. 2020;16.
- Faridnia R, Soosaraei M, Kalani H, Fakhari M, Jokelainen P, Zolfaghari Emameh R, et al. Human urogenital myiasis: A systematic review of reported cases from 1975 to 2017. Eur J Obstet Gynecol Reprod Biol. 2019;235:57-61. doi: 10.1016/j.ejogrb.2019.02.008. PubMed PMID: 30784828.
- Jones N, Whitworth T, Marshall S. Blow flies of North America: Keys to the subfamilies and genera of Calliphoridae, and to the species of the subfamilies Calliphorinae, Luciliinae and Chrysomyinae. Canadian Journal of Arthropod Identification. 2019.
- Sher A, Latif SA. First case of nosocomial nasal myiasis caused by *Chrysomya bezziana* in Kuwait. Open Access Library Journal. 2022;9:1-5. doi: 10.4236/oalib.1109256.
- Martins LGV, Barbosa TM, Gama RA. Myiasis in humans: Case reports in Northeastern Brazil including multispecies co-infestation by Sarcophagidae. Parasitol Int. 2021;85:102436. doi: 10.1016/j.parint.2021.102436. PubMed PMID: 34389491.
- Francesconi F, Lupi O. Myiasis. Clin Microbiol Rev. 2012;25:79-105. doi: 10.1128/CMR.00010-11. PubMed PMID: 22232372; PubMed Central PMCID: PMC3255963.
- Salimi M, Goodarzi D, Karimfar M, Edalat H. Human Urogenital Myiasis Caused by *Lucilia sericata* (Diptera: Calliphoridae) and *Wohlfahrtia magnifica* (Diptera: Sarcophagidae) in Markazi Province of Iran. Iran J Arthropod Borne Dis. 2010;4:72-6. PubMed PMID: 22808392; PubMed Central PMCID: PMC3385545.
- Mullen GR, Durden LA. Medical and veterinary entomology. Cambridge: Academic press; 2009.