

Periodontal Pockets as a Potential Source of Infection: a Case of Possible Odontogenic Septic Pulmonary Embolism

S.Gh.R. Mortazavimoghaddam

Abstract

Although dental foci can be sources of bacteremia and bacterial endocarditis, hematogenous spread of infection presented with septic pulmonary embolism apparently is rare. The occurrence of septic pulmonary embolism in patients with periodontal disease without suppurative thrombophlebitis of the great vessels of the neck is well documented but to our knowledge, there is no report on septic pulmonary embolism in immunocompetent patients following root canal treatment. Here in we present a 42-year-old man who referred to our hospital because of fever, left sided pleuritic chest pain, and scanty productive cough. Chest radiography and computed tomography revealed multiple nodular shadows with features characteristic of septic pulmonary embolism. His medical history revealed dental care clinic visit and root canal treatment 2 weeks earlier. In the present case, the results of extensive investigations were negative for other potential causes of septic pulmonary embolism and dental pocket was considered to be the only possible source for the disease.

Iran J Med Sci 2008; 33(3): 183-186.

Keywords • Periodontal pocket • pulmonary nodules • dental root canal • pulmonary embolisms

Introduction

Sepic pulmonary embolism (SPE) is a serious and rare disease. It is a well-recognized potential problem in the settings of tricuspid valve endocarditis, septic thrombophlebitis, infected central venous catheters, and postanginal septicemia.¹⁻⁵ Other rare causes of SPE are urinary tract infection,^{6,7} and undetermined origin.⁸ Although the occurrence of SPE in patients with periodontal disease without suppurative thrombophlebitis of the great vessels of the neck is well documented,⁹⁻¹⁵ to our knowledge, there is no report on SPE in immunocompetent subjects following root canal treatment. The purpose of the present report was to define the clinical and radiological features in a patient with SPE secondary to root canal treatment and to identify the features that may facilitate the recognition, prevention, and diagnosis of this uncommon disorder.

Case Presentation

A 42-year-old, non-smoker, non-addicted man presented to our hospital because of chills, fever, and left-sided chest pain. Mild cough and scanty sputum production were also evident. At the time of hospital admission, no abnormal physical findings

Department of Internal Medicine,
Birjand University of Medical Sciences,
Birjand, Iran.

Correspondence:

Sayed Gholamreza
Mortazavimoghaddam MD,
Department of Internal Medicine,
Birjand University of Medical Sciences,
Birjand, Iran.

Tel/Fax: +98 561 4435633

Email: gmortazavi@yahoo.com

Submitted: 9 September 2007

Revised: 11 June 2008

Accepted: 26 June 2008

were noted in the neck, abdomen or extremities. Lung auscultation disclosed decreased breath sound on the left lung base. Examination of the heart was normal. A chest radiograph showed multiple small pulmonary infiltrates in both lungs more prominent in the base of the left lung (figure 1). Chest computed tomography (CT) showed multiple scattered nodular lesions, most located subpleurally and measuring approximately 2-3 cm in diameter, in both lungs fields (figure 2). A necrotic center was seen in nodules compatible with SPE. Initial laboratory results revealed white blood cell count: 12600/ μ l, hemoglobin: 10 mg/dl, blood urea nitrogen (BUN): 23 mg/dl, creatinine: 1.2 mg/dl, Platelet count: 223/ μ l, 1h erythrocyte sedimentation rate (ESR): 123, positive C-reactive protein, and normal urine analysis. Cytoplasmic antineutrophilic cytoplasmic antibody (C-ANCA) was negative. Sputum culture yielded normal flora and was negative for tuberculosis. Tuberculin skin test was negative. Abdominal ultrasonography and transthoracic echocardiogram showed no abnormalities. No infectious source was present except a history of dental care and root canal treatment in the previous month. At the time of admission, there was no evidence of gum infection or dental abscess. The dental surgeon reported that the second left upper premolar dental root decay was cleaned and filled with gutta percha and a permanent filling was placed at the teeth. The first premolar root canal was bifurcated without abnormalities. He also reported gingiva was intact at the time of operation.

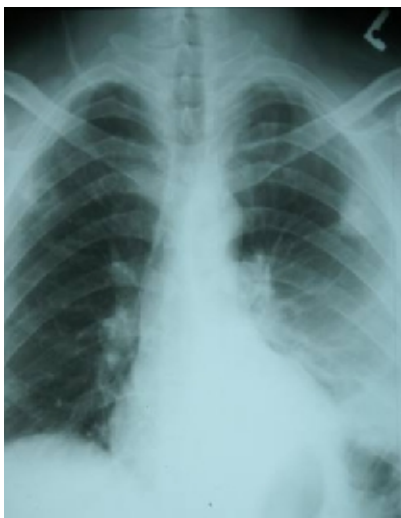

Figure 1: Chest radiograph (before treatment). A pulmonary infiltrates on the base of the left lung, a peripheral not cavitated left lung nodule and a peripheral cavitated right lung nodule.

Because the results of investigations aimed to identify the possible sources of infection were negative, a diagnosis of odontogenic septic

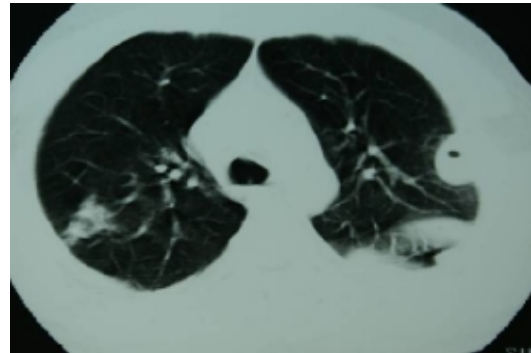


Figure 2: Chest CT scan. Nodules located subpleurally measuring approximately 2-3 cm in diameter with central necrosis on both sides. Necrotic center in nodules is compatible with septic embolism.

pulmonary embolism was made and pulmonary lesions were treated successfully with antimicrobial agents (two weeks parental clindamycin and Ceftriaxone followed by 6 weeks oral cefixime and clindamycine). The patient was improved and the lung lesions were disappeared (figure 3).

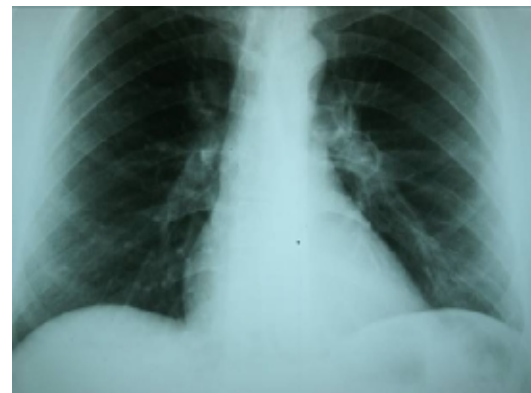

Figure 3: Chest radiograph (after treatment). Infiltration and nodules are cleared.

Discussion

The case reported here showed mild cough and scanty sputum production at initial presentation, arguing against the acquisition of infection via the respiratory tract. Chest pain or back pain presumably related to pleural inflammation. Chest CT is very useful in the diagnosis of septic pulmonary embolism.¹⁶ In our case, findings of chest CT were consistent with septic pulmonary embolism. It was not possible to perform a transesophageal echocardiography (TEE) as the golden standard tool for ruling out infective endocarditis (a potential source of septic pulmonary embolism). However, the examination of heart and transthoracic echocardiography were normal and the patient had no history of intravenous drug abuse, as a major risk factor for endocarditis.

The interesting comment in our case was that there was no evidence of any sources for

SPE and the only possible source was considered to be dental root after root canal treatment. Jaffe and Koschmann,¹⁷ reported that most cases of septic pulmonary emboli originated from right-sided bacterial endocarditic or septic thrombophlebitis from sources such as the tonsil, the jugular region, pelvic infection, or infected indwelling catheters. Although dental foci can be a source of bacteremia and bacterial endocarditis,¹⁰ hematogenous spread of infection to lung apparently is rare in periodontal disease.¹¹ A review of literature found that clinical picture of septic pulmonary embolism was associated with periodontal disease. Christensen et al,¹¹ reported a 56-year-old man who developed cough, sputum, fever, and pleuritic chest pain three weeks following a toothache. He had mild periodontal disease and his chest radiographs and chest CT scans showed multiple pulmonary nodules. Aspirated pus from one of the nodules yielded pure growth of streptococcus intermedius. The lesions resolved with antimicrobial treatment. Shiota et al,¹⁴ reported two cases (a 53-year-old and a 67-year-old patients) of septic pulmonary embolism associated with periodontitis. Both patients were men and one of them had a 10-year history of bronchial asthma treated with 5 mg/d oral prednisolone. Repeated blood culture findings were negative. None of the patients showed cough or sputum production at initial presentation. Both patients had chest pain or back pain. In both cases, chest CT was very useful in the diagnosis of septic pulmonary embolism.

In a report by Russi et al,¹² a man in whom hereditary hemorrhagic telangiectasia and gingival arteriovenous malformations had been diagnosed was visited because of multiple episodes of fever and chills due to septic pulmonary emboli. Since no other infectious embolic sources were found and the patient's pulmonary infection was not extirpated by a prolonged course of antibiotics, Russi et al speculated that gingival arteriovenous malformations being involved by periodontitis were the source of small septic emboli.

Mattar et al,¹⁵ reported a 55-year-old man with renal transplant from living relative 20 years prior to presentation, who experienced recurrent shortness of breath, left-sided pleuritic chest pain, and night sweats for 3 months. The patient denied fevers, chills, and rigors. His immunosuppressive regimen consisted of azathioprine (50 mg orally per day) and prednisone (5 mg orally per day). He smoked one pack of cigarettes per day. On review of systems, he stated pain in his oral cavity. The patient's oral temperature was 98.4° F. He had multiple dental caries as well as gingivitis but an oral abscess could not be identified. His chest radiography documented a 3.4×3.9 cm

sub pleural mass in the left lower lobe. CT of the chest was performed to better delineate this lesion. Several smaller nodular densities were apparent in the periphery of both lungs. Due to concerns that these lesions represented septic emboli, antibiotic therapy was initiated. Because the patient was hemodynamically stable, he was treated as an outpatient with oral ampicillin-clavulanate (875/125 mg) twice a day for 6 weeks.

In the review of the related literature, all reported cases, as our presented case, were male and in middle age. Two of the patients were immunosuppressed. Interestingly, none of the patients were reported to be seriously ill or toxic. None of the patients with SPE originated from periodontal disease had positive blood cultures.

This is in contrast with patients who experienced septic emboli from endocarditis, septic thrombophlebitis, and postanginal septicemia, where blood cultures grow the causative organism in more than 90% of cases. None of the published cases of SPE from periodontitis was in a nosocomial situation. Although the chest radiographic appearance of SPE is non-specific, in the appropriate clinical setting, the diagnosis can be suggested. Multiple wedge-shaped peripheral nodules abutting the pleura with cavitation should raise the suspicion of embolic lesions.¹⁶ Although no pathogenic bacteria was identified, all reported cases of SPE due to periodontal disease were successfully treated by antimicrobial agents and in the case of hereditary hemorrhagic telangiectasia, the treatment was surgery. The antibiotic treatment duration ranged from 2 to 6 weeks.

In conclusion, in the absence of any other sources of infection and in patients with periodontal disease or dental root manipulation, the dental pockets should be considered a possible source of SPE both in immunocompetent and immunocompromised patients. Empiric antibiotic therapy to cover aerobic and anaerobic oral flora would appear justifiable. In particular, dentists should be aware of this complication.

Conflict of Interest: None declared

References

- 1 Griffith GL, Maull KI, Sachatello CR. Septic pulmonary embolization. *Surg Gynecol Obstet* 1977; 144: 105-8.
- 2 MacMillan JC, Milstein SH, Samson PC. Clinical spectrum of septic pulmonary embolism and infarction. *J Thorac Cardiovasc Surg* 1978; 75: 670-9.
- 3 O'Donnell AE, Selig J, Aravamuthan M, Richardson MS. Pulmonary complications

- associated with illicit drug use: an update. *Chest* 1995; 108: 460-3.
- 4 Taniguchi H, Fujisaka S, Abo H, et al. Pulmonary septic emboli in a patient with right-side infectious endocarditis. *Nihon Kokyuki Gakkai Zasshi* 2003; 41: 666-70.
 - 5 Hanibuchi M, Shimada R, Nishioka Y, et al. A case of septic pulmonary embolism accompanied with tricuspid valve endocarditis and pyogenic spondylitis. *Nihon Kokyuki Gakkai Zasshi* 2003; 41: 365-9.
 - 6 Miyaki J, Souma S, Narumiya Y, Chiba S, Kugiyama K. A case of septic pulmonary embolism showing the rapid appearance of multiple cavities in both lung fields induced by urinary tract infection. *Nihon Kokyuki Gakkai Zasshi* 2006; 44: 879-84.
 - 7 Kiwamoto T, Endo T, Sekizawa K. A case of septic pulmonary embolism induced by urinary tract infection. *Nihon Kokyuki Gakkai Zasshi* 2004; 42: 89-93.
 - 8 Nagafuchi M, Koga T, Taguchi K, et al. A young adult patient with septic pulmonary emboli of undetermined origin. *Kurume Med J* 2006; 53: 99-101.
 - 9 Cook RJ, Ashton RW, Aughenbaugh GL, Ryu JH. Septic pulmonary embolism: presenting features and clinical course of 14 patients. *Chest* 2005; 128: 162-6.
 - 10 Scannapieco FA. Position paper of The American Academy of Periodontology: periodontal disease as a potential risk factor for systemic diseases. *J Periodontol* 1998; 69: 841-50.
 - 11 Christensen PJ, Kutty K, Adlam RT, et al. Septic pulmonary embolism due to periodontal disease. *Chest* 1993; 104:1927-9.
 - 12 Russi EW, Dazzi H, Gäumann N. Septic pulmonary embolism due to periodontal disease in a patient with hereditary hemorrhagic telangiectasia. *Respiration* 1996; 63: 117-9.
 - 13 Sahara S, Yoshida K, Hoshino H, et al. A case of septic pulmonary embolism complicated with dental caries. *Jpn J Chest Dis* 1998; 57: 766-70.
 - 14 Shiota Y, Arikita H, Horita N, et al. Septic Pulmonary Embolism Associated With Periodontal Disease. Reports of Two Cases and Review of the Literature. *Chest* 2002; 121: 652-4.
 - 15 Mattar CS, Keith RL, Byrd RP Jr, Roy TM. Septic pulmonary emboli due to periodontal disease. *Respir Med* 2006; 100: 1470-4.
 - 16 Kuhlmann JE, Fishman EK, Teigen C. Pulmonary septic emboli: diagnosis with CT. *Radiology* 1990; 174: 211-3.
 - 17 Jaffe RB, Koschmann EB. Septic pulmonary emboli. *Radiology* 1970; 96: 527-32.