

# Evaluation of the Efficacy of Topical Ethyl Vanillate in Enhancing the Effect of Narrow Band Ultraviolet B against Vitiligo: A Double Blind Randomized, Placebo-Controlled Clinical Trial

Mohammad Reza Namazi<sup>1,2</sup>, MD;  
Amir Kalafi Shotorbani<sup>1,3</sup>, MD

## Abstract

**Background:** Vitiligo is an acquired disease of skin that presents with depigmented patches due to lack of melanocytes in the epidermis. Accumulation of toxic free radicals like hydrogen peroxide in the epidermis may be responsible for melanocytes death. Since ethyl vanillate (vanillic acid ethyl ester) is a strong hydrogen peroxide scavenger, it may be effective against vitiligo. This study was carried out to evaluate the effect of ethyl vanillate cream on vitiligo patients receiving phototherapy.

**Methods:** A double-blind placebo-controlled clinical trial using ethyl vanillate cream 20% was performed on 30 cases of generalized stable vitiligo (randomly selected) who were receiving phototherapy in the outpatient clinic of Faghihi Hospital (Shiraz, Iran). The patients randomly applied ethyl vanillate on an assigned lesion (left or right side of the body) and placebo on the opposite side lesion (almost the same size and location) twice a day for 3 months, while receiving a narrow band ultraviolet B (NB-UVB) 2-3 times weekly. Photos were taken at the beginning of the trial and at the end of 4<sup>th</sup>, 8<sup>th</sup>, and 12<sup>th</sup> weeks. Then, images were compared with the photos from the beginning of the trial based on VASI score.

**Results:** There was a significant change in pigmentation after applying ethyl vanillate compared with baseline in medication side ( $P=0.002$ ), but no significant change in placebo side ( $P=0.066$ ). Additionally, there was a significant difference between medication and placebo sides in pigmentation ( $P=0.005$ ).

**Conclusion:** Ethyl vanillate may serve as an adjunct therapy for the treatment of vitiligo, although changes in pigmentation are mild clinically.

Please cite this article as: Namazi MR, Kalafi A. Evaluation of the Efficacy of Topical Ethyl Vanillate in Enhancing the Effect of Narrow Band Ultraviolet B against Vitiligo: A Double Blind Randomized, Placebo-Controlled Clinical Trial. *Iran J Med Sci.* 2015;40(6):478-484.

**Keywords** • Vitiligo • Vanillic acid • Phototherapy

<sup>1</sup>Molecular Dermatology Research Center, Department of Dermatology, Shiraz University of Medical Sciences, Shiraz, Iran;

<sup>2</sup>Skin and Stem Cell Research Center, Tehran University of Medical Sciences, Tehran, Iran;

<sup>3</sup>Student Research Committee, Shiraz University of Medical Sciences, Shiraz, Iran

## Correspondence:

Amir Kalafi Shotorbani, MD;  
Department of Dermatology, Faghihi Hospital, Zand Street, Shiraz, Iran

**Tel/Fax:** +98 71 32319049

**Email:** amirkalafi@yahoo.com

Received: 11 November 2013

Revised: 14 January 2014

Accepted: 08 February 2014

## Introduction

Vitiligo is defined as a chronic and progressive destruction of melanocytes in the epidermis that leads to symmetric depigmented macules or patches. Vitiligo is considered as an acquired and multifactorial disease with a prevalence of 0.5-2%. The most common type is the generalized form, which affects more than 20% of body surface area. It usually can have unpredictable

course.<sup>1</sup> There is no sex predilection and at least 30% of cases have a positive family history of vitiligo.<sup>2</sup>

There are multiple pathogenic hypotheses for vitiligo, including the following hypotheses:

1. Melanocyte destruction due to antibodies against their proteins
2. A defect in melanocyte structure, adhesion or survival
3. Lack of proper defense against oxidative stress

Oxidative stress may be the triggering factor for the destruction of melanocytes in the epidermis.

Free radicals like hydrogen peroxide (H<sub>2</sub>O<sub>2</sub>), super oxide, or nitric oxide are produced during different processes, including melanogenesis.<sup>3</sup> These reactive oxygen species inhibit tyrosinase. They are scavenged by superoxide dismutase, catalase, and other antioxidant enzymes. If these free radicals are not scavenged by antioxidants like catalase, they cause cell damage by crossing cell membrane. Catalase, the key enzyme in scavenging free radicals, changes H<sub>2</sub>O<sub>2</sub> to H<sub>2</sub>O and O<sub>2</sub>.<sup>4</sup> There is a low level of catalase and other antioxidants and high levels of H<sub>2</sub>O<sub>2</sub> in the epidermis of vitiliginous lesions.<sup>1,4</sup>

There are high levels of superoxide dismutase enzyme, which converts pro-oxidant superoxide into H<sub>2</sub>O<sub>2</sub> in vitiligo. Hence, there is accumulation of H<sub>2</sub>O<sub>2</sub> in cytoplasm or mitochondrial parts of the cell, which causes damage to melanocytes. The activity of aforementioned enzyme is higher in active vitiligo compared with stable vitiligo.<sup>5</sup>

There are high oxidative stress index and low serum total oxidant status values, based on a study.<sup>6</sup>

High levels of H<sub>2</sub>O<sub>2</sub> and reactive oxygen species inhibit tyrosinase activity (melanogenic) through oxidation of methionine residues.<sup>7</sup> Also, melanocytes in vitiligo patients are more susceptible to damage than normal ones.<sup>8</sup> High levels of H<sub>2</sub>O<sub>2</sub> are cytotoxic to melanocytes and lead to their destruction in the skin.

In summary, imbalance between oxidative and antioxidative processes and excess reactive oxygen species in the active vitiligo skin are thought to be pathogenic events in vitiligo.<sup>9,10</sup> H<sub>2</sub>O<sub>2</sub> leads to increase production of tetrahydrobiopterin.<sup>11</sup>

Vanillin is a flavoring component that is used in beverages, food, and drugs. It has been proved that vanillin has a superoxide anion scavenging ability via testing with 25 mg/ml orally in mice. Vanillic acid is a metabolite of vanillin.<sup>12</sup> Vanillic acid is the most effective H<sub>2</sub>O<sub>2</sub> scavenger. If H<sub>2</sub>O<sub>2</sub> is not scavenged efficiently, it leads to the production of hydroxyl free radicals by

fenton-type reactions.<sup>13</sup> Ethyl vanillate is vanillic acid ethyl ester. It is a white powder and soluble in alcohol and slightly water.<sup>14</sup>

Since narrow band ultraviolet B (NB-UVB) is one of the best modalities in the treatment of generalized vitiligo,<sup>1</sup> vanillic acid scavenges H<sub>2</sub>O<sub>2</sub><sup>13</sup> and there is a high level of H<sub>2</sub>O<sub>2</sub> in vitiliginous epidermis.<sup>4</sup> Thus, we decided to evaluate the efficacy of topical ethyl vanillate 20% cream (vanillic acid ethyl ester) in enhancing the effect of NB-UVB therapy in the treatment of vitiligo in order to lessen total sessions of phototherapy, lessen side effects of it, also to hasten pigmentation of lesions and most importantly strong role for oxidative stress in vitiligo.

## Materials and Methods

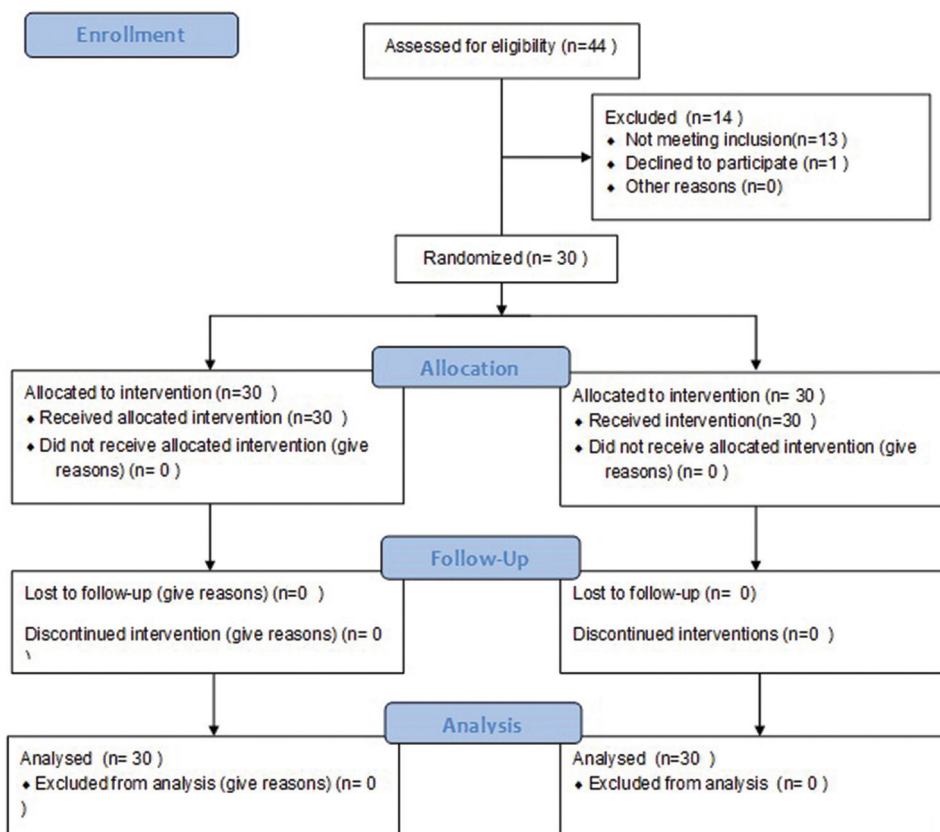
### Patient Selection

This study was a single center, double-blind, randomized, placebo-controlled clinical trial. Among the 44 patients who came to the phototherapy center, only 30 patients (23 females (76.6%) and 7 males (23.4%)) who met the study criteria were included. They served as both cases and controls since the drug was applied on one side while the placebo was applied on the other side of their bodies. The inclusion criteria were generalized (more than 20% of body surface area), and inactive disease (no progression, nor development of new lesions within the last 3 months). The patients were selected randomly by arbitrary selection of patients' phototherapy receipt number. The process of patient selection is shown in Figure 1. The exclusion criteria were pregnant women, children less than 6 years of age, patients with a history of cutaneous malignancy, those who were immunosuppressed, taking or applying any medications for vitiligo within the last 3 months, or those with photosensitive disorders.

### Study Protocol

Informed consent was obtained from each patient. The study was approved by the Ethical Committee of Shiraz Medical University and the proposal was accepted by three faculties of dermatology department. A questionnaire was filled out for each patient regarding associated autoimmune diseases like thyroid problems or diabetes, family history of vitiligo, number of phototherapy sessions prior to study, consumption of any medication, site and pattern of lesions, stability or progression of lesions, and some demographic information.

The patients were selected randomly based on their phototherapy receipt number. A third person assigned number 1 and 2 to both



**Figure 1:** Shows the CONSORT 2010 flow diagram.

creams. Medication was ethyl vanillate 20% cream and placebo was Eucerin (same color as the medication). The selected patients were randomly (by tossing coins) assigned to apply cream 1 on the right side and cream 2 on the left side of the lesion. The next patient applied cream 1 on the left side and cream 2 on the right side twice daily. Two symmetric lesions (nearly the same size and location) were chosen in each patient. Meanwhile, each patient received NB-UVB, 2-3 times a week and patients were assessed in terms of any discomfort or side effect of phototherapy by a physician and the dose was adjusted when necessary. The patients were asked to report any side effect or problem with the medication or phototherapy at will. Our study for each patient lasted 12 weeks. Each patient was visited at the end of the 4<sup>th</sup>, 8<sup>th</sup>, and 12<sup>th</sup> week and evaluated in terms of response to the therapy or any significant side effects. Both the patient and physician were blinded to the treatment and placebo.

**Assessments**

We determined the degree of pigmentation of specified lesions on both sides prior to the study by the Vitiligo Area Severity Index (VASI) score. Photos of the lesions were taken from both sides at the end of the 4<sup>th</sup>, 8<sup>th</sup>, and 12<sup>th</sup> week in addition

to pre-study photos. Then, we compared the photos at the end of the study with baseline, according to VASI score.

VASI score 100%: Depigmentation, 90%: Specks of pigment, 75%: Depigmented areas more than the pigmented areas, 50%: Equal pigmented and depigmented areas, 25%: Pigmented areas more than depigmented area and 10%: Specks of depigmentation. The patients were asked about any adverse effects of medications in each visit. There is no special unit for numbers in VASI score.

**Statistical Methods**

Paired t-test and Wilcoxon signed ranks test were used for statistical analysis (with SPSS 15.0 software). All results were significant if P values were 0.05 or less.

**Results**

**Patient Population**

Thirty cases of generalized vitiligo, aged from 22 to 60 years were enrolled in this study.

They were randomly instructed to apply topical ethyl vanillate 20% cream and placebo (Eucerin) twice daily on the right or left sided specified symmetrical lesions along with 2-3 times a week NB-UVB phototherapy. We chose the sample

size of 30 similar to other studies as mentioned in the discussion section of this article and in consultation with a statistician ( $\alpha=0.05$ , power=80%). All patients completed the 12-week study. Test sites are mentioned in Table 1.

**Treatment Efficacy**

Of the 30 patients, there were 76.6% (23) female and 23.4% (7) male. 16.6% of cases had positive family history of vitiligo, 3.3% were hypothyroid, and 6.6% had diabetes. Pigmentation of lesions based on VASI (before and at the end of the trial), mean scores of pigmentation on both sides based on VASI, and the difference between both sides are shown Tables 2-4, respectively. The final results at the end of the 12<sup>th</sup> week are shown to demonstrate the maximum effect. Lower pigmentation

numbers indicate more repigmentation and higher numbers show more depigmentation.

In summary, 36.6% of lesions which were treated with ethyl vanillate showed a change in pigmentation (mostly mild clinically) compared with 13.3% in placebo side. There were no changes in other cases on both sides compared with baseline. Figures 2 and 3 shows both sides of a patient (medication and placebo) before (a) and after (b) the trial.

**Safety and Tolerability**

Both ethyl vanillate and placebo were tolerated with a few transient burning and stinging as reported by some patients. No serious problem was observed with NB-UVB phototherapy.

**Discussion**

We sought to evaluate whether topical ethyl vanillate would enhance NB-UVB efficacy in the treatment of vitiligo.

**Table 1:** Sites (symmetrical) selected for test

Elbow 5	Ankle 1	Wrist 6	Arm 1	Hand 4
Forearm 6	Chest 1	Leg 3	Knee 2	Finger 1

**Table 2:** Pigmentation of lesions based on VASI (baseline, end of trial)

Patient no	Pig (VASI) before med	Pig (VASI) before placebo	VASI 12 <sup>th</sup> Med	VASI 12 <sup>th</sup> placebo	Phototherapy sessions before study	Site of lesion
1	100	100	100	100	30	Wrist
2	90	75	75	75	16	Elbow
3	90	100	90	100	64	Wrist
4	50	50	50	50	42	Forearm
5	100	100	100	100	38	Forearm
6	90	90	90	90	15	Leg
7	100	75	50	50	24	Leg
8	75	90	50	75	17	Arm
9	100	100	90	100	60	Wrist
10	75	100	75	100	20	Forearm
11	100	100	90	100	38	Knee
12	100	100	90	100	58	Chest
13	100	100	90	100	21	Wrist
14	100	100	90	100	37	Hand
15	75	75	50	50	150	Forearm
16	100	90	90	90	20	Forearm
17	90	90	90	90	119	Ankle
18	75	75	75	75	23	Elbow
19	100	100	100	100	65	Wrist
20	100	100	100	100	10	Finger
21	100	100	100	100	10	Elbow
22	100	75	90	75	104	Hand
23	90	90	90	90	100	Wrist
24	75	75	75	75	82	Hand
25	100	100	100	100	10	Hand
26	100	100	100	100	8	Elbow
27	100	100	100	100	1	Elbow
28	50	50	50	50	170	Elbow
29	100	100	100	90	24	Leg
30	90	100	75	100	18	Forearm

**Table 3:** Mean scores of pigmentation based on VASI (medication and placebo sides)

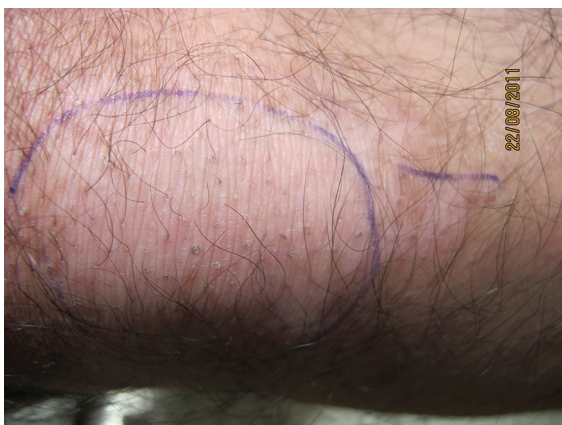Indices	Mean±SD pigmentation	N
Before med	90.50±14.40	30
After med	83.83±17.50	30
Before placebo	90.00±14.68	30
After placebo	87.50±17.55	30

There was a significant change after applying ethyl vanillate compared with baseline (P=0.002) on medication side, but no significant change in placebo side (before and after placebo) (P=0.066)

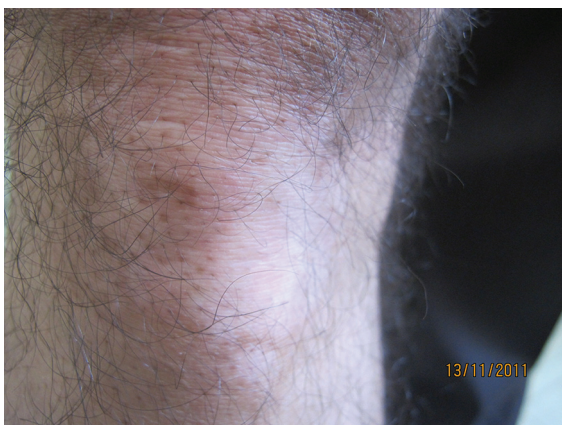**Table 4:** Difference in mean pigmentation between medication and placebo sides

Indices	Diff mean±SD pigmentation	P value
Med side	6.66±11.09	0.002
Placebo side	2.50±6.91	0.066

There was a significant difference between medication and placebo sides (P=0.005)

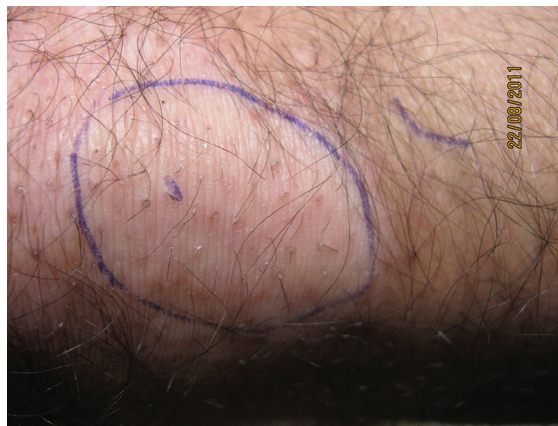

**Figure 2a:** Pigmentary changes on the knee before ethyl vanillate (VASI=100) are seen.

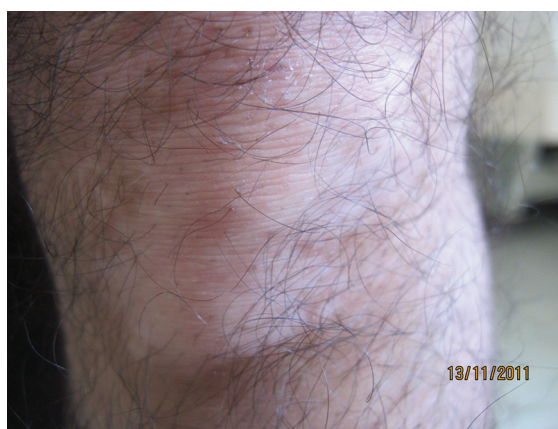

**Figure 2b:** Pigmentary changes on the knee after ethyl vanillate (VASI=90) are seen.

This double-blinded randomized clinical trial indicated that ethyl vanillate, as an antioxidant agent, can improve repigmentation and enhance the efficacy of NB-UVB in vitiligo patients. However, such increase in pigmentation is not



**Figure 3a:** Pigmentary changes on the knee before the placebo (VASI=100) are seen.



**Figure 3b:** Pigmentary changes on the knee after the placebo (VASI=100) are seen.

marked or excellent clinically. Ethyl vanillate was not tested in higher concentrations as we were not sure if patients could tolerate the medication or what the side effects would have been.

Similar to other studies, we chose to evaluate patients for 12 weeks. This was in-line with studies on tacrolimus ointment or vitamin D ointment with NB-UVB for 3 months in vitiligo patients.<sup>15</sup> Notably, the selection of such duration was based on a textbook; where at least 2-3 months were required to evaluate the effectiveness of vitiligo treatment.<sup>1</sup>

Based on a review of non-surgical treatments for vitiligo, oral antioxidants were useful in the management of vitiligo, but there were no long-term follow up in most studies and the sample size was limited.<sup>16</sup>

Some researches were done on the role of antioxidants in the treatment of vitiligo. For instance, Elgoweini et al.<sup>17</sup> evaluated vitamin E along with NB-UVB against vitiligo on 24 patients. This study showed that vitamin E, as an antioxidant, could increase the efficacy of NB-UVB and induces good repigmentation

(72.7% in the treatment group vs. 55.6% in the placebo group).

In another double-blind placebo controlled clinical trial on 35 patients by Dell Anna et al.,<sup>18</sup> antioxidants such as alpha-lipoic acid, vitamins C and E were given to a treatment group before and during NB-UVB therapy. Results showed greater repigmentation of 47% in the treatment group versus 18% in the placebo group.

Contrary to the above researches, in a study by Jayanth et al.<sup>9</sup> on 30 stable vitiligo patients (not on any treatment for 1 month), the treatment group received oral antioxidants with photochemotherapy while the placebo group received only photochemotherapy for 3 months. There were no significant differences between the groups.

Other studies compared betamethasone ointment with topical catalase/superoxide dismutase (which are deficient in vitiligo) on 25 vitiligo patients. Photos were taken and compared for both sides. No statistical difference ( $P=0.758$ ) on the percentage of pigmentation was observed between the two sides (similar lesions) at 4 months. In this study, the authors suggested a stronger role for oxidative stress.<sup>19</sup> Topical catalase/superoxide dismutase combined with NB-UVB were evaluated on 15 vitiligo patients versus 15 patients only on NB-UVB as the control group. The patients applied the cream for 6 months. No significant changes between the groups ( $P>0.05$ ) were observed. The authors recommended larger studies to be carried out.<sup>20</sup>

Another study compared pseudocatalase cream with NB-UVB versus placebo and NB-UVB on 32 vitiligo patients for 24 weeks. No statistically significant difference between the groups was reported, but significant improvement was seen in each group by week 12 and was stable until the end of the study. It was concluded that pseudocatalase cream does not enhance the efficacy of phototherapy.<sup>21</sup>

In conclusion, some studies are in favor of antioxidants, but others are inconclusive.

Recently, a topical gel including phenylalanine, cucumis melo extract and acetyl cysteine was tested on vitiligo patients who were on phototherapy. Topical gel was applied for 12 weeks. This study showed that the gel was effective and improved repigmentation.<sup>22</sup>

The limitations of our study were possibly a low concentration of ethyl vanillate, the selection of some resistant to therapy sites (e.g. the hands) and poor compliance of some patients.

## Conclusion

This study showed that ethyl vanillate could be used as an adjunct modality to NB-UVB or

possibly other modalities in the treatment of vitiligo. Therefore, it can reduce the need for phototherapy by improving repigmentation. However, most patients may not notice small changes in pigmentation of lesions.

Since this study, using ethyl vanillate, was done for the first time (based on the important role of H<sub>2</sub>O<sub>2</sub> in damaging melanocytes and efficient scavenging ability of vanillic acid), lower concentrations of ethyl vanillate was used. However, it is recommended that higher concentrations in larger studies be used in the future in order to achieve better repigmentation. Since patients cannot receive long-term phototherapy or other therapies like steroids due to adverse side effects, and stronger role for oxidative stress in the pathogenesis of vitiligo according to many studies, adjunct therapies like newer antioxidant modalities, might help accelerating repigmentation and be used as maintenance therapy.

## Acknowledgment

The present article was extracted from the thesis by Amir Kalafi Shotorbani and was financially supported by Shiraz University of Medical Sciences, grant NO.90-01-01-3321. IRCT registration number IRCT201107317160N1.

**Conflict of interest:** None declared.

## References

- Ortonne J, Passeron TH. Vitiligo and other disorders of hypopigmentation. In: Bolognia J, Jorrizo JL, Rapini R, editors. *Dermatology*. China: Elsevier; 2012. p. 1023-9.
- Habif TP. *Clinical Dermatology: A Color Guide to Diagnosis and Therapy*. 5<sup>th</sup> ed. China: Mosby; 2010.
- Kamel N, Sobhy N, Kamal H, Ismail M. A comparative study of oxidant- antioxidant status in blood and tissue in vitiligo patients. *Egyptian Dermatology Online Journal*. 2010;6:1-10.
- Sravani PV, Babu NK, Gopal KV, Rao GR, Rao AR, Moorthy B, et al. Determination of oxidative stress in vitiligo by measuring superoxide dismutase and catalase levels in vitiliginous and non-vitiliginous skin. *Indian J Dermatol Venereol Leprol*. 2009;75:268-71. PubMed PMID: 19439879.
- Laddha NC, Dwivedi M, Gani AR, Shajil EM, Begum R. Involvement of superoxide dismutase isoenzymes and their genetic variants in progression of and higher susceptibility to vitiligo. *Free Radic Biol*

- Med. 2013;65:1110-25. doi: 10.1016/j.freeradbiomed.2013.08.189. PubMed PMID: 24036105.
6. Akoglu G, Emre S, Metin A, Akbas A, Yorulmaz A, Isikoglu S, et al. Evaluation of total oxidant and antioxidant status in localized and generalized vitiligo. *Clin Exp Dermatol.* 2013;38:701-6. doi: 10.1111/ced.12054. PubMed PMID: 23601201.
  7. Glassman SJ. Vitiligo, reactive oxygen species and T-cells. *Clin Sci (Lond).* 2011;120:99-120. doi: 10.1042/CS20090603. PubMed PMID: 20958268.
  8. Guerra L, Dellambra E, Brescia S, Raskovic D. Vitiligo: pathogenetic hypotheses and targets for current therapies. *Curr Drug Metab.* 2010;11:451-67. doi: 10.2174/138920010791526105. PubMed PMID: 20540698.
  9. Jayanth DP, Pai BS, Shenoi SD, Balachandran C. Efficacy of antioxidants as an adjunct to photochemotherapy in vitiligo: a case study of 30 patients. *Indian J Dermatol Venereol Leprol.* 2002;68:202-5. PubMed PMID: 17656936.
  10. Jalel A, Hamdaoui MH. Study of total antioxidant status and glutathione peroxidase activity in Tunisian vitiligo patients. *Indian J Dermatol.* 2009;54:13-6. doi: 10.4103/0019-5154.48978. PubMed PMID: 20049261; PubMed Central PMCID: PMC2800862.
  11. Chavan B, Beazley W, Wood JM, Rokos H, Ichinose H, Schallreuter KU. H(2)O(2) increases de novo synthesis of (6R)-L-erythro-5,6,7,8-tetrahydrobiopterin via GTP cyclohydrolase I and its feedback regulatory protein in vitiligo. *J Inher Metab Dis.* 2009;32:86-94. doi: 10.1007/s10545-008-0971-1. PubMed PMID: 19101819.
  12. Tai A, Sawano T, Yazama F, Ito H. Evaluation of antioxidant activity of vanillin by using multiple antioxidant assays. *Biochim Biophys Acta.* 2011;1810:170-7. doi: 10.1016/j.bbagen.2010.11.004. PubMed PMID: 21095222.
  13. Mansouri A, Makris DP, Kefalas P. Determination of hydrogen peroxide scavenging activity of cinnamic and benzoic acids employing a highly sensitive peroxyoxalate chemiluminescence-based assay: structure-activity relationships. *J Pharm Biomed Anal.* 2005;39:22-6. doi: 10.1016/j.jpba.2005.03.044. PubMed PMID: 15953704.
  14. Ethyl Vanillate [Internet]. Wisconsin: Goodscents, Inc. [cited 2010 Feb 20]. Available from: <http://www.thegoodscentscopy.com/data/rw1043971.html>
  15. Sprang NV, Kersten S. Combination therapy enhances effect of NB-UVB for treatment of vitiligo. A systematic review. *Erasmus Journal of Medicine.* 2011;1:43-6.
  16. Bacigalupi RM, Postolova A, Davis RS. Evidence-based, non-surgical treatments for vitiligo: a review. *Am J Clin Dermatol.* 2012;13:217-37. doi: 10.2165/11630540-000000000-00000. PubMed PMID: 22423621.
  17. Elgoweini M, Nour El, Din N. Response of vitiligo to narrowband ultraviolet B and oral antioxidants. *J Clin Pharmacol.* 2009;49:852-5. doi: 10.1177/0091270009335769. PubMed PMID: 19553407.
  18. Dell'Anna ML, Mastrofrancesco A, Sala R, Venturini M, Ottaviani M, Vidolin AP, et al. Antioxidants and narrow band-UVB in the treatment of vitiligo: a double-blind placebo controlled trial. *Clin Exp Dermatol.* 2007;32:631-6. doi: 10.1111/j.1365-2230.2007.02514.x. PubMed PMID: 17953631.
  19. Sanclemente G, Garcia JJ, Zuleta JJ, Diehl C, Correa C, Falabella R. A double-blind, randomized trial of 0.05% betamethasone vs. topical catalase/dismutase superoxide in vitiligo. *J Eur Acad Dermatol Venereol.* 2008;22:1359-64. doi: 10.1111/j.1468-3083.2008.02839.x. PubMed PMID: 18624857.
  20. Yuksel EP, Aydin F, Senturk N, Canturk T, Turanli AY. Comparison of the efficacy of narrow band ultraviolet B and narrow band ultraviolet B plus topical catalase-superoxide dismutase treatment in vitiligo patients. *Eur J Dermatol.* 2009;19:341-4. PubMed PMID: 19467974.
  21. Bakis-Petsoglou S, Le Guay JL, Wittal R. A randomized, double-blinded, placebo-controlled trial of pseudocatalase cream and narrowband ultraviolet B in the treatment of vitiligo. *Br J Dermatol.* 2009;161:910-7. doi: 10.1111/j.1365-2133.2009.09252.x. PubMed PMID: 19523170.
  22. Buggiani G, Tsampau D, Hercogova J, Rossi R, Brazzini B, Lotti T. Clinical efficacy of a novel topical formulation for vitiligo: compared evaluation of different treatment modalities in 149 patients. *Dermatol Ther.* 2012;25:472-6. doi: 10.1111/j.1529-8019.2012.01484.x. PubMed PMID: 23046028.