

# Hydatid Cyst of Ovary: A Case Report

Mohsen Khosravi Maharlooei<sup>1</sup>,  
Armin Attar<sup>1</sup>, Amita Goran<sup>2</sup>,  
Seddigheh Amuee<sup>2</sup>, Arman Dehghan<sup>1</sup>,  
Ahmad Monabati<sup>3</sup>

## Abstract

*Echinococcus granulosus* is considered the major cause of human hydatid cysts. Usually the duration of cyst formation is 10-20 years. This period shortens significantly upon rupture of a primary cyst. The literature describes low incidence of primary involvement of ovary as a site of hydatid cyst formation. Our case is the first report on ovarian hydatid cyst in Iran. A 60-year-old woman was presented with abdominal pain in the left lower quadrant area. Paraclinical data were suggestive of neoplasia and preoperative diagnosis was ovarian tumor. During laparotomy, multiple cysts resembling hydatid cysts were observed in the left ovary. Pathological examination confirmed the diagnosis of hydatid cyst. Although there is a small possibility of secondary ovarian echinococcal disease, it is more probable for this case to be primary infection, as the patient had developed ovarian hydatid cysts 15 years after hepatic involvement and recurrence after 30 months is very uncommon.

**Iran J Med Sci 2009; 34(1): 76-79.**

**Keywords** • Cestode infections • Echinococcosis • *Echinococcus granulosus*

## Introduction

**H** ydatid cysts occur worldwide. *Echinococcus granulosus* is considered a major cause of human hydatid cysts. This infection is more common in countries where people keep cattle, sheep, and dogs near their living places.<sup>1</sup> These countries belong to Mediterranean region, middle Europe, south America, Middle East, east Africa, and Australia.<sup>1</sup> Humans play the role of accidental intermediate hosts. Usually the duration of cyst formation from the ingestion of the eggs by a host up to symptomatic stage of the disease is 10-20 years.<sup>1</sup> However, this period depends largely on the elasticity and expandability of the organ and shortens significantly upon rupture of the primary cyst.<sup>1</sup> The route that larvae choose to spread is through penetration of the intestinal wall, and most of them enter the portal vein to reach the liver. Seventy percent of these larvae are captured by the liver while the remaining 30% escape the hepatic filter. *E. granulosus* mainly affects the liver (63%), lungs (25%), muscles (5%), bones (3%), kidneys (2%), brain (1%), and spleen (1%).<sup>1</sup> Recurrence of the disease after surgery for primary hydatid cysts reaches 22% by 30 months. Recurrence has not reported after 30 months in a 7-year follow-up period.<sup>2</sup>

## Case Presentation

A 60-year-old woman presented with abdominal pain in the left lower quadrant area occurring mostly at night, as well as

<sup>1</sup>Student of Medicine,

<sup>2</sup>Department of Gynecology & Obstetrics,

<sup>3</sup>Department of Pathology, Shiraz University of Medical Sciences, Shiraz, Iran.

### Correspondence:

Mohsen Khosravi Maharlooei,  
Student of Medicine,  
Shiraz University of Medical Sciences,  
Shiraz, Iran.

**Tel:** +98 711 8230256

**Fax:** +98 711 2349521

**Email:** [mohsen2010k@yahoo.com](mailto:mohsen2010k@yahoo.com)

Submitted: 5 March 2008

Revised: 27 April 2008

Accepted: 21 August 2008

vaginal spotting for several days each month for 3 months prior to admission. She had gone through the menopause for 15 years and described regular menstruation cycles before that time. She had a history of two dead fetus deliveries through normal vaginal delivery (NVD) in her third and fourth pregnancies. All her other eleven pregnancies were terminated by NVD and led to healthy newborns. She had two histories of laparotomy: one for liver hydatid cyst 10 years prior to admission, and the other about 3 years prior to admission because of an ovarian lesion with the evidence of ovarian neoplasia. In the latter laparotomy, right oophorectomy was performed. She had positive history of direct contact with dogs and sheep for about 20 years up to 15 years prior to admission. The patient was a known case of hypertension and was on atenolol. On bimanual examination a left adnexal mass was palpated. She had a second grade uterine prolapse accompanied by cystocele and rectocele. No other abnormalities were detected on systemic and gynecological examination. Abdominopelvic sonography revealed a 48 mm multicystic appearance located in the left ovary, suggestive of ovarian neoplasia. Transvaginal sonographic evaluation showed a multivesiculated cystic mass in the left adnexa (figure 1). Computed tomography (CT)

showed a multivesiculated cystic mass in the left adnexa with enhancement in the periphery without any evidence of invasion into the adjacent soft tissue structures. However a malignant process arising from the left ovary was also a remote possibility.

Preoperative amount of tumor marker CA-125 was 50 U/ml. Alanine transaminase (ALT), aspartate transaminase (AST) and Alkaline phosphatase, were within the normal ranges. Preoperative diagnosis was ovarian tumor. During laparotomy, multiple cysts resembling hydatid cyst were observed in the left ovary (figure 2).

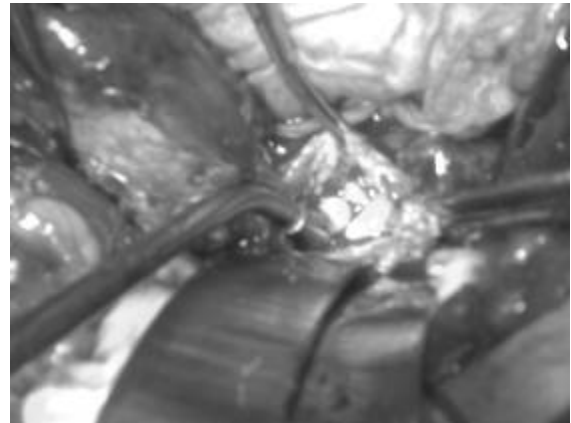


Figure 2: Three hydatid cysts inside the ovary.

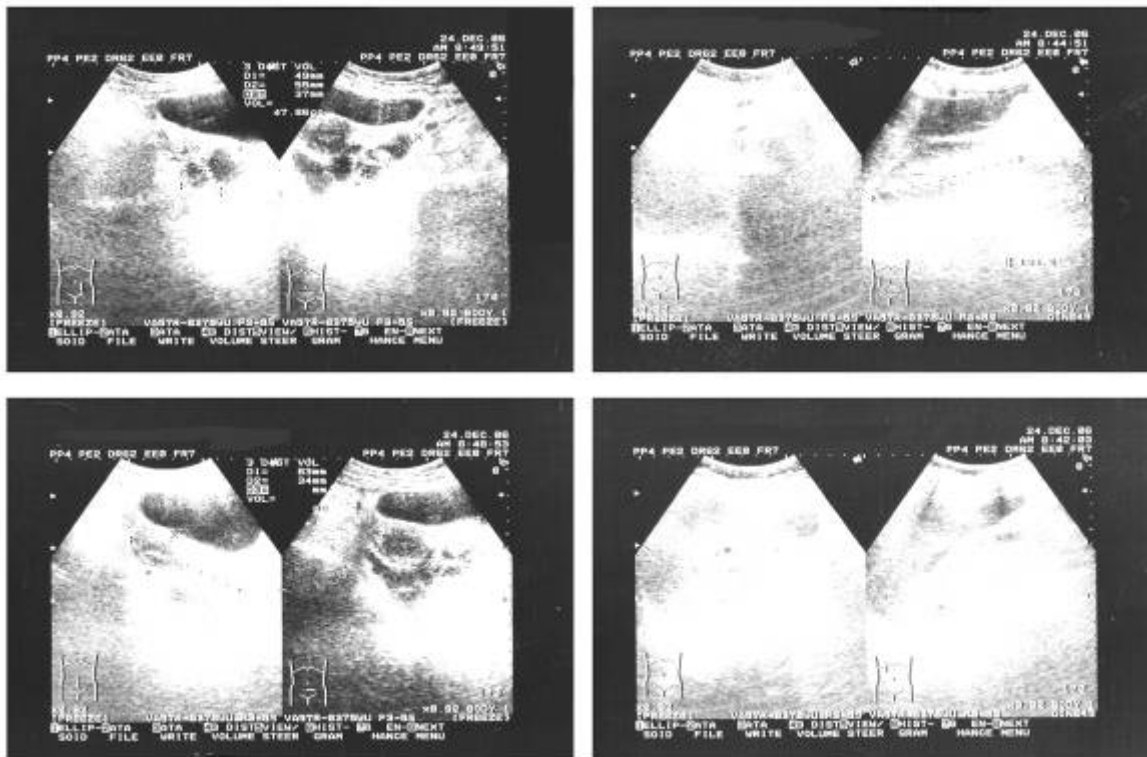


Figure 1: Sonographic imaging before the surgery revealed a multicystic appearance in the left ovary and absence of right ovary as a result of previous oophorectomy.

Total abdominal hysterectomy and left salpingo-oophorectomy was done. Pathological examination confirmed the diagnosis of hydatid cyst. No sign of malignancy was observed (figure 3). Counter-current immunoelectrophoresis for detection of hydatid cyst was strongly positive.

## Discussion

Patients with hydatid cyst of the ovary have been reported from Saudi Arabia,<sup>3</sup> Ethiopia,<sup>4</sup> India,<sup>5</sup> and other regions.<sup>6</sup> All these reports revealed low incidence of primary involvement of the ovary as a site of hydatid cyst formation.

Since secondary involvement of the pelvic organs is seen and the primary involvement is very rare, it has been suggested that Echinococcal cysts should be included in the differential diagnosis of multicystic ovarian lesions if the patient comes from an endemic area and has had cysts elsewhere in the body.<sup>7</sup>

Our case is the first report of ovarian hydatid cyst from Iran. Although it is possible that the case be a secondary ovarian echinococcal disease, it is more probable for this case to be primary infection. This is due to the fact that the patient developed ovarian hydatid cyst 15 years after hepatic involvement and recurrence

after 30 months is very uncommon.<sup>2</sup> We are in agreement with Hiller et al. that Echinococcal cysts should be included in the differential diagnoses of multicystic ovarian lesions, not only as secondary but as primary involvement, if the patient lives in an endemic area and the patient has had cysts elsewhere in the body.<sup>7</sup>

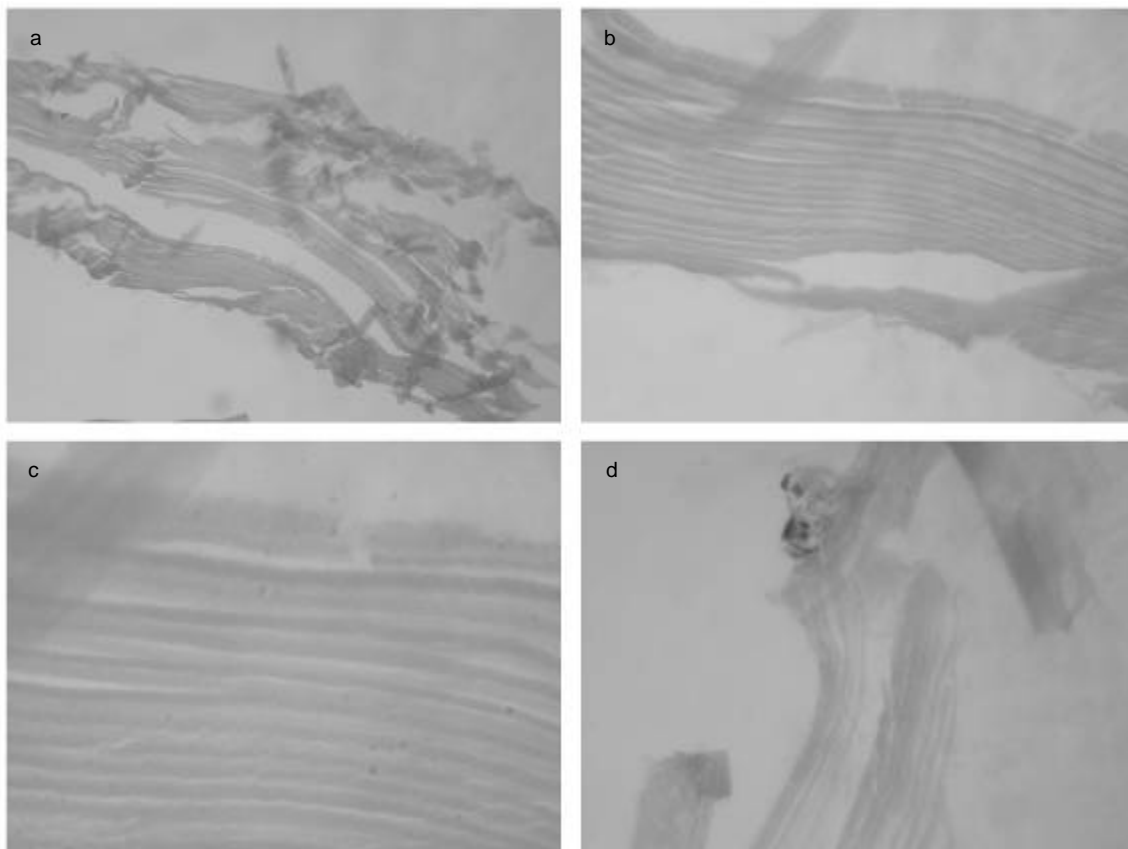
Ovarian Echinococcus cysts may have a peculiar ultrasonographic pattern at high frequency (7.5 MHz) vaginal ultrasonography. Such a high-frequency ultrasonography can be a useful tool in the diagnosis of the disease.<sup>8</sup>

Ultrasonography (particularly high frequency trans-vaginal), CT, and more recently, magnetic resonance imaging are more frequently used in the diagnosis of Echinococcus cyst. These methods appear more reliable than many earlier tests of varying sensitivities.

Adewunmi et al. have endorsed the recommendation that any gynecologist, radiologist, and histopathologist should suspect hydatid cyst whenever a septate cystic pelvic mass is found.<sup>3</sup>

## Acknowledgment

We thank Farshid Pahlevan for his scientific contribution. We also thank E Ghannadan, Resident of Gynecology & Obstetrics, Depart-



**Figure 3:** Microscopic appearance of the cyst showing clear, hyalin laminated membrane: a- H&E staining  $\times 40$ , b- H&E staining  $\times 100$ , c- H&E staining  $\times 400$ , d- a single proglottid is shown  $\times 400$

ment of Gynecology & Obstetrics, Shiraz University of Medical Sciences, and A Ghasemi, Resident of Radiology, Department of Radiology, Shiraz University of Medical Sciences, for their kind help.

**Conflict of Interest:** None declared

### References

- 1 Aksu MF, Budak E, Ince U, Aksu C. Hydatid cyst of the ovary. *Arch Gynecol Obstet* 1997; 261: 51-3.
- 2 Little JM, Hollands MJ, Ekberg H. Recurrence of hydatid disease. *World J Surg* 1988; 12: 700-4.
- 3 Adewunmi OA, Basilingappa HM. Primary ovarian hydatid disease in the Kingdom of Saudi Arabia. *Saudi Med J* 2004; 25: 1697-700.
- 4 Gaym A, Abebe D, Degefe DA. Hydatid cyst an unusual cause of ovarian enlargement. *Ethiop Med J* 2002; 40: 283-91.
- 5 Konar K, Ghosh S, Konar S, et al. Bilateral ovarian hydatid disease-an unusual case. *Indian J Pathol Microbiol* 2001; 44: 495-6.
- 6 Gamoudi A, Ben Romdhane K, Farhat K, et al. Ovarian hydatic cyst. 7 cases. *J Gynecol Obstet Biol Reprod (Paris)* 1995; 24: 144-8.
- 7 Hiller N, Zagal I, Hadas-Halpern I. Echinococcal ovarian cyst. A case report. *J Reprod Med* 2000; 45: 224-6.
- 8 Díaz-Recaséns J, García-Enguידanos A, Muñoz I, et al. Ultrasonographic appearance of an echinococcus ovarian cyst. *Obstet Gynecol* 1998; 91:841-2.