

Rare Association between Kikuchi's Disease and Systemic Lupus Erythematosus

Mohammadhassan Jokar, Zahra Mirfeizi,
Kambiz Javidi

Abstract

Histiocytic necrotizing lymphadenitis or Kikuchi's disease is a rare, benign condition of unknown etiology, which is usually characterized by cervical lymphadenopathy and fever. This disease is rarely associated with systemic lupus erythematosus. Here we describe, for the first time in Iran, a patient who developed systemic lupus erythematosus about 3 years after the initial diagnosis of Kikuchi's disease.

Iran J Med Sci 2009; 34(4): 289-291.

Keywords • Histiocytic necrotizing lymphadenitis • Kikuchi's disease • systemic lupus erythematosus

Introduction

Histiocytic necrotizing lymphadenitis (HNL) or Kikuchi's disease was described in 1972 by Kikuchi.¹ The disease is characterized by a benign subacute necrotizing lymphadenitis affecting young individuals in the third and fourth decades of life. The male to female ratio of affected patients is 1:4. The clinical features usually appear after common cold-like symptoms, run a self-limiting benign course, and can resolve spontaneously. Lymphadenopathy is frequently associated with fever. Maculopapular rash, characterized by transient rubella-like or drug-induced-like eruptions, are also often present, especially in febrile and more severe cases.

The etiology of HNL is unknown. Association of HNL and systemic lupus erythematosus (SLE) is rare and only 40 patients have been reported with HNL who later fulfilled the diagnostic criteria or developed certain features of SLE.² This report presents for the first time in Iran a patient who developed SLE about 3 years after the initial diagnosis of Kikuchi's disease.

Case Report

A 24-year-old man was admitted to a local hospital with fever, abdominal pain, nausea, and vomiting for 3 days in May 2004. The pain was diffuse and continuous. His medical history was unremarkable. On physical examination he was febrile (T=38.5°C) and his abdomen was diffusely tender and rigid without rebound tenderness. The rest of systemic examination was normal.

Complete blood cell count (CBC), biochemical tests, erythrocyte sedimentation rate (ESR) and C-reactive protein were within normal limits. Blood and urine cultures were sterile. Chest radiograph was normal. An ultrasound imaging of the abdomen showed only small amount of ascites. A diagnosis of probable peritonitis was made and diagnostic laparotomy was carried out. Laparotomy showed no abnormality except for 50 ml yellowish ascites. In spite of the failure to prove bacterial

Rheumatic Diseases Research Center,
Imam Reza Hospital,
Mashhad University of Medical Sciences,
Mashhad, Iran.

Correspondence:

Mohammadhassan Jokar MD,
Rheumatic Diseases Research Center,
Mashhad University of Medical Sciences,
Mashhad, Iran.

Tel/Fax: +98 511 8598818

Email: jokarmh@mums.ac.ir

Received: 12 January 2009

Revised: 5 March 2009

Accepted: 22 April 2009

infection, intravenous antibiotics (ceftriaxone 1000 mg twice daily and metronidazole 500 mg every 6 hours) were started. After one week the patient refused more treatment and was discharged without significant improvement. He continued to have intermittent fever and abdominal pain.

Two months later (July 2004) the patient was admitted to another hospital for further evaluation. His symptoms were intermittent fever and abdominal pain. Physical examination showed only low grade fever ($T = 38.3^{\circ}\text{C}$) and mild diffuse abdominal tenderness. A complete evaluation, including routine laboratory tests, bone marrow biopsy, blood and urine cultures, and tuberculin skin test were unremarkable. Chest radiograph was normal. Abdominal ultrasonography showed mild splenomegaly. Computed tomography of abdomen and pelvis showed only mild splenomegaly. Esophagogastroduodenoscopy was normal. He was discharged from hospital without making a definite diagnosis.

Seven months later (February 2005) the patient experienced diffuse musculoskeletal pain and was admitted again to another hospital. At this time, physical examination showed a 2x2 cm posterior cervical lymph node on the right side. The lymph node was firm, mildly tender, and mobile. No other lymph nodes were enlarged. All his laboratory investigations including CBC, ESR, blood chemistry, and urine analysis were within normal range. Serologic tests for brucellosis were negative. Excisional biopsy of the lymph node was performed and the histopathological evaluation revealed lymph node with essentially preserved architecture with follicular hyperplasia and multiple areas of histiocytic aggregates consistent with necrosis and cell debris (figure 1). The findings were consistent with Kikuchi's disease. Administration of oral prednisolone (15 mg per day) at decreasing dosage, resulted in marked improvement. After six months, prednisolone was discontinued.

The patient was asymptomatic until December 2007. At this time he was referred to our rheumatology clinic for evaluation of polyarthritis. He was photosensitive and physical examination showed tenderness and swelling in both hands, elbows, and knees joints. Laboratory tests were normal except for antinuclear antibodies (ANA) and anti-double-stranded DNA (anti-dsDNA). ANA was 1/80 (indirect immunofluorescence) and anti-dsDNA was 177 IU/ml (normal <100 IU/ml). The clinical diagnosis of SLE was made according to American College of Rheumatology criteria.³ Treatment with oral hydroxychloroquine 200 mg twice

daily and prednisolone 10 mg/day was started. The patient became symptom free after few days. After one year of follow-up, the patient is still in complete remission.

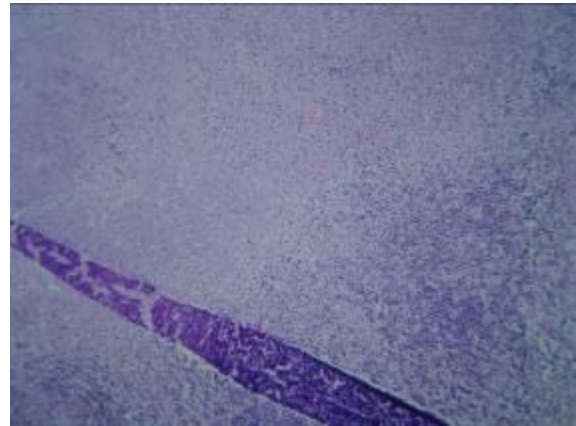

Figure 1: Excisional biopsy of the lymph node showing essentially preserved architecture with follicular hyperplasia and multiple areas of histiocytic aggregates consistent with necrosis and cell debris.

Discussion

Kikuchi's disease has been described primarily in people younger than 30 years of age, predominantly in women, and in Asian populations.⁴ It is considered as a self-limiting benign systemic lymphadenitis, especially involving the cervical nodes of unknown cause. Though the disease has been reported to exist worldwide, it remains a poorly recognized clinicopathological entity often confused with malignant lymphoma and SLE.² While the pathogenesis of Kikuchi's disease is unknown, its clinical presentation, natural history, and histological changes suggest an immune response of T cells and histiocytes to an infectious agent. Numerous inciting agents have been proposed, including Epstein Barr virus (EBV),⁵ human herpes virus,⁶ parvovirus B19,⁷ and type I human T-cell lymphotropic virus.⁸ In one report, EBV was detected by in situ hybridization in tissue of all the 10 examined patients; however, immunohistochemistry detected EBV-encoded protein in only one of those patients.^{8,9} An observation consistent with a viral etiology is increased levels of interferon alpha and of other proteins stimulated by interferon alpha including 2', 5'-oligoadenylate synthetase and tubuloreticular structures in the cytoplasm of stimulated lymphocytes, histiocytes, and vascular endothelium.¹⁰

The relationship between SLE and Kikuchi's disease, though strong, is still complex. Some authors feel that HNL is an atypical manifestation of SLE. HNL may occur in patients with pre-existing SLE, may coexist with SLE, or

may evolve into SLE.²

SLE can also present with lymphadenopathy, although there are few differences between SLE and lupus lymphadenopathy. The involvement of lymph nodes in Kikuchi's disease is focal, while in lupus lymphadenitis, more extensive involvement is observed. Histologically, the presence of hematoxyphillic bodies, abundant plasma cells and true vasculitis outside the area of necrosis also favor the diagnosis of SLE.¹¹ The absence or paucity of neutrophils confirms the diagnosis of KD.¹²

No effective treatment has been established for patients with Kikuchi's disease. Signs and symptoms usually resolve within one to four months. Patients with severe or persisting symptoms have been treated with corticosteroids with some benefits.¹³ There has been one report on recurrent Kikuchi's disease successfully treated with hydroxychloroquine.¹⁴ Affected patients should be followed up for years because they can develop SLE and recurrent episodes of Kikuchi's disease can occasionally continue for many years.¹³ One patient, for example, had four episodes of lymphadenopathy over 18 years and another had two episodes separated by six years.¹⁵

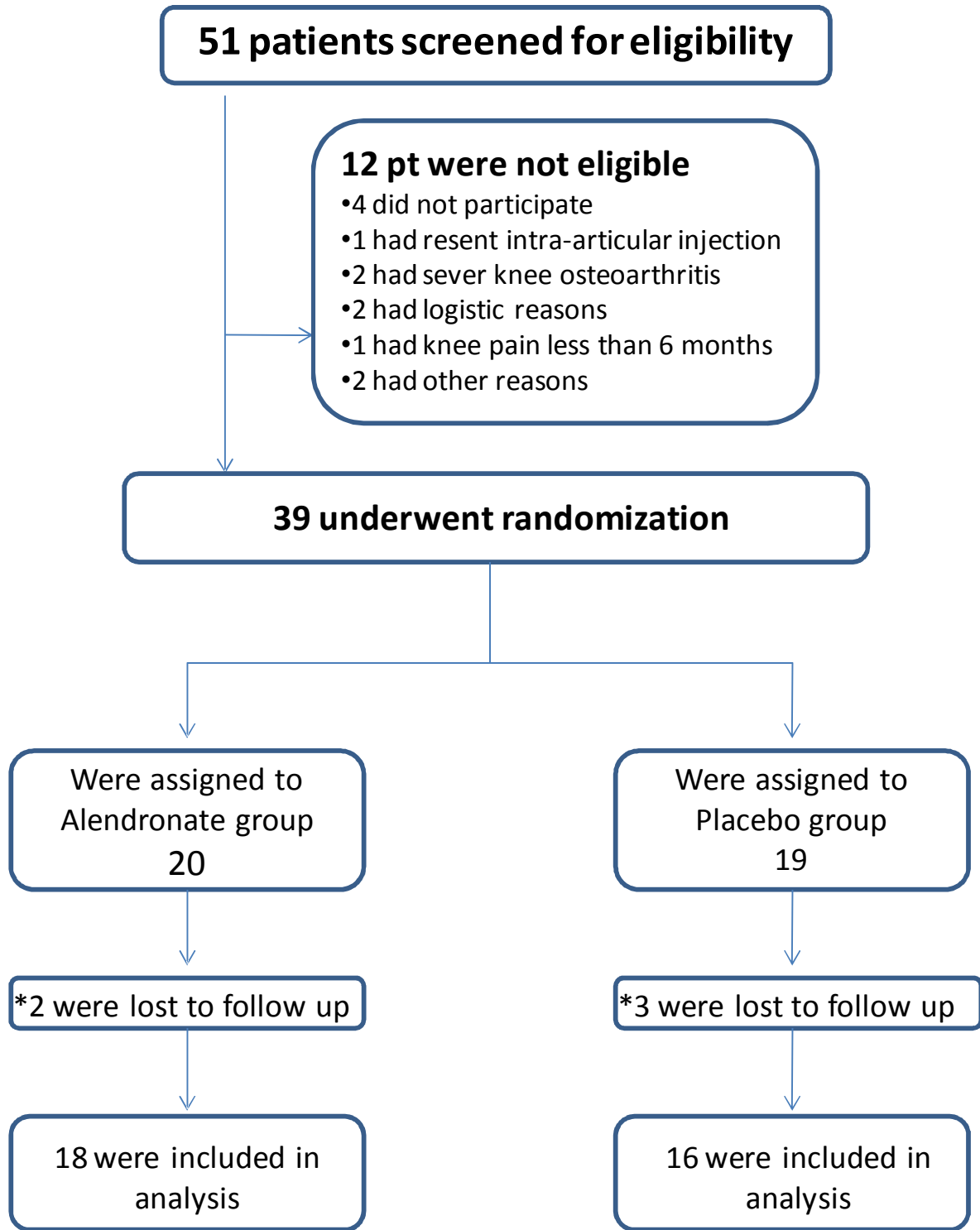
Conclusion

Some patients initially diagnosed as having Kikuchi's disease may subsequently develop SLE.

Conflict of Interest: None declared

References

- 1 Kikuchi M. Lymphadenitis showing focal reticulum cell hyperplasia with nuclear debris and phagocytosis: a clinicopathological study *Acta Hematol Jpn* 1972; 7: 261-7.
- 2 Paradelo S, Lorenzo J, Martínez-Gómez W, et al. Interface dermatitis in skin lesions of Kikuchi-Fujimoto's disease: a histopathological marker of evolution into systemic lupus erythematosus? *Lupus* 2008; 17: 1127-35.
- 3 Hochberg MC. Updating the American College of Rheumatology revised criteria for the classification of systemic lupus erythematosus. *Arthritis Rheum* 1997; 40: 1725.
- 4 Tsang WY, Chan JK, Ng CS. Kikuchi's lymphadenitis. A morphologic analysis of 75 cases with special reference to unusual features. *Am J Surg Pathol* 1994; 18: 219-31.
- 5 Yen A, Fearneyhough P, Raimer SS, Hudnall, SD. EBV-associated Kikuchi's histiocytic necrotizing lymphadenitis with cutaneous manifestations. *J Am Acad Dermatol* 1997; 36: 342-6.
- 6 Huh J, Kang GH, Gong G, et al. Kaposi's sarcoma-associated herpesvirus in Kikuchi's disease. *Hum Pathol* 1998; 29: 1091-6.
- 7 Yufu Y, Matsumoto M, Miyamura T, et al. Parvovirus B19-associated haemophagocytic syndrome with lymphadenopathy resembling histiocytic necrotizing lymphadenitis (Kikuchi's disease). *Br J Haematol* 1997; 96: 868-71.
- 8 Chiu CF, Chow KC, Lin TY, et al. Virus infection in patients with histiocytic necrotizing lymphadenitis in Taiwan. Detection of Epstein-Barr virus, type I human T-cell lymphotropic virus, and parvovirus B19. *Am J Clin Pathol* 2000; 113: 774-81.
- 9 Hudnall SD. Kikuchi-Fujimoto disease. Is Epstein-Barr virus the culprit? *Am J Clin Pathol* 2000; 113: 761-4.
- 10 Rich SA. De novo synthesis and secretion of a 36-kD protein by cells that form lupus inclusions in response to alpha-interferon. *J Clin Invest* 1995; 95: 219-26.
- 11 Spies J, Foucar K, Thompson CT, LeBiot PE. The histopathology of cutaneous lesions of Kikuchi's disease (necrotizing lymphadenitis): a report of five cases. *Am J Surg Pathol* 1999; 23: 1040-7.
- 12 Martínez-Vázquez C, Hughes G, Bordon J, et al. Histiocytic necrotizing lymphadenitis, Kikuchi-Fujimoto's disease, associated with systemic lupus erythematosus. *QJM* 1997; 90: 531-3.
- 13 Imad-Eddin B. Tahboub, Hussein A. Sha'lan, Rami S. Farraj, Nayef M. Hababeh. Kikuchi - Fujimoto Disease: A Case Report. *JRMS* 2005; 12: 54-6.
- 14 Rezai K, Kuchipudi S, Chundi V, et al. Kikuchi-Fujimoto disease: hydroxychloroquine as a treatment. *Clin Infect Dis* 2004; 15: (12): e124-6.
- 15 Smith KG, Becker GJ, Busmanis I. Recurrent Kikuchi's disease. *Lancet* 1992; 340: 124.



*Five patients discontinued the treatment because of the adverse events